

# Corneal Suturing Techniques

# 6

W. Barry Lee and Mark J. Mannis

## Key Points

### Surgical Indications

- Congenital corneal disorders
- Corneal dystrophies
- Corneal degenerations
- Corneal scarring/opacification
  - Infection
  - Inflammation
  - Trauma
- Graft failure
- Corneal decompensation
  - Pseudophakic
  - Aphakic
  - Iatrogenic
  - Dystrophic
  - Traumatic

### Surgical Instrumentation

- Operating microscope
- Microsuturing instruments
  - Fine-toothed 0.12-mm forceps
  - Fine-tip needle holder
  - Tying forceps
  - 10-0 or 11-0 monofilament suture
- Trephination device
- Preserved corneal tissue

### Surgical Technique

- Appropriate tissue fixation with forceps
  - Avoid compression or tissue maceration
  - Avoid donor endothelium
- Appropriate suture placement
  - Equal suture length on donor and host tissue
  - Radial placement
  - Appropriate depth
  - Adequate knot tension
- Interrupted suture placement at four cardinal positions
- Avoid donor–host mismatch
- Second suture is critical for placement
- Look for diamond-shaped striae
- Suture pattern
  - Interrupted technique
  - Combined interrupted and continuous technique

- Single continuous technique
- Double continuous technique

### Complications

- Intraoperative
  - Iris, lens, or vitreous prolapse
  - Iris trauma/iris incarceration with suture
  - Traumatic cataract
  - Suprachoroidal hemorrhage
  - Donor–recipient mismatch
- Postoperative
  - Astigmatism
  - Infection (suture abscess, graft ulcer, endophthalmitis)
  - Wound leak (flat or narrow chamber)
  - Traumatic cataract
  - Iris trauma (hyphema, peripheral synechia, iris suture entrapment)

## 6.1

### Introduction

Suturing technique remains one of the most vital skills in the art of contemporary corneal surgery. Although the main purpose of suture placement remains adequate wound apposition and closure, meticulous attention to appropriate suture placement cannot only minimize postoperative astigmatism, but also may facilitate more rapid visual recovery and lead to a more stable wound long term. A variety of factors remain critical for suture placement, including avoidance of mismatch between radial and nonradial suture bite placement, appropriate donor and recipient bite lengths, appropriate bite depth, and symmetrical and adequately dispersed suture tension in each quadrant of the cornea, with special care to prevent excessive tightening. The evolution of corneal suturing techniques from overlay sutures to direct appositional suture closure, along with the discovery of small, monofilament suture material has revolutionized suturing techniques and postoperative success.

This chapter focuses on the suturing techniques in penetrating keratoplasty, including indications, instrumentation, various surgical techniques, complications,

and future considerations. Corneal suturing in settings other than keratoplasty is discussed elsewhere in this book.

---

## 6.2 Surgical Indications

The indications for keratoplasty encompass a diverse group of corneal disorders. The underlying pathologic mechanisms lead to the development of corneal edema, opacification, scarring, vascularization, and/or distortion creating an unacceptable level of vision. The broad range of corneal abnormalities include congenital disorders, hereditary dystrophic conditions, degenerative conditions, infections, inflammatory disorders, trauma, stem cell dysfunction, graft failure, and iatrogenic causes whether surgical or medication-induced.

The most common indications for corneal transplantation include pseudophakic bullous keratopathy, Fuchs' endothelial dystrophy, keratoconus, and previous graft rejection. Less common indications include aphakic bullous keratopathy, corneal scarring, other corneal dystrophies, chemical burns, congenital corneal opacities, and corneal sequelae from infections such as *Herpes simplex*, *Herpes zoster*, bacteria, and fungi [9, 12, 16, 29].

---

## 6.3 Instrumentation and Equipment

Corneal surgery requires an operating microscope, highly specialized microsurgical tools including fine-toothed forceps, fine corneal scissors, tying forceps, needle holders, and precision-cutting circular corneal trephines. Essential adjuncts to the microsurgical instruments include 10-0 or 11-0 monofilament suture, ophthalmic viscosurgical agents, and pharmacological agents such as miotics, corticosteroids, and topical and subconjunctival antibiotics.

The forceps in corneal surgery must have fine teeth that enable appropriate stabilization of corneal tissue while a fine-tip needle holder is used to pass suture. Single-point fixation forceps, typically 0.12-mm forceps, are used for tissue stabilization with care to avoid excessive grabbing or compression that may lead to tissue maceration. These forceps have a tying platform that can be used to hold one suture end during tying of the knot. The fine-tip needle holder can be used to hold the other suture end during tying of the knot. Alternatively, tying forceps can be used for suture tying once a suture has been adequately placed.

Corneal incisions during keratoplasty are typically constructed using vacuum-based or handheld trephine blades. A variety of vacuum systems are available but

all consist of a centration device, vacuum-suction tubing, multiple-sized trephination blades, and a turning platform to allow for controlled cutting of the host cornea. A cutting platform is typically used on a side table to make appropriately sized cuts into the donor tissue with the trephination blade size of choice.

Additional components of keratoplasty procedures include acquisition of donor tissue from eye banking establishments. The combination of improved methods of corneal tissue procurement by eye banks as well as tissue preservation, storage media, and advanced microsurgical instrumentation has contributed to the modern day success of keratoplasty surgery.

---

## 6.4 Surgical Technique

Surgical corneal procedures require meticulous suture technique for appropriate wound closure. The purpose of the suture is to hold the wound in stable apposition until the natural healing process is complete, rendering the suture unnecessary.

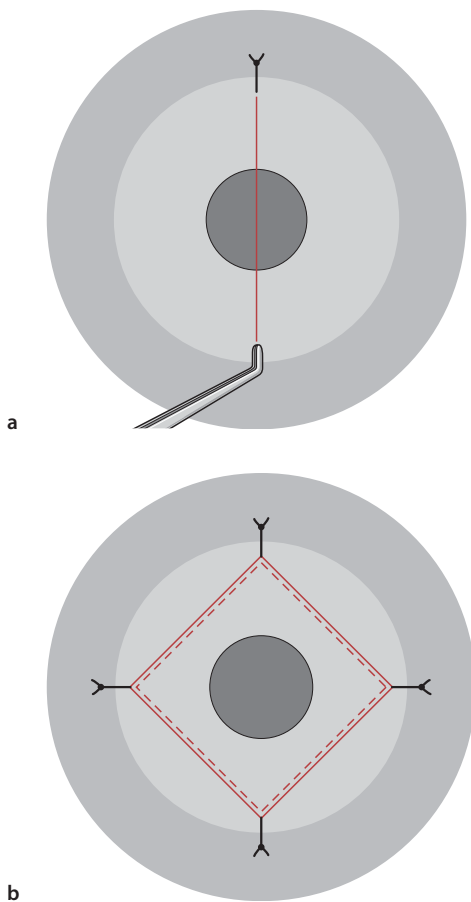
After appropriate trephination and sizing of the donor tissue and diseased host cornea, an ophthalmic viscoelastic is placed in the anterior chamber and angle. The donor corneal button is grasped with fine-toothed forceps, taking care to avoid compression of the donor endothelial cells. This maneuver is best performed with two-point fixation, toothed forceps (e. g., Polack forceps) for the initial suture placement. However, single fixation, toothed forceps are adequate as long as torque of the donor tissue can be avoided. The forceps should hold the anterior one third of the corneal tissue edge with the anterior fixation point contacting the donor epithelium and the posterior fixation point contacting the trephined edge of the corneal stroma. Torque can be avoided by grasping the tissue in this manner, allowing for the forceps tips to meet in direct opposition, without excessive squeezing of the tissue. The donor cornea is placed over the eye on the bed of viscoelastic, and the initial cardinal suture is placed at 12 o'clock. Previously placed radial ink marks from a radial keratotomy (RK) marker can aid appropriate radial suture placement. For suture placement, the point of the needle should enter the anterior graft surface approximately 0.75 mm from the wound edge and is passed at 95% depth through the donor cornea immediately behind the point of forceps fixation. The proper depth of suture placement should fall just anterior to Descemet's membrane. The suture is then passed through the recipient tissue with an equal amount of tissue purchase. The length of suture placement on the donor and recipient tissue should approximate 0.75 mm on each side of the wound. In some instances, a longer recipient bite is required such as a

thin recipient bed or a large tectonic graft procedure. The four “cardinal” sutures are passed at the 12 and 6 o'clock positions, followed by the 3 and 9 o'clock positions. Though controversial, some corneal surgeons intentionally place the four cardinal sutures completely through both the donor and the recipient, resulting in full-thickness sutures. It is thought this technique may result in better tissue apposition. Controversy exists as to whether the suture can act as a wick to allow ingress of bacteria from the tear film into the anterior chamber with the resultant risk of endophthalmitis.

The second cardinal suture is considered the most important suture in keratoplasty, because it is crucial in determining lateral wound apposition, proper donor/recipient edge alignment, and corneal astigmatism. This suture is placed at the 6 o'clock position precisely 180° from the first cardinal suture. After placement of this suture, donor/recipient apposition should be equal at the 3 and 9 o'clock positions, with neither gap nor overlap and a tension line from 12 to 6 o'clock should bisect the donor tissue in two equal

halves (Fig. 6.1a). After placement of the second suture, the third and fourth sutures are placed at 3 and 9 o'clock, equidistant from the previous two sutures. After completion of the four cardinal sutures, equal tension lines form a diamond-shaped pattern within the donor cornea (Fig. 6.1b). Once the cardinal sutures are completed, the wound architecture and configuration of the donor/recipient junction has been determined, regardless of the placement of future sutures. Cardinal suture placement largely determines final corneal sphericity and subsequent corneal astigmatism. Once the cardinal sutures are in place, a variety of suturing techniques can then be implemented.

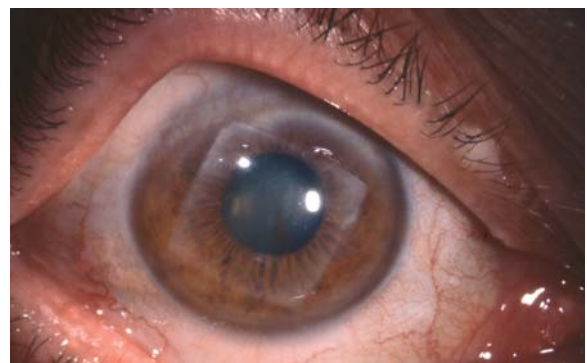
A variety of suture fixation patterns can be implemented for appropriate tissue alignment and wound closure. Interrupted sutures are the oldest technique of the modern keratoplasty era. Surgeons such as Castroviejo, Troutman, and Fine popularized the use of direct appositional interrupted sutures, which are now typically performed with 12, 16, or 24 interrupted equidistant 10-0 nylon sutures ([23, 24, 30, 46–49]; Fig. 6.2). An alternative pattern of corneal suture fixation employs interrupted sutures in combination with a continuous running suture. Finally, a single continuous running suture (SCS) or double continuous running suture (DCS) may also be used for corneal wound apposition with nylon, polypropylene, or Merseline suture.



**Fig. 6.1** **a** Schematic diagram of cardinal suture placement in keratoplasty demonstrating the typical appearance of vertical striae, with appropriate placement of the second cardinal suture. **b** The typical pattern of diamond-shape striae seen with appropriate placement of all four cardinal sutures.

#### 6.4.1 Single Interrupted Suture Technique

The single interrupted corneal suturing technique represents the oldest of the various suture techniques performed today, and it is the gold standard of wound closure and adequate wound apposition in corneal surgery. Regardless of the surgeon's preferred suturing technique, interrupted suture placement must be perfected by all surgeons, especially in keratoplasty, as certain cases mandate interrupted suture methods



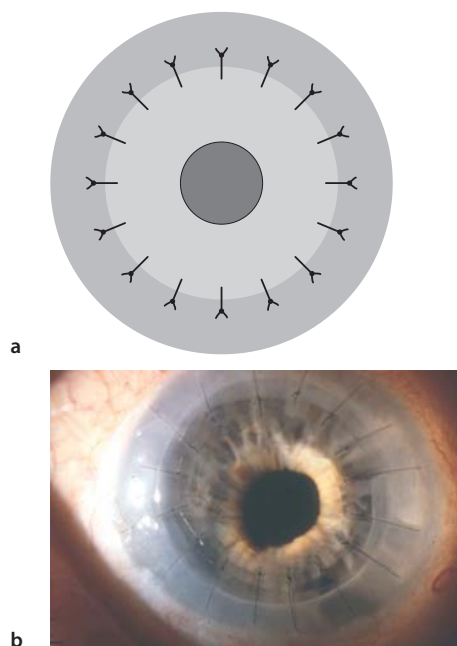
**Fig. 6.2** A square graft performed by Castroviejo with best-corrected vision of 20/20 almost 40 years after penetrating keratoplasty for keratoconus. (Courtesy of Bruce Varnum)

rather than continuous running methods. The interrupted suture technique should be performed in all cases of pediatric keratoplasty, traumatic or spontaneous graft dehiscence repair, tectonic keratoplasty, and cases in which corneal graft vascularization may occur, e. g., eccentric grafts, multiple prior rejection episodes, prior corneal inflammatory conditions, and host corneal vascularization or ulceration. The interrupted suture technique requires a minimum of eight sutures to maintain watertight wound closure; however, most surgeons perform 16 equidistant sutures for routine cases. Some surgeons advocate use of 24 rather than 16 interrupted equidistant sutures. Proper, equidistant spacing of the sutures can be facilitated by previously applied radial ink marks, using an RK marker. Pediatric grafts may include the use of varying numbers of interrupted sutures with 8, 12, 16, or 24 individual equidistant sutures depending on surgeon preference.

The interrupted suturing technique generally employs 10-0 monofilament nylon suture with a 160° single-curve 5.5-mm needle at the four cardinal positions in the order of 12, 6, 3, and 9 o'clock, as described earlier. Sutures can be tied with a variety of different techniques. A common method includes a 3-1-1 closure, with adjustment of tension before the second throw is made and the knot secured. The authors prefer a slipknot technique, with four single throws and adjustment of suture tension after the second throw. The third and fourth throws are square knots and ensure permanent suture tension. The slipknot technique

allows for easier adjustment of suture tension while retaining the ability to change undesirable suture tension easily before the third throw is completed. Regardless of the method of suture fixation, meticulous attention to appropriate suture tension with avoidance of loose or tight knots is essential for minimizing postoperative corneal astigmatism. Sutures should be replaced if tension is not adequate. Once all sutures have been placed with adequate knot tension and watertight wound closure, the ends are trimmed with a microsurgical blade or Vannas scissors, and all knots are buried (Fig. 6.3). Some surgeons prefer to bury the knots on the recipient side to reduce tension on the graft–host junction at time of suture removal, making risk of wound dehiscence less likely [34]. Other surgeons prefer to bury the sutures near the donor side, increasing the distance between the knot and the limbal vessels in order to reduce the risk of suture vascularization and inflammation [34].

Astigmatism adjustment with the interrupted technique is performed by removing the suture at the steep meridian as indicated by keratometry, photokeratometry, or computerized corneal topography. Each suture creates tangential vector forces, creating adjacent flattening with central steepening along the meridian of suture placement. Interrupted sutures can be removed in a well-constructed corneal graft as early as 6 weeks postoperatively if a suture is felt to be too tight, contributing to abnormal corneal topography and high amounts of astigmatism, or if suture vascularization or infiltration occurs. While adjacent sutures should typically not be removed until 6 months postoperatively, earlier removal may be indicated at the surgeon's discretion if stable wound integrity exists, limiting the risk of wound dehiscence after removal, or if a running suture is in place. Circumstances for earlier suture removal may include severe visual compromise as a result of high amounts of astigmatism or suture vascularization in the setting of a stable corneal wound. Sutures can be left in place indefinitely but should be removed if they break, loosen, become inflamed, infected, or vascularized, or if removal will clearly improve the topographical profile and subsequent visual acuity. Typically a drop of antibiotic or povidone iodine solution is placed in the eye prior to removal, and the suture is cut with a needle and removed with typing forceps. Prior to cutting the suture, the knot location should be identified. The suture should be cut in a manner that allows removal without dragging the knot across the graft–host wound junction, as pulling the knot across the wound may result in a wound dehiscence. A quick, jerk-like motion is best used for interrupted suture removal rather than a slow movement. A topical antibiotic drop should be placed following suture removal, and topical antibiotics are used for several days following suture removal



**Fig. 6.3** a Schematic diagram and b immediate postoperative photograph demonstrating the interrupted suture technique with 16 individual 10-0 nylon sutures.

**Table 6.1** Comparison of final mean keratometric astigmatism in various suture techniques

Author(s)	No. of eyes	Suture technique	Final average keratometric astigmatism (D)
Murta et al. [35]	61	IS	2.77±1.34
Busin et al. [8]	15	IS	4.89±3.16
Troutman et al. [50]	74	IS/CICS	4.4–5.1
Heidemann et al. [26]	156	IS	6.36
Binder [4]	204	CICS	2.6
Karabatsas et al. [27]	51	CICS	2.66±1.70
Gross et al. [25]	63 (group 1) 103 (group 2)	CICS CICS	2.94 3.27
Van Meter et al. [53]	31	CICS	3.2±1.9
Binder [6]	188	CICS	3.5
Filatov et al. [22]	20	CICS	3.9±2.5
Assil et al. [2]	19	CICS	4.07
Dursun et al. [18]	92	CICS	4.19±2.94
Van Meter et al. [53]	26	SCS	1.5±1.1
Serdarevic et al. [43]	25	SCS	1.75±1.04
Filatov et al. [22]	18	SCS	2.7±2.2
Ramirez et al. [39]	44	SCS	3.00±2.20
Karabatsas et al. [27]	44	SCS	3.12±2.62
Murta et al. [35]	14	SCS	3.90±1.70
Van Meter [51]	43	SCS	4.4±2.5
Assil et al. [2]	14	DCS	1.54
Clinch et al. [11]	30	DCS	2.66±0.24
Heidemann et al. [26]	57	DCS	3.75
Dolorico et al. [17]	91	DCS	3.98
Busin et al. [8]	22	DCS	3.98±3.69
Ramirez et al. [39]	48	DCS	4.2±2.1
Davison et al. [14]	33	DCS	4.5
Wiffen et al. [54]	313	DCS	4.6

IS interrupted suture technique, CICS combined interrupted and continuous suture technique, SCS single continuous suture technique, DCS double continuous suture technique, D Diopter

to lower subsequent risk of infection. In order to minimize discomfort and promote re-epithelialization, overnight patching with antibiotic ointment can be administered when many sutures are removed at once.

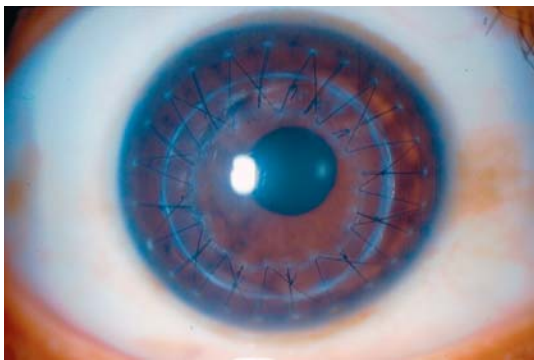
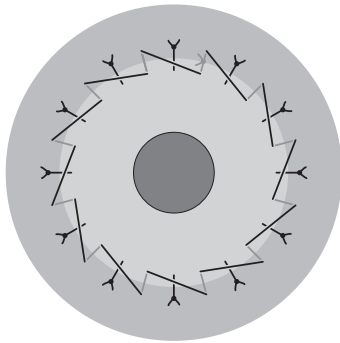
The interrupted suture technique has been associated with a wide range of postoperative astigmatism.

This technique can be associated with a high degree of astigmatism early in the postoperative course prior to selective suture removal. However, long-term keratometric astigmatism is quite acceptable, as reported in various clinical studies (Table 6.1).



#### 6.4.2 Combined Interrupted and Single Continuous Suture

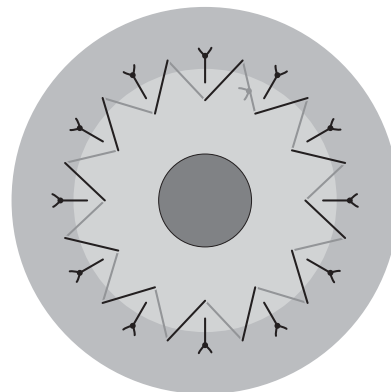
A combination of interrupted sutures and a continuous running suture (CICS) may be used to provide appropriate wound apposition and closure [2, 4–6, 25, 45]. One of the most commonly utilized suture patterns includes 12 interrupted sutures and a 12-bite continuous running suture (CS), although eight interrupted sutures and a 16-bite continuous running suture is also commonly employed (Fig. 6.4a, b). After placement of the four cardinal interrupted sutures, eight additional interrupted sutures are placed with 10-0 nylon suture. After the sutures are trimmed and the knots are buried, the CS is completed. Some surgeons employ qualitative keratometry to adjust or replace interrupted sutures before placement of the CS component. These surgeons generally repeat keratometry after CS placement as well. The CS is typically completed in a clockwise fashion, using 10-0 or 11-0 nylon suture, with the first bite midway between the 12 and 1 o'clock interrupted sutures. The CICS technique can be performed with radial bites equidistant between each of the interrupted sutures or by using an anti-



**Fig. 6.4** **a** Schematic diagram demonstrating appropriate suture placement using the combined interrupted and single continuous running keratoplasty technique with 12 interrupted sutures and a 12-bite running suture. **b** A slit-lamp photograph of the combined interrupted and continuous 12-bite running suture.

torque technique in which the apex of each bite in the donor cornea forms an isosceles triangle with each interrupted suture (Fig. 6.5). Several authors have suggested that the antitorque CR reduces the torquing effects and pressure distortion induced from each bite compared with radial running bites which may cause pressure distortion and torque when the running portion overlies the radial interrupted sutures [3, 19, 41, 47–49]. The CS depth is generally more superficial than are the deeper interrupted sutures, creating better approximation of Bowman's layer. The CS is run the entire 360°, with placement of a temporary knot at 12 o'clock. Additional slack is removed along the entire length of the CS to square the apical points within the corneal graft, and the suture is tied permanently at 12 o'clock with a 3-1-1 tying technique. The CS is then rotated with two tying forceps, and the knot is buried. Alternatively, the continuous running suture can be started within the wound, and finished at the same clock hour within the wound. A slipknot can be used to secure the suture and adjusted after the slack is relieved. Once tied permanently, the knot can be left in place after the ends are trimmed, and further manipulation of the CS to bury the knot is unnecessary.

The combination of interrupted and continuous running sutures allows for earlier removal of interrupted sutures to reduce postoperative astigmatism. If astigmatism is acceptable (generally less than 3 diopters [D]), sutures may be left alone until breakage, loosening, scarring, or vascularization develops, though the patient must be warned to call immediately if they develop a foreign-body sensation. Interrupted sutures can be removed as early as 4 weeks postoperatively to reduce corneal distortion and astigmatism as measured by keratometry, photokeratometry, or computerized corneal topography. Selective interrupted suture removal can be performed until only the running suture is left in place. The CS can be left in place



**Fig. 6.5** Schematic diagram of the combined interrupted and single continuous running pattern using an antitorque running technique.

indefinitely, but is generally removed 12–18 months following surgery. Astigmatism with this technique varies from 2.16 to 4.19 D, with selective removal of interrupted sutures followed by removal of the CS (Table 6.1; [6, 18, 20, 27, 42]). If significant astigmatism exists following removal of all interrupted sutures, corneal astigmatism correction with surgical methods will need to wait until the wound is stable enough to have the continuous running suture removed. This technique should not be performed in pediatric keratoplasty, tectonic keratoplasty, vascularized host corneas from previous inflammation or infection, multiple graft rejections, or conditions in which a risk of melting is present such as in autoimmune conditions like rheumatoid arthritis.

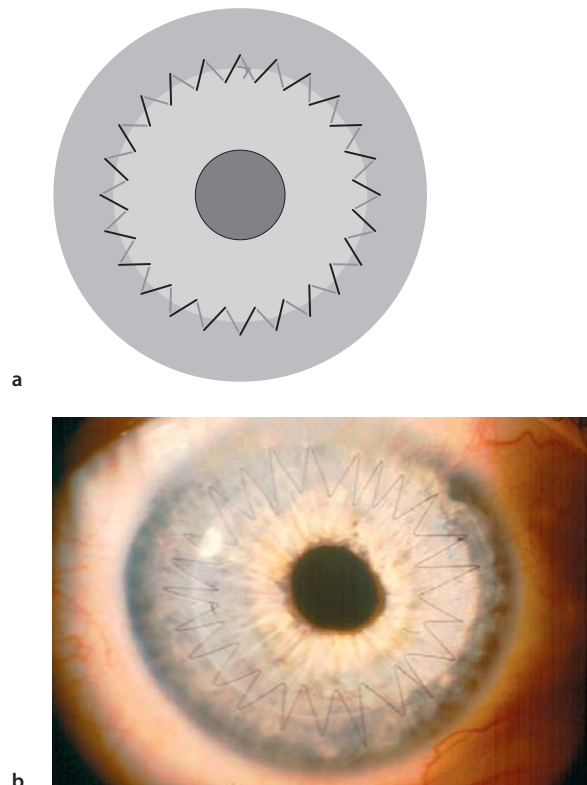
### 6.4.3 Single CRS Technique

The single continuous running suture technique was first described by Roper-Hall and popularized by McNeill in the United States [33, 40]. This technique carries the advantages of faster surgical time, one-time suture removal, and potential for suture adjustment intraoperatively and postoperatively. The disadvantages of this technique include increased technical difficulty, the increased risk of needle dullness, impaired wound integrity with only one improper bite, and difficulties of suture manipulation if the continuous suture breaks intraoperatively. The technique is typically performed with a 24-bite SCS of 10-0 nylon, although some surgeons have performed this with a 16-bite SCS. After the four cardinal sutures are placed as described above, the surgeon starts the SCS between 12 and 1 o'clock, and the suture is run clockwise until it is temporarily secured at 12 o'clock after completion. The surgeon places six bites per quadrant. The four cardinal sutures are removed, and the anterior chamber is filled to physiologic level before permanently tightening the knot to avoid a topographically flat donor cornea. Tightening of the is achieved by using tying forceps to release excess tension from each bite in a clockwise manner until the desired tension is achieved. Any excess tension from the lid speculum or a scleral fixation ring, if used, should be alleviated before the knot is tied permanently. Once the suture is tied permanently, it is trimmed to the knot, and the knot is buried. However, if the SCS is initiated within the wound, once tied and cut flush, the knot will be buried without further manipulation. The SCS can then be adjusted for appropriate sphericity with typing forceps using intraoperative qualitative keratocopy (Fig. 6.6a, b).

When using the SCS technique, the surgeon should pay careful attention to care of the needle point, place-

ment of continuous suture bites in a radial orientation, placement of evenly spaced, symmetrical bites at 95% depth, and prevention of suture breakage. If the SCS does inadvertently break, it should be removed if the pattern is in the first quadrant and restarted to prevent time delays. If the suture is broken in the final quadrants, a new suture can be spliced to proximal end with continuation, using the new needle (see Chap. 3 for suture-splicing technique description). The first spliced knot can be buried at the end of suturing, and the SCS can be tightened from the buried knot toward the suture completion at 12 o'clock. In some situations, if the initial suture end was left long, the SCS can be advanced to beyond the 12 o'clock position, and the spliced section can subsequently be removed, leaving only one knot to tie, as described earlier. When two knots are buried after splicing, suture adjustment should be performed in two separate portions to minimize astigmatism, but without exposure of either knot or repeat breakage.

While the SCS technique represents an efficient and effective method for keratoplasty wound closure, it can be problematic, as early suture removal may result in wound instability and unacceptably high astigmatism. Several clinical studies evaluating the single continu-



**Fig. 6.6** **a** Schematic diagram of the single continuous running keratoplasty suturing technique using 24 bites with 10-0 nylon suture. **b** A slit-lamp photograph of the single continuous running suture (CS) technique.

ous running suture describe low levels of astigmatism and more rapid visual recovery as compared with other suturing techniques when early postoperative suture adjustment techniques are implemented [22, 33, 42, 43, 45, 51–53]). Van Meter and colleagues compared the SCS, and CICS techniques and found that the former was associated with significantly less astigmatism ( $1.5 \pm 1.1$  D as compared with  $3.2 \pm 1.9$  D), fewer postoperative suture adjustments (0.9 as compared with 3.8), and earlier refractive stability (7 months earlier) (see Table 6.1 [53]). Patients undergoing intraoperative suture adjustment are reported to have significantly decreased astigmatism, more regular corneas, and better spectacle-corrected visual acuity until the running suture is eventually removed [42, 43, 51]. These data must be weighed against a 7.2% risk of spontaneous wound dehiscence following suture removal associated with this technique [1].

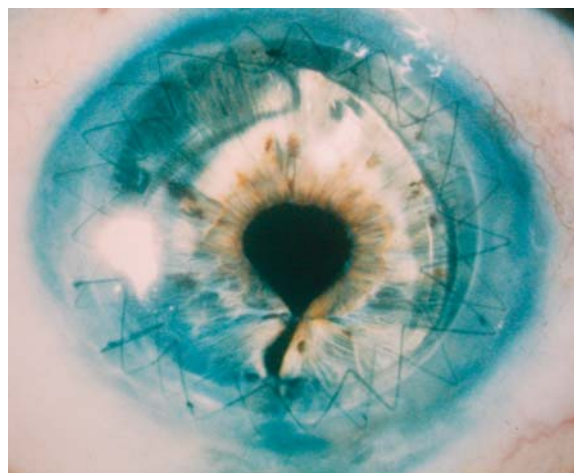
The ideal time for postoperative suture adjustment is 3–6 weeks following keratoplasty, since this provides adequate time for graft re-epithelialization and adequate measurement of astigmatism with corneal topography or keratometry. This timeframe also allows for easier manipulation of the SCS, with microsurgical instruments reducing risk of suture breakage, a risk that increases with later postoperative suture adjustments after more complete wound healing. SCS adjustment is performed with sterile tying forceps at the slit-lamp, following administration of a drop of topical antibiotic or topical povidone iodine and topical anesthetic. Keratometry, photokeratometry, or corneal topography should be reviewed prior to suture adjustment in order to establish the proper adjustment plan. Prior to suture adjustment, one tip of the tying forceps is placed through the epithelium and Bowman's layer along the graft–host junction at the steep meridian. After severing these anterior layers, the tip of the forceps is used to lift the suture, which is carefully advanced along the suture direction. This maneuver is performed at the steep meridian to serve as a relaxing incision in conjunction with suture adjustment. Once the suture moves, it is advanced loop by loop from the area of the flattest meridian and distributed to the area of the steepest meridian as measured by topography or keratometry until the tension has been evenly dispersed around the entire circumference of the wound. If a suture is too tight, adjustment plans should be aborted since attempting to adjust a very tight suture may lead to breakage. Avoidance of twisting the suture over the tips of the tying forceps and careful advancement of the suture along the line of suture placement can reduce the risk of the SCS breaking during adjustment. After completion of suture adjustment, the keratometric astigmatism should be measured after stabilization has occurred (typically in 2–3 weeks) to determine the effectiveness of the adjustment. Several

adjustments may be required to arrive at an acceptable level of keratometric astigmatism and subsequent visual acuity.

#### 6.4.4 Double Continuous Suture Technique

The double continuous running suture technique was first described in 1977 [32]. The DCS can be performed with two 10-0 nylon sutures, a 10-0 nylon suture and 11-0 nylon suture, or a 10-0 nylon suture and an 11-0 Mersilene suture. This technique provides the benefits of a SCS, with the added safety and security of a second SCS.

After placement of the four cardinal interrupted sutures, a 12-bite running 10-0 nylon CRS is placed. The CRS is run clockwise for  $360^\circ$  and tied temporarily at 12 o'clock. Each suture pass should be placed at 80% of the depth of the donor cornea and recipient cornea. The slack is removed and the knot is tied permanently at 12 o'clock and buried. The four cardinal sutures are removed. A second suture (10-0 or 11-0 nylon or 11-0 Mersilene) is placed between each of the previous bites and run clockwise for  $360^\circ$ . The second CRS is placed at 50–60% of the corneal depth to approximate Bowman's layer on both sides of the wound. The knot is tied temporarily at 12 o'clock, and the slack is removed, with a permanent tie completed at 12 o'clock (Fig. 6.7). The tension of the second suture should allow for only enough tension to take up slack in the suture. The second running suture permits early removal of the first CRS in 2–3 months, depending of the level of astigmatism. The second CRS may be left indefinitely, depending on the level of astigmatism, or it may be removed at 12–18 months.



**Fig. 6.7** Slit-lamp photograph depicting the double running suture technique. (Photo courtesy of Woodford Van Meter, M.D.)



The disadvantage of this technique is the time required to perform two continuous running sutures and requirement of significant expertise. This technique can potentially cause premature breakage or severing of the first suture with an improper pass of the second continuous running suture. In addition, care must be taken to avoid bending the needle during each pass or dulling the tips of the needle with each instrument grasp. Also, each suture bite must be regular and symmetrical in order to close the wound in an adequate fashion. Any irregular or improperly placed bite can lead to wound instability and inappropriate wound healing.

Several studies report excellent long-term stability with an acceptable range of postoperative astigmatism, and some authors consider it the most stable and secure suture technique [7, 14, 17, 32]. Rapid visual recovery and low levels of final astigmatism occur with early postoperative adjustment of the 10-0 nylon deep [11, 14, 32]. Marked variability exists in the literature regarding the effect of vision and postoperative astigmatism following suture removal with this technique, since some studies have shown an increase in astigmatism, whereas others have found no change or a decrease in the amount of astigmatism [7, 17, 32, 36, 46, 47, 50]. The deep 10-0 nylon CRS is typically removed first, followed by removal of the more anterior suture at 12–24 months. A retrospective study of 91 patients undergoing the DCS technique found an average postoperative keratometric astigmatism of 3.73 D after sutures were removed at an average follow-up of 13.7 months with 94% having best-correctable vision of 20/60 or better [17]. Average sutures-out keratometric astigmatism with this technique can vary widely as with all suture patterns in keratoplasty (see Table 6.1; [36, 54]).

---

### 6.5 Pediatric Keratoplasty

Pediatric keratoplasty deserves special mention, as these cases present a variety of challenges that are not routinely encountered in adult cases. Challenges in pediatric keratoplasty include smaller working space, decreased corneal dimensions, smaller ocular structures and shallow anterior chambers, more significant posterior pressure, and more scleral and corneal tissue elasticity. These factors provide heightened risks for intraoperative and postoperative complications, with a greater potential for iris prolapse or expulsion of ocular contents. A scleral fixation ring should be placed, with fixation to the episclera during the initial stages of the case to provide better globe stabilization and assist with management of increased posterior pressure and tissue elasticity.

In regard to suture placement, children have more elastic recipient corneas as compared with adults, more posterior pressure, more elastic donor corneas due to younger donor tissue, and a tendency for suture loosening sooner than adults, all of which account for greater suture pattern variability. This variability makes the single interrupted suture technique the ideal technique in pediatric cases, because it provides for better wound apposition and a more stable wound as sutures began to loosen over time. Continuous suture patterns are not recommended for pediatric cases. In pediatric keratoplasty, suture removal is often initiated as early as 2 weeks postoperatively, depending on the state of corneal healing. Frequent examinations under anesthesia are commonly encountered in pediatric cases for suture removal and adequate viewing of corneal grafts in cases where children are too young to cooperate with a slit-lamp examination. A team approach is often needed in these cases, with coordination of care between a pediatric ophthalmologist, a glaucoma specialist, and the corneal surgeon as amblyopia, glaucoma, and graft failure are very common occurrences in pediatric keratoplasty cases.

---

### 6.6 Suture-Related Complications

Complications from corneal suturing techniques in keratoplasty can be divided into intraoperative and postoperative complications. Intraoperative complications may include forward movement of the lens–iris diaphragm, disrupting suturing by iris prolapse and creating a potential for lens damage or expulsion. The most dreaded complication creating this forward shift is a suprachoroidal hemorrhage, a complication that can progress to an expulsive choroidal hemorrhage with expulsion of intraocular contents. Other intraoperative complications may include violation of, or contact with, the anterior lens capsule, leading to a traumatic cataract; inadvertent iridectomy when excising the diseased cornea; and damage to the donor endothelium from tissue manipulation or poor handling techniques. Improper suture placement can lead to iris incarceration, lens violation, and a higher risk of suture abscess or endophthalmitis in the postoperative course. Improper suture tension can create undesirable astigmatism or donor–recipient mismatch, which can lead to difficulty in creating a watertight wound once suturing is completed, as well as significant astigmatic refractive error postoperatively.

While intraoperative complications for an experienced corneal surgeon typically remain limited, postoperative complications are numerous and are commonly encountered. Postoperative complications following suture techniques in keratoplasty include

wound leak with a flat anterior chamber, hyphema, traumatic cataract, iris prolapse and peripheral iris synechiae to the graft–host junction, secondary glaucoma, and retrocorneal membranes [15]. Loose sutures in the immediate or late postoperative course can lead to suture vascularization or wound dehiscence [10]. In particular, late postoperative wound dehiscence has been reported in one study with the 24-bite SCS in 7.2% of patients, with the majority of cases occurring within 2 weeks of suture removal [1]. While wound dehiscence typically occurs soon after removal of sutures, late postoperative wound dehiscence has also been reported 10–19 years after suture removal [38]. Infections such as endophthalmitis, suture abscesses, and graft ulceration may also occur in association with loose sutures. Postkeratoplasty surface keratopathy is one of the most common postoperative complications after astigmatism. It can present in many forms including hurricane keratopathy, filamentary keratitis, keratitis medicamentosa, persistent epithelial defects, and superficial hypertrophic dendri-form epitheliopathy (SHDE) [19, 28]. These surface complications can indirectly affect sutures and require observation for potential suture melting or infiltration when present.

Astigmatism is the most common postoperative suture-related complication in keratoplasty. Factors felt to increase the risk of high amounts of astigmatism include increased external pressure exerted on the globe such as a tight lid speculum or improperly sutured scleral fixation ring. Other factors related to astigmatism include inappropriate trephination procedures, donor–recipient mismatch, sutures with inappropriate tension, inconsistent suture depth, lack of suture radi-ality, asymmetrical suture placement, and/or malposi-tioned cardinal sutures.

## 6.7 Future Challenges

Despite the many advances made in corneal surgery over the last decade, the ideal suturing technique remains to be identified. Regardless of the various advances in instrumentation, surgical technique, and our knowledge of immunobiology, perfect and reproduc-ible results in corneal surgery and keratoplasty in par-ticular do not exist. Although the success of penetrat-ing keratoplasty is commonly over 90% in routine cases, intraoperative and postoperative complications will always remain a risk with corneal surgery [7]. De-spite the increased success of contemporary kerato-plasty, suture-related complications continue to exist. Regardless of these inherent risks, postoperative com-plications such as astigmatism, wound dehiscence, and suture-related infections can be diminished with care-

ful attention to appropriate suture technique and care-ful and close follow-up of patients after corneal sur-gery techniques. Nonetheless, the fundamentals of corneal wound closure and appropriate tissue apposi-tion represent the core foundation of knowledge for the corneal surgeon.

## References

1. Abou-Jaoude ES, Brooks M, Katz DG et al (2002) Spontaneous wound dehiscence after removal of single continuous penetrating keratoplasty suture. *Ophthalmology* 109:1291–1296
2. Assil KK, Zarnegar SR, Schanzlin DJ (1992) Visual outcome after penetrating keratoplasty with double continuous or combined interrupted and continuous suture wound closure. *Am J Ophthalmol* 114:63–71
3. Au Y-K, Mahjoub SB, Hart JC (1990) Suture patterns and corneal graft rotation in the cadaver eye. *Ophthalmic Surg* 21:472–474
4. Binder PS (1985) Reduction of postkeratoplasty astigmatism by selective suture removal. *Dev Ophthalmol* 11:86–90
5. Binder PS (1985) Selective suture removal can reduce postkeratoplasty astigmatism. *Ophthalmology* 92:1412–1416
6. Binder PS (1988) The effect of suture removal on post-keratoplasty astigmatism. *Am J Ophthalmol* 105:637–645
7. Bourne WM (1981) Current techniques for improved visual results after penetrating keratoplasty. *Ophthalmic Surg* 12:321–327
8. Busin M, Monks T, Al-Nawaiseh I (1998) Different suturing techniques variously affect the regularity of post-keratoplasty astigmatism. *Ophthalmology* 105:1200–1205
9. Brady SE, Rapuano CJ, Arensten JJ et al (1989) Clinical indications for and procedures associated with penetrating keratoplasty 108:118–122
10. Christo CG, Rooij J, Geerards AJM et al (2001) Suture-related complications following keratoplasty. *Cornea* 20:816–819
11. Clinch TE, Thompson HW, Gardner BP et al (1993) An adjustable double running suture technique for keratoplasty. *Am J Ophthalmol* 116:201–206
12. Cosar CB, Sridhar MS, Cohen EJ (2002) Indications for penetrating keratoplasty and associated procedures, 1996–2000. *Cornea* 21:148–151
13. Cottingham AJ (1980) Residual astigmatism following keratoplasty. *Ophthalmology* 87(S):113
14. Davison J, Bourne WM (1980) Results of penetrating keratoplasty using a double running suture technique. *Arch Ophthalmol* 99:1591–1595
15. Dhanda RP, Kalevar V (1972) Corneal surgery. *Int Ophthalmol Clin* 12:3–420
16. Dobbins KRB, Price FW, Whitson WE (2000) Trends in the indications for penetrating keratoplasty in the Mid-western United States. *Cornea* 19:813–816
17. Dolorico AMT, Tayyani, Ong HV et al (2003) Shortterm and longterm visual and astigmatic results of an oppos-ing 10-0 nylon double running suture technique for penetrating keratoplasty. *J Am Coll Surg* 197:991–999
18. Durson D, Forster RK, Feuer WJ (2002) Suturing technique for control of postkeratoplasty astigmatism and myopia. *Trans Am Ophthalmol* 100:51–60
19. Eisner G (1980) *Eye Surgery: An Introduction to Operative Technique*. Springer, Berlin Heidelberg New York, pp38–40

20. Eliason JA, McCulley JP (1990) A comparison between interrupted and continuous suturing techniques in keratoplasty. *Cornea* 9:10–16
21. Feiz V, Mannis MJ, Kandavel G et al (2001) Surface keratopathy after penetrating keratoplasty. *Trans Am Ophthalmol Soc* 99:159–168
22. Filatov V, Steinert RF, Talamo JH (1993) Postkeratoplasty astigmatism with single running suture or interrupted sutures. *Am J Ophthalmol* 115:715–721
23. Fine M (1962) Technique of penetrating keratoplasty. Symposium on the Cornea. *Trans New Orleans Acad Ophthalmol*. Mosby, St. Louis, pp 132–142
24. Fine M (1970) Techniques of keratoplasty. *Int Ophthalmol Clin* 10:271–296
25. Gross RH, Poulsen EJ, Davitt S et al (1997) Comparison of astigmatism after penetrating keratoplasty by experienced cornea surgeons and cornea fellows. *Am J Ophthalmol* 123:636–643
26. Heidemann DG, Sugar A, Meyer RF et al (1985) Over-sized donor grafts in penetrating keratoplasty. *Arch Ophthalmol* 103:1807–1811
27. Karabatsas CH, Cook SD, Figueiredo FC et al (1998) Combined interrupted and continuous versus single continuous adjustable suturing in penetrating keratoplasty. *Ophthalmology* 105:1991–1998
28. Lee WB, Mannis MJ, Mehra N et al (2005) Superficial hypertrophic dendriform epitheliopathy: A follow-up series. *Cornea* 25:273–276
29. Lois N, Kowal VO, Cohen EJ et al (1997) Indications for penetrating keratoplasty and associated procedures, 1989–1995. *Am J Ophthalmol* 16:623–629
30. Mannis MJ, Tran L, A Panorama, 1789–1999 (1999) In: Mannis MJ, Mannis AA (eds) *Corneal transplantation: a history in profile*. Wayenborgh, Belgium
31. Mannis MJ, Krachmer JH (1981) Keratoplasty: a historical perspective. *Surv Ophthalmol* 25:333–338
32. McNeill JI, Kaufman HE (1977) A double running suture technique for keratoplasty: earlier visual rehabilitation. *Ophthalmic Surg* 8:58–61
33. McNeill JI, Wessels F (1989) Adjustment of single continuous suture to control astigmatism after penetrating keratoplasty. *Refract Corneal Surg* 5:216–223
34. Melles GRH, Binder PS (1990) A comparison of wound healing in sutured and unsutured corneal wounds. *Arch Ophthalmol* 108:546–548
35. Murta JN, Amaro L, Tavares C et al (1994) Astigmatism after penetrating keratoplasty. *Doc Ophthalmol* 87:331–336
36. Musch DC, Meyer RF, Sugar A (1988) The effect of removing running sutures on astigmatism after penetrating keratoplasty. *Arch Ophthalmol* 106:488–492
37. Olson RJ (1988) Prevention of astigmatism in corneal transplant surgery. *Int Ophthalmol Clin* 28:37–45
38. Pettinelli DJ, Starr CE, Stark WJ (2005) Late traumatic corneal wound dehiscence after penetrating keratoplasty. *Arch Ophthalmol* 123:853–856
39. Ramirez M, Hodge DO, Bourne WM (2001) Keratometric results during the first year after keratoplasty: Adjustable single running suture technique versus double running technique. *Ophthalmic Surg Lasers* 32:370–374
40. Roper-Hall M (1985) Control of postoperative astigmatism. *Br J Ophthalmol* 69:348–351
41. Rowsey JJ (1987) Prevention and correction of corneal transplant astigmatism. *Trans New Orleans Acad Ophthalmol* 35:35–51
42. Serdarevic ON (1994) Refractive corneal transplantation: control of astigmatism and ametropia during penetrating keratoplasty. *Int Ophthalmol Clin* 34:13–33
43. Sedarevic ON, Rneard GJ, Pouliquen Y (1995) Randomized clinical trial of penetrating keratoplasty. *Ophthalmology* 102:1497–1503
44. Stainer GA, Perl T, Binder PS (1982) Controlled reduction of postkeratoplasty astigmatism. *Ophthalmology* 89:668–676
45. Temnycky GO, Lindahl KJ, Aquavella JV (1991) Early visual rehabilitation following keratoplasty using a single continuous adjustable suture technique. *Ophthalmic Surg* 22:208–212
46. Troutman RC (1974) *Microsurgery of the anterior segment of the eye*, vol. 1. Mosby, St. Louis, pp 187–195
47. Troutman RC (1977) *Microsurgery of the anterior segment of the eye*, vol. 2. Mosby, St. Louis, pp 40–41
48. Troutman RC, Willard DE (1965) Management of the aphakic patient. Symposium on cataracts. *Trans New Orleans Academy of Ophthalmology*. Mosby, St. Louis, pp 261–279
49. Troutman RC, Meltzer M (1972) Astigmatism and myopia in keratoconus. *Trans Am Ophthalmol Soc* 70:265–277
50. Troutman RC, Gaster RN (1980) Surgical advances and results of keratoconus. *Ophthalmology* 90:131–136
51. Van Meter W (1996) The efficacy of a single continuous nylon suture for control of post keratoplasty astigmatism. *Tr Am Ophth Soc* 44:1157–1180
52. Van Meter W, Katz DG (2004) Keratoplasty suturing techniques. In: Krachmer JH, Mannis MJ, Holland EJ (eds) *Cornea*, 2nd edn. Mosby, St. Louis
53. Van Meter WS, Gussler JR, Solomon KD et al (1991) Postkeratoplasty astigmatism control. *Ophthalmology* 98:177–183
54. Wiffen SJ, Maguire LJ, Bourne WM (1997) Keratometric results of penetrating keratoplasty with the Hessburg-Barron and Hanna trephine systems using a standard double-running suture technique. *Cornea* 16:306–313