
Blepharitis: current strategies for diagnosis and management

W. Bruce Jackson, MD, FRCSC

ABSTRACT • RÉSUMÉ

Background: The aim of this article is to present a consensus on the appropriate identification and management of patients with blepharitis based on expert clinical recommendations for 4 representative case studies and evidence from well-designed clinical trials.

Methods: The case study recommendations were developed at a consensus panel meeting of Canadian ophthalmologists and a guest ophthalmologist from the U.K., with additional input from family doctors and an infectious disease/medical microbiologist, which took place in Toronto in June 2006. A MEDLINE search was also conducted of English language articles describing randomized controlled clinical trials that involved patients with blepharitis.

Results: Blepharitis involving predominantly the skin and lashes tends to be staphylococcal and (or) seborrheic in nature, whereas involvement of the meibomian glands may be either seborrheic, obstructive, or a combination (mixed). The pathophysiology of blepharitis is a complex interaction of various factors, including abnormal lid-margin secretions, microbial organisms, and abnormalities of the tear film. Blepharitis can present with a range of signs and symptoms, and is associated with various dermatological conditions, namely, seborrheic dermatitis, rosacea, and eczema. The mainstay of treatment is an eyelid hygiene regimen, which needs to be continued long term. Topical antibiotics are used to reduce the bacterial load. Topical corticosteroid preparations may be helpful in patients with marked inflammation.

Interpretation: **Blepharitis can present with a range of signs and symptoms, and its management can be complicated by a number of factors. Expert clinical recommendations and a review of the evidence on treatment supports the practice of careful lid hygiene, possibly combined with the use of topical antibiotics, with or without topical steroids. Systemic antibiotics may be appropriate in some patients.**

Contexte : Présentation d'un consensus d'experts en clinique sur l'identification et le traitement appropriés des patients atteints de blépharite. Les recommandations résultent d'un examen de 4 études de cas et de données d'essais cliniques bien pensés.

Méthodes : Les recommandations résultant de l'étude de cas ont été mises au point par consensus lors d'une réunion d'experts à laquelle ont participé en juin 2006, à Toronto, un groupe d'ophtalmologistes canadiens et un ophtalmologiste invité du Royaume-Uni, avec l'apport de médecins de famille et d'un microbiologiste médical et spécialiste en maladies infectieuses. On a aussi effectué sur MEDLINE une recherche dans les articles publiés en anglais et décrivant des essais cliniques contrôlés et randomisés chez des patients atteints de blépharite.

Résultats : La blépharite, qui affecte surtout la peau et les cils, a tendance à être de nature staphylococcique et (ou) séborrhéique, alors que l'implication des glandes de Méibomius peut être séborrhéique, obstructive, ou une combinaison des deux. La pathophysiologie de la blépharite montre une interaction complexe de divers facteurs comprenant des sécrétions anormales sur la marge de la paupière, des organismes microbiens et des anomalies du film lacrymal. La blépharite peut s'accompagner d'un éventail de signes et de symptômes et s'associer à diverses conditions dermatologiques, notamment la dermatite séborrhéique, l'acné rosacée et l'eczéma. Le traitement de base porte sur l'hygiène des paupières, qu'il faut maintenir à long terme. Les antibiotiques topiques servent à réduire la charge bactérienne. Les préparations topiques de corticostéroïdes peuvent aider les patients qui ont une inflammation marquée.

Interprétation : **La blépharite peut présenter un éventail de signes et de symptômes, et un certain nombre de facteurs peuvent en compliquer le traitement. Les recommandations des experts en clinique et une revue des données sur le traitement appuie la pratique attentive de l'hygiène des paupières à laquelle on peut ajouter des antibiotiques topiques, avec ou sans stéroïdes topiques. Les antibiotiques systémiques peuvent être indiqués pour certains patients.**

From the University of Ottawa Eye Institute, Ottawa, Ont.

Originally received Aug. 22, 2007. Revised Dec. 28, 2007

Accepted for publication Jan. 9, 2008

Published online Mar. 12, 2008

Correspondence to W. Bruce Jackson, MD, University of Ottawa Eye Institute, The Ottawa Hospital, General Campus, 501 Smyth Rd., Suite W6253, Box 307, Ottawa ON K1H 8L6; bjackson@ohri.ca

This article has been peer-reviewed. Cet article a été évalué par les pairs.

Can J Ophthalmol 2008;43:170-9

doi:10.3129/i08-016

Blepharitis is a generic term for eyelid inflammation but generally refers to different types of inflammation involving the skin, lashes, and meibomian glands and is among the most frequently encountered ocular diseases. The condition is usually chronic, intermittent (with exacerbations and remissions), and typically bilateral. It is a complex disorder with a number of causes and overlapping signs and symptoms, and its management can be frustrating and challenging.^{1,2}

The aim of this article is to present a consensus on the appropriate identification and management of patients with blepharitis based on expert clinical recommendations for 4 representative case studies and evidence from well-designed clinical trials.

The case study recommendations were developed at a consensus panel meeting of Canadian ophthalmologists and a guest ophthalmologist from the U.K., with additional input from family doctors and an infectious disease/medical microbiologist, which took place in Toronto in June 2006. The members of the panel are listed in the Acknowledgements section.

METHODS

Classification and etiology

There is no single, universally accepted classification system for the various presentations of blepharitis. The ideal system may eventually be structured according to underlying disease pathophysiology, but this is incompletely understood.

Historically, blepharitis has been divided into anterior forms (affecting the anterior lid margin and eyelashes) and posterior forms (affecting the meibomian glands).^{1,2} Both forms can be inflammatory or infectious, as shown in Table 1.

Alternatively, blepharitis can be classified according to the most commonly presenting signs and symptoms into staphylococcal, seborrheic, mixed staphylococcal and seborrheic, and meibomian gland dysfunction (MGD).

Pathophysiology

The pathophysiology of blepharitis is complex and thought to represent the interaction of various factors, including abnormal lid-margin secretions, lid-margin

organisms, and a dysfunctional precorneal tear film.

The tear film lipid layer (the outer layer of the ocular tear film) reduces evaporation of water from the underlying aqueous layer of the film. Meibomian gland secretions, which contain lipids, help maintain the stability of the tear film. The polar lipids (principally phospholipids) in the meibomian oil interact with the aqueous layer of the tear film and enable the film to spread over the eye.

In blepharitis, various changes can occur that may destabilize the film. In particular, a reduction in the quantity of secretions reaching the eyelid margin (and therefore the tear film) and changes in the composition of the secretions can have this effect.^{6,7}

The orifices leading to the meibomian glands can become keratinized and obstructed secondary to an inflamed lid margin. In seborrheic blepharitis, there may actually be excess lipid production initially, but this leads to encrustation of the lid margin, which eventually blocks the gland orifices.⁸ Finally, scarring can lead to retraction of the orifice such that secretions are not delivered to the correct part of the eyelid margin.⁶

Alterations in the composition of the meibomian secretions occur in patients with chronic blepharitis.^{6,7} Decreased amounts of polar lipids may result in destabilization of the lipid tear layer, uneven spreading, and increased aqueous tear evaporation. In obstructive meibomian gland disease the altered nonpolar lipids, including triglycerides and cholesterol esters, will raise the melting point, leading to thickening of the meibum, ductal plugging stagnation, and pouting of the meibomian gland orifices. Further clarification of the specific lipid changes in patients with blepharitis is necessary, but even our limited understanding helps to explain the associated evaporative dry eye seen in these patients.

The most common organisms isolated from patients with chronic blepharitis include *Staphylococcus epidermidis*, *Propionibacterium acnes*, corynebacteria, and *Staphylococcus aureus*.^{9–11} Groden et al.¹⁰ found that the first of these 3 organisms was present in patients with blepharitis more often than in control patients. In addition, blepharitis patients were found to be more heavily colonized than control patients. McCulley and Dougherty¹¹ found that *S. aureus* was isolated from the subgroup of blepharitis patients in the mixed staphylococcal/seborrheic group more than in controls. Lipolytic exoenzymes produced by *S. epidermidis* and *S. aureus*, including triglyceride lipase, cholesterol esterase, and wax esterase, hydrolyze wax and sterol esters with the release of highly irritating free fatty acids and other products, resulting in the disruption of the tear film integrity.⁶ Some patients are more heavily colonized than others, and this could also be the effect of the altered lipids stimulating the growth of *S. epidermidis* and *S. aureus* on the eyelid margin.⁶

Over time, the interaction of these various factors results in instability and thinning of the tear film. This allows more of the aqueous component of tears to evaporate,

Table 1—Etiological classification of blepharitis*

Inflammatory	Infectious
Seborrheic	Bacterial (most commonly <i>Staphylococcus aureus</i> , <i>S. epidermidis</i> and <i>Propionibacterium acnes</i>)
Meibomian gland dysfunction	Viral (<i>Molluscum contagiosum</i> , <i>Herpes simplex</i> , varicella-zoster, common warts)
Allergic (atopic and contact dermatitis)	Fungal (uncommon; immunosuppressed pts)
Associated with dermatosis (rosacea)	Parasitic (<i>Demodex folliculorum</i> , <i>Pediculosis pubis</i>)

*Adapted with permission from McCulley et al.,⁹ Mathers et al.,⁴ and Tasman et al.⁵

increasing tear osmolarity and the level of inflammatory cytokines; it ultimately damages the ocular surface and results in the dysfunctional tear syndrome.^{2,8}

The fungus *Pityrosporum* has been found to be associated more frequently with meibomianitis in patients with blepharitis than in controls, likely because of copious secretions containing fatty acids, which support the growth of the fungus, on the lid margin.¹² *Demodex* infestation of the facial skin has been implicated in rosacea and blepharitis. Microscopic examination of epilated eyelashes with cylindrical dandruff (sleeves) that cuff the lashes will reveal the mite. It is suggested that ocular irritation, conjunctival inflammation, and keratitis may be found in patients with *Demodex* infestation of the eyelids, which may improve with lid scrubs with 50% tea tree oil, a new treatment to eradicate the mites.¹³

Clinical presentation

General ocular symptoms that may accompany blepharitis are sore eyelids, eyes feeling irritated, itchy, burning, or gritty, red eyes, dry or watery eyes, increased frequency of blinking, foreign body sensation, photophobia, contact lens intolerance, and eyelids sticking together (particularly in the morning).^{1,2}

Signs include swollen eyelids, inflamed lid margins (with redness and thickening), scaling, crusting, irregularity (tylosis) and (or) ulceration of the lid margins, and altered eyelash appearance (loss [madarosis], individual lash poliosis, and lashes broken, misdirected, or crusted with fibri-

nous or sebaceous matter [collarettes, scurf, and sleeves]), as well as secondary alterations to the conjunctiva (such as conjunctivitis) and cornea (corneal inflammation and ulceration). Sties and chalazia are also common.^{1,2}

Typical presentations for the major subtypes of blepharitis are summarized in Table 2. Inflammation of the anterior margin is usually caused by staphylococcal, seborrheic, or mixed blepharitis, whereas inflammation of the posterior margin is associated with MGD.² A patient history that includes symptoms associated with systemic disease (e.g., lupus erythematosus, scleroderma), recent systemic and topical medications, and contact lens use can be important in determining the diagnosis.¹

Evidence of various dermatological conditions that can occur in association with blepharitis should be sought. These include seborrheic dermatitis, rosacea, and atopic dermatitis (Table 2).

MGD

MGD is the most common affliction of the meibomian gland. It is characterized by inflammatory changes at the lid margins and changes in the anatomy of the orifices and character of the secretions, which distinguish it from more anterior inflammation. With a prevalence of 39%–50% among patients that have disease of the meibomian glands, the changes can be primary or secondary, focal or diffuse. Secondary changes are seen with cutaneous and dermatological diseases that involve the sebaceous glands, such as seborrheic dermatitis and seborrhea.

Table 2—Summary of typical clinical presentations for the most common forms of blepharitis*

Presentation	Anterior blepharitis (Staphylococcal)	Anterior blepharitis (Seborrheic)	Posterior blepharitis (Meibomian gland dysfunction)
Demographics	Predominantly young to middle-aged women	Older age group, no gender difference	—
Eyelid deposits	Collarettes or cuffs of fibrin (matted, hard scales) extending from the base of and along lashes as a sleeve	Greasy scales (“scurf”) on lid margins and around lashes	Thick lipid secretions (may be foamy), with plugged and pouting meibomian gland orifices
Eyelid ulcerations	Fine at the base of lashes	—	—
Eyelid scarring	May occur	—	Common with longstanding disease
Eyelash absence and/or breakage	Frequent	Rare	Unusual
Eyelash misdirection	Frequent	Rare	May occur with longstanding disease
Chalazion	Rare	Rare	Occasional to frequent (may be multiple)
Sty	May occur	—	—
Conjunctiva	Mild to moderate injection, occasional phlyctenules	Mild injection	Mild to moderate injection, papillary reaction on tarsal conjunctiva
Aqueous tear deficiency	Frequent (50% have keratoconjunctivitis sicca)	Frequent (25%–40% have dry eye)	Frequent (50% with ocular rosacea have dry eye)
Cornea	Inferior punctate epithelial erosions, marginal infiltrates, neovascularization, pannus, scarring, thinning, and phlyctenules	Usually not affected	Inferior punctate epithelial erosions, marginal infiltrates, neovascularization, pannus, scarring, and phlyctenules
Associated dermatological disorder	Atopic eczema (uncommon)	Seborrheic dermatitis	Rosacea

*Adapted with permission from Frith et al.¹⁴

The most frequent association is with rosacea, in which meibomian gland involvement is seen in up to 50% of cases. It occurs much less frequently in patients with ichthyosis and psoriasis.

Hypersecretion of the meibomian glands (meibomian seborrhea or seborrheic MGD) can occur, seen in the release of large quantities of lid oil at the lid margin with expression. It is usually associated with seborrheic dermatitis but can also be seen with rosacea and atopy.

Tear evaporation is usually increased but may remain normal with seborrheic MGD. Patients may complain of burning red eyes with little to be seen except for the excessive secretions and whitish froth on the lid margin due to the free fatty acids. Mild conjunctival injection and superficial punctate keratitis in the lower third are frequently seen.

Obstructive MGD is strongly associated with skin disease and characterized by obstruction (ductal plugging or pouting) and dilation of the meibomian ducts with squamous metaplasia, abnormal keratinization, and foreign-body reaction. The lipid volume is decreased with thickened secretions and gland drop out. Loss of the meibomian gland orifice can also occur, with cicatricial changes that lead to retroplacement of the orifices. These changes can be seen with cicatricial conjunctival diseases.

Posterior blepharitis in its mildest form may be asymptomatic, or it can cause chronic irritation and inflammation of the eyelids. Symptoms may relate to the release of inflammatory cytokines, ductal dilation, the products of lipolysis released into the tear film, and increased evaporation from the tear layer. As tear osmolarity rises, aqueous tear flow and volume decrease, initiating a vicious inflammatory cycle. Combined anterior and posterior lid disease can be seen, especially with seborrheic blepharitis and atopy.

Relation between rosacea, MGD, and dry eye

Rosacea is a chronic skin condition that frequently involves the eye, usually with lid and (or) ocular surface inflammation. The primary features of rosacea are flushing, nontransient erythema, papules and pustules, and telangiectasia. One or more of these features across the central area of the face is typical of rosacea. Secondary features that may occur are a burning or stinging sensation of the cheeks, red plaques, dry facial skin, phymatous changes, including irregular thickening of the skin (e.g., rhinophyma,) and ocular changes.^{15,16} It is thought that the manifestations of rosacea probably all have an inflammatory origin.

Ocular rosacea can affect the eyelids, conjunctiva, sclera, and cornea. Many patients with ocular rosacea lack the typical facial skin manifestations initially, although telangiectasia and erythema of the lid margin are generally present.^{15,17} Eyelid changes include MGD in up to 90% of cases and anterior blepharitis in approximately half of patients.¹⁵ Many rosacea patients have mixed seborrhea with obstructive MGD. The dry eye is often the result of ocular surface irritation that suppresses tear production.

Treatment

The treatment of blepharitis is generally based on eyelid hygiene, topical and systemic antibiotics and, in some cases, topical anti-inflammatory agents: corticosteroids and cyclosporin A.

Eyelid hygiene

The traditional management of blepharitis has been to begin a regimen to improve eyelid hygiene, starting with application of warm compresses to the closed eyelids for several minutes to soften and loosen encrustations and warm the secretions from meibomian glands. The usual method is to place a washcloth that has been soaked in warm water on the closed eyelids for 5 to 10 minutes. This is typically followed by firm massage of the lid margins to enhance the flow of secretions from the meibomian glands, particularly in patients with posterior blepharitis. The eyelid is held taut at the outer corner with one hand while the index finger of the other hand sweeps from the inner corner of the lid toward the ear while applying pressure or simple direct pressure on the lids, whichever the patient finds most helpful. This is repeated several times. Although patients with anterior blepharitis do not usually require massage, many will have MGD as well. The regimen is usually performed twice daily, but some patients benefit from repeated warm compresses during the day. Excessive massage of the eyelid often leads to irritation and is not recommended.^{1,2}

Hygiene generally involves removing the crusts by gently rubbing the base of the eyelashes with cotton balls, Q-tips, a commercial eyelid scrub, or a 50:50 mixture of water and baby shampoo on a quilted makeup remover pad. Many patients will do this after a shower. Commercial eyelid scrubs available in Canada include Lid-Care (Novartis Ophthalmics, Mississauga, Ont.), Blepharoshampoo (Ophthapharma, Montréal, Qué.), and OCuSOFT Lid Scrub (OCuSOFT Inc, Richmond, Tex.). Hypoallergenic soap and sodium bicarbonate in water have also been used.^{2,18} It is important not to scrub too vigorously or to irritate the conjunctiva with Q-tips. Cleansing is usually done once or twice daily initially. Continuing some form of regular lid hygiene over the long term helps prevent relapses.¹

Uncomplicated seborrheic blepharitis may be controlled adequately by eyelid hygiene alone,² although these patients usually have seborrhea of the scalp, and the management of that using antiseborrheic shampoos is also helpful. Other forms of blepharitis may require drug treatment in addition.

Pharmacotherapy

Decreasing the degree of bacterial colonization on the lids that drives inflammation often improves symptoms, but elimination of all bacteria with antibiotics is neither possible nor desirable. Staphylococcal blepharitis or blepharoconjunctivitis usually responds well to a topical antibiotic. Specific recommendations vary.^{1,2} Erythromycin or bacitracin ointments have been the most frequently used

topical antibiotics for blepharitis, but their availability in Canada has been inconsistent. Fusidic acid is a good alternative and avoids the use of erythromycin, which has shown increased resistance to *Staphylococcus*. Fusidic acid gel applied to the lid margin at bedtime will cover *S. epidermidis* and *S. aureus*, including methicillin-resistant *S. aureus*, and has been shown to be effective for the treatment of bacterial conjunctivitis.¹⁹ There was no trend toward increasing resistance of *S. aureus* to fusidic acid in Canada between 1999 and 2005.²⁰ The long-term use of fourth-generation fluoroquinolones for the control of lid disease should be discouraged because of increasing resistance; however, these preparations are recommended for preoperative anterior segment prophylaxis to reduce bacteria on the lid margin and achieve therapeutic levels in the anterior chamber. Aminoglycosides do not have the same broad coverage against Gram-positive organisms as fusidic acid and are more likely to cause toxic symptoms and signs when used for prolonged periods.

Pharmaceutical preparations that remain in contact with the lid margin for longer periods of time (e.g., ointments or gels) may be preferable to solutions. Such preparations are typically applied to the eyelids 1 to 4 times daily for up to 2 weeks and then less frequently for several weeks after the inflammation has settled (e.g., once nightly for 8 weeks). Regimens will vary depending on the severity of the inflammation.^{1,2} When there is sensitivity or pain associated with topical antibiotic administration, or in atopic individuals, nonpreserved formulations can be useful (e.g., fusidic acid unit dose).

Systemic antibiotics are rarely needed to treat staphylococcal blepharitis except in cases that do not respond adequately to topical therapy and for secondary infections of the meibomian glands.² For example, cloxacillin and rifampin are used for intracellular *Staphylococcus*. Topical vancomycin 50 mg/mL 4 times daily has been used to treat resistant *Staphylococcus*.²¹

In patients with recurrent staphylococcal infection, *Staphylococcus* carrier status, or the presence of a resistant strain, additional therapies are employed.

Approximately 20% of individuals almost always carry 1 type of *S. aureus* strain and are called persistent carriers.²² Such individuals may be among those patients who present to the ophthalmologist with recurring infections. Isolation of *S. aureus* from the anterior nares, rectum, and wounds is required to identify patients who are colonized with the organism. Several studies have assessed the efficacy of decolonization strategies in preventing *S. aureus* infections, focusing mainly on specific populations.^{23–27}

Although there are no published studies that have assessed the efficacy of decolonization of *Staphylococcus*-carrying patients with blepharitis, it may be reasonable to consider a regimen consisting of antibacterial washes, such as chlorhexidine gluconate, and topical antibiotics, such as mupirocin or fusidic acid applied to the nares with or without oral antistaphylococcal antibiotics.

MGD patients who do not respond to eyelid hygiene and patients with ocular rosacea (most of whom will have MGD) may benefit from orally administered tetracyclines, including tetracycline, doxycycline, or minocycline.^{1,15,17,28} Doxycycline is often started at a dose of 100 mg twice daily for 3–4 weeks, then tapered to a dose of 100 mg once daily for several months. Low doses of doxycycline 20 mg may prove to be as effective when long-term therapy is required. Tetracycline may be started at 250 mg 4 times daily, and tapered after 3–4 weeks to twice and then once daily. The length of drug treatment varies depending on the severity of disease, and the regimen itself is often intermittently stopped because of medication tolerance. The rationale for the use of tetracyclines is based on several factors: improved symptoms in patients with ocular rosacea,^{17,28} improved tear break-up time in patients with rosacea and MGD,²⁹ decreased eyelid flora, and evidence that tetracycline decreases lipase production in both *S. epidermidis* and *S. aureus*.³⁰ Clarithromycin can be used as an alternative for those patients who cannot tolerate tetracycline, and erythromycin has proved beneficial in children.¹⁶

Topical corticosteroids are generally reserved for severe inflammation and complications such as phlyctenules, severe conjunctival injection, infectious eczematoid dermatitis, or marginal keratitis. The lowest effective dose should be employed, and a tapering course administered.^{1,2} Patients requiring prolonged steroid treatment should be monitored closely by an ophthalmologist to assess the continued need for therapy, as well as to avoid potential complications such as increased intraocular pressure and corneal and lens changes. Antibiotic–steroid combinations are also available in either ointment or eye-drop form and may be suitable for use in some patients. Examples include tobramycin–dexamethasone; neomycin or polymyxin B with hydrocortisone; neomycin or polymyxin B with dexamethasone; sulfacetamide–prednisolone acetate; and sulfacetamide–prednisolone sodium phosphate.⁸ There is also some evidence that cyclosporin A is helpful in patients with MGD and dry eye.^{31,32} A trial of treatment with cyclosporin A in patients with MGD found that although it did not improve symptoms significantly compared with placebo, the number of meibomian gland inclusions did decrease significantly.³¹ The use of 2% topical metronidazole has also been shown to be beneficial in the treatment of rosacea blepharitis.

Lastly, management of the dry eye with minimally or nonpreserved tears, gels, and ointments, environmental control, moisture goggles, and nutritional supplements, such as omega-3 fatty acids from fish oils and flax seed oil, may decrease inflammatory cytokines and improve tear function.¹ Anti-inflammatory treatment may be necessary, including short-term use of topical corticosteroids and cyclosporin A. Punctal plugs should be avoided in patients with chronic blepharitis at least until the inflammation is well controlled. Preventing tear drainage raises the level of

cytokines in the tear film, potentially resulting in increased surface inflammation.

RESULTS

Illustrative patient reports

The following case studies illustrate the range of clinical signs and symptoms that may be present in patients with blepharitis and the factors that can complicate diagnosis and management.

Case study 1: anterior marginal blepharitis with lid margin notching

A 33-year-old man had a history of eyelid burning and mild itching accompanied by redness of the lid margin and crusting. There was a family history of lid infections, and as a child he had had recurrent sties. He had had a couple of chalazia removed. Examination revealed an anterior blepharitis with a lid notch from a previous chalazion excision. The lid margin showed crusting with both scurf and collarettes (Fig. 1A). Fig. 1B shows a patient with more severe

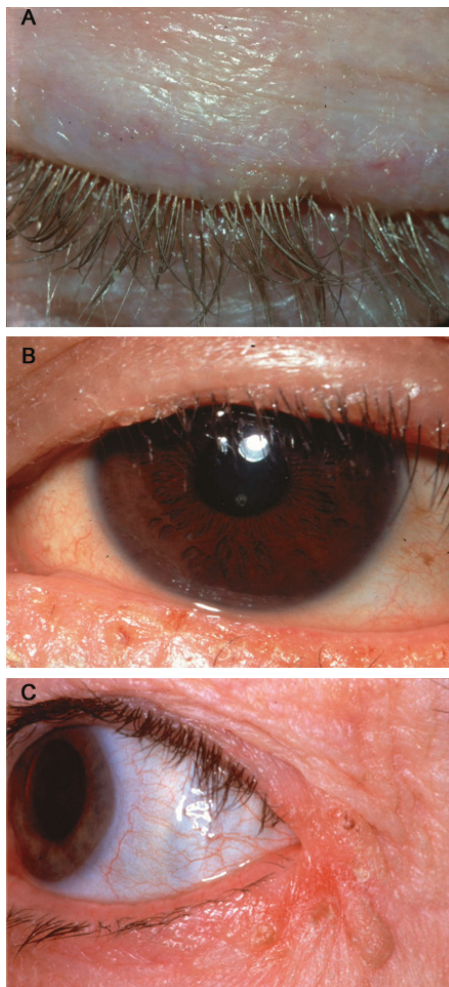


Fig. 1—(A) Anterior marginal blepharitis with lid notch. (B) Ulcerative blepharitis. (C) Angular blepharitis positive for *Staphylococcus aureus*.

ulcerative blepharitis with crusting, ulceration, and madarosis. Fig. 1C shows a patient with angular blepharitis, positive by culture for *S. aureus*.

Management includes taking a thorough ocular and family history. For chronic, unresponsive infections, specimens for culture should be obtained, and scraping should be carried out for atypical cells. In 15%–20% of cases *S. aureus* will be recovered; the rest have coagulase-negative *Staphylococcus*. With the increase in community-acquired methicillin-resistant *S. aureus*, it is important to obtain specimens for culture from health care workers presenting with chronic blepharitis. Occasionally *Moraxella* will be cultured in chronic blepharoconjunctivitis.

The panel agreed that lid care is the most important part of the treatment, including warm compresses and good lid hygiene to remove the crusts and debris from the lid margin. Antibiotics can reduce the bacterial load and the number of recurrences but are not necessary in all cases. Ointments that can be applied to the lid margin at bedtime are preferred. Fusidic acid gel gives excellent coverage for *Staphylococcus* and is well tolerated. Erythromycin ointment can be used, but resistant organisms are more common. A few members of the panel use an antibiotic–steroid combination, such as tobramycin 0.3%–dexamethasone 0.1% ointment for short periods of time. Others try to avoid the prolonged use of aminoglycosides. Many will start off prescribing the antibiotic to be taken every night and then 2 to 3 times a week once the disease is controlled, before stopping it.

For the patient with marked ulcerative blepharitis, long-term lid hygiene and topical antibiotics are helpful to avoid flare-ups. Topical steroids, such as fluorometholone 0.1%, can reduce inflammation. If the patient has atopic dermatitis and posterior blepharitis, additional therapy may be required with topical tacrolimus or pimecrolimus plus systemic tetracycline. The use of lubricants is often overlooked but should be encouraged to avoid tear film abnormalities leading to ocular surface damage.

Case study 2: conjunctivitis/blepharitis with eczema

A 45-year-old man had irritated eyes and an occasional foreign-body sensation. He had frequent bouts of lid crusting with debris on his lashes. Examination revealed a mixed anterior blepharitis with greasy scales and collarettes, plus moderate conjunctival hyperemia with more lid crusting in his right eye. He had a history of mild atopic dermatitis. Culture, carried out because of the conjunctivitis, revealed *S. aureus* (Fig. 2A).

S. aureus is frequently cultured from the lid margins of patients with atopic dermatitis. The conjunctivitis may be due to bacterial infection, toxicity, or the underlying immunologic mechanisms. Good lid hygiene forms the basis of treatment combined with a topical antibiotic. Because of the atopy, a preservative-free antibiotic such as fusidic acid gel or moxifloxacin would be helpful. The atopic conjunctivitis can be treated using a dual-acting antihistamine–mast-cell stabilizer such as olopatadine 0.1% twice daily. A

short course of a topical steroid (fluorometholone) will also help. If the skin is involved, a mild steroid cream such as 0.5% or 1% hydrocortisone can be beneficial. Topical tacrolimus or pimecrolimus has been shown to settle the skin reaction down quickly. A number of these patients will also have MGD and will respond to oral administration of doxycycline 100 mg bid for 2–4 weeks and then 100 mg daily for another 8 weeks. Artificial tears may be helpful if there is an associated dry eye. Topical cyclosporin A has proven very useful in patients with atopic blepharoconjunctivitis (Fig. 2B) avoiding many of the complications of steroids, but is not yet available in Canada except through the Special Access Program of Health Canada (http://www.hc-sc.gc.ca/dhp-mps/acces/index_e.html).

In patients with eczematoid reaction on their eyelids it is important to look for the etiologic cause, which may be atopic dermatitis, an eczematoid reaction from the exotoxins of *Staphylococcus*, or drug-induced hypersensitivity (e.g., from long-term topical antibiotics).

A 25-year-old nurse working in a newborn nursery had a chronic unilateral blepharoconjunctivitis and infections around her ear lobes. *S. aureus* was cultured from the lid margins of both eyes, the conjunctiva, the anterior nares, and the ear lobe. In addition to the lid margin hygiene, compresses, and topical antibiotic, treatment was begun with rifampin and cloxacillin orally, and mupirocin was administered to the anterior nares. Since she was colonized with *Staphylococcus*, chlorhexidine gluconate baths were also prescribed.

Case study 3: meibomian gland dysfunction (rosacea, dry eye)

A 65-year-old woman was being followed for severe burning and irritation of her eyes, which was not improv-

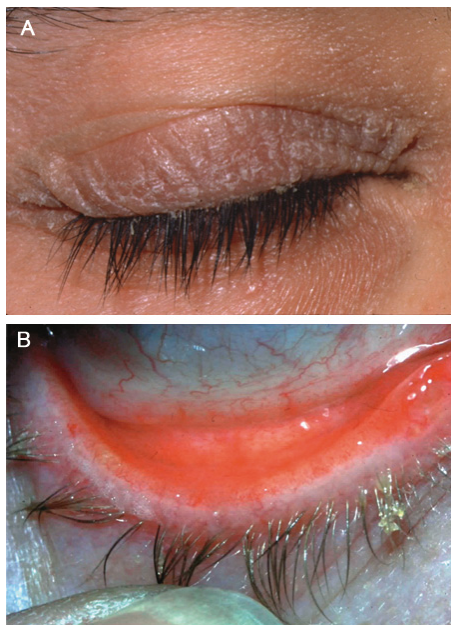


Fig. 2—(A) Blepharitis with dermatitis. (B) *Staphylococcus aureus* blepharoconjunctivitis.

ing with local eye care. At times her eyes felt dry, and she had a history of recurrent chalazia. There was obvious facial rosacea with erythema and telangiectasia in the flush areas of the face. The lid margin showed hyperemia and telangiectasis, as well as mild anterior blepharitis. There was meibomian hypersecretion on lid margin pressure, with plugging of the meibomian glands. Fine punctate stains were present on the inferior cornea. Fig. 3 shows the conjunctival flush typical of rosacea and corneal scarring from phlyctenular keratitis.

The consensus panel recommended lid hygiene scrubs, hot compresses (to liquefy the lipid secretions), and meibomian gland expression. In addition, doxycycline 100 mg bid is frequently given if lid hygiene alone is not sufficient. If there is a response over the first 4–6 weeks, the dose is reduced to 100 mg/day. Further reduction to doxycycline 20 mg/day can maintain control. A weak topical steroid may help reduce the inflammation, and if there is an associated dry eye the steroid can be combined with cyclosporin A (which reduces inflammatory cytokines and improves tear secretion) for a couple of weeks, after which the topical steroid is stopped and the cyclosporin A continued for the long term at twice a day if effective. Punctal plugs are not recommended with lid margin inflammation, as this keeps prolonged higher levels of cytokines present on the ocular surface.

Case study 4: prophylaxis for anterior segment surgery with concurrent blepharitis

A 72-year-old woman had ocular rosacea, mild anterior and posterior blepharitis, and a moderately dry eye. She had mild symptoms and had not been receiving any therapy except for warm compresses and lid margin massage. She occasionally used artificial tears.

The panel noted that the lid disease must be controlled before proceeding with cataract surgery. Lid cultures are not necessary unless the disease is resistant to treatment. Fusidic acid gel or another topical antibiotic, such as erythromycin, can be used along the lid margin, systemic doxycycline should be started and continued for 1–3 months, and nonpreserved tears should be started. The patient should be assessed for control of the blepharitis before any decision to proceed with surgery.

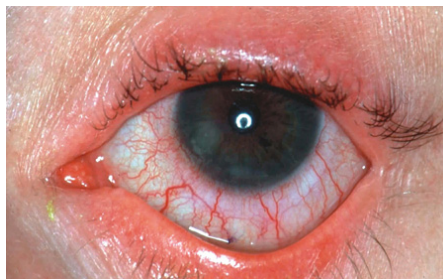


Fig. 3—Meibomian gland dysfunction: rosacea, dry eye, and keratitis.

Three to 7 days before surgery, a fourth-generation fluoroquinolone should be started 4 times daily and then used for 1–2 weeks postoperatively. For the first 24 hours postoperatively it should be used every 2 hours while the patient is awake.

The nasal lacrimal ducts need to be irrigated before surgery because they can be a reservoir of *Streptococcus pneumoniae* or *S. aureus*. Postoperatively, the lid disease needs to be followed, with special attention to the dry eye, which can be aggravated by surgery.

Literature review

Best-evidence data on blepharitis treatment from randomized, controlled clinical trials are summarized in Table 3. Trials were identified from a search of English language articles on MEDLINE (1966 to the present). Search terms were “randomized controlled trial” AND “blepharitis” OR “meibomian”.

The results of these trials confirm that topical antibiotics are effective at reducing infection in blepharitis.^{32,33,35,41} They also support the use of oral tetracyclines,^{29,44} as well as *N*-acetylcysteine,⁴³ in patients with posterior blepharitis or MGD. Recent studies indicate that cyclosporine can offer benefits in posterior blepharitis.^{31,40} In patients with ocular rosacea, oral tetracycline improved tear film break-up time but not tear production (Table 3).²⁹ A partially randomized trial (not tabulated) found that tetracycline provided faster relief of symptoms than doxycycline but noted that the doxycycline regimen might be easier to comply with in the long term.²⁸

Randomized trials specifically in children are not available. However, a retrospective case series (*n* = 29) and a prospective survey (*n* = 44) found that oral erythromycin was effective in children with blepharoconjunctivitis.^{45,46}

Last, subjective symptoms quite often persist despite objective improvements in infection and signs of inflammation (Table 3).

Reference	Blepharitis type	No. of pts (duration)	Treatment groups	Results*
Adenis et al. ³³	Bacterial blepharitis/ conjunctivitis	39 (7 d)	CIP 0.3% vs. FUS 1%	Bacterial eradication: 81% CIP vs. 72% FUS Clinical cure/improvement: 95% CIP vs. 89% FUS Clinical cure: 62% CIP vs. 28% FUS
Adenis et al. ³⁴	Bacterial blepharitis/ conjunctivitis	41 (7 d)	CIP 0.3% vs. RIF 1%	Bacterial eradication: 68% CIP vs. 77% RIF Clinical cure/improvement: 95% CIP vs. 91% RIF Clinical cure: 53% CIP vs. 23% RIF
Bloom et al. ³⁵	Blepharitis/ blepharoconjunctivitis	464 (7 d)	CIP 0.3% vs. TOB 0.3%	Bacterial eradication: 55% CIP vs. 53% TOB Clinical cure/improvement: 82% CIP vs. 84% TOB
Donshik et al. ³⁶	Chronic staphylococcal blepharoconjunctivitis	79 (2 wk)	GEN 0.3% + BET 0.1% vs. GEN 0.3% vs. BET 0.1% vs. PL	GEN+BET and GEN > BET and PL for staphylococcus eradication Improvement in clinical sign score: GEN+BET 73% vs. BET 76% vs. GEN 62% vs. PL 57%
Goto et al. ³⁷	Noninflamed obstructive MGD	20 (2 wk)	Castor oil 2%/ polyoxyethylene castor oil 5% vs. PL	Castor oil > PL for symptom score, tear interference grade, tear evaporation test, rose bengal staining, tear break-up time, gland orifice obstruction
Hyndiuk et al. ³⁸	Bacterial blepharitis	39 (7 d)	MER 1% vs. PL	MER > PL for bacterial counts, clinical sign cure, clinical sign improvement No significant difference for symptom improvement
Nelson et al. ³⁹	Seborrheic or mixed seborrheic/ staphylococcal blepharitis	40 (8 wk)	KET 2% vs. PL	No significant difference between KET and PL for symptom improvement or signs of inflammation
Perry et al. ³¹	Posterior/MGD	26 (3 mo)	CsA 0.05% vs. PL	CsA > PL for lid margin vascular injection, tarsal telangiectasis, fluorescein staining, meibomian gland inclusions No significant difference between CsA and PL for symptom improvement
Rubin and Rao ⁴⁰	Posterior blepharitis	30 (3 mo)	CsA 0.05% vs. TOB 0.3%/DEX 0.1%	CsA > TOB/DEX for improvement in Schirmer score (2.33 mm vs. 0.9 mm), fluorescein break-up time (1.87 s vs. 1.3 s), secretion quality score (0.77 vs. 0.3) Improvement in blurred vision, burning, itching and tearing with CsA vs. TOB/DEX: 47% vs. 40%, 47% vs. 33%, 40% vs. 33%, and 53% vs. 53% No significant difference between groups for lid telangiectasia, lid erythema or tear lysozyme levels
Seal et al. ⁴¹	Chronic symptomatic blepharitis	43 (2 mo)	FUS 1% vs. OXY 500 mg/d vs. combination	Symptom improvement: in patients with rosacea: FUS 75% vs. OXY 50% vs. combination 35% in patients without rosacea: FUS 0% vs. OXY 25% vs. combination 30%
Shulman et al. ⁴²	Bacterial blepharitis or conjunctivitis	95 (4 d)	NEO 3500 IU/mL/ POL 6000 IU/mL/DEX 0.1% vs. DEX 0.1%	NEO/POL/DEX > DEX for bacterial eradication (50% vs. 17%), reduction in bacterial count (90% vs. 34%) NEO/POL/DEX > DEX for improvement in conjunctival discharge but no significant difference for other signs/symptoms
Yalcin et al. ⁴³	Chronic posterior blepharitis	40 (1–4 mo)	NAC 300 mg/d/TOB/PRED vs. TOB/PRED	NAC/TOB/PRED > TOB/PRED for increase in fluorescein break-up time (5.3 s vs. -0.5 s), improvement in mucus ferning grade (1.2 vs. 0.6)
Yoo et al. ⁴⁴	Chronic MGD	150 (1 mo)	DOX 400 mg/d vs. DOX 40 mg/d vs. PL	High-dose DOX and low-dose DOX > PL for tear break-up time, Schirmer test, symptom improvement No significant difference between effects of high- and low-dose DOX
Zengin et al. ²⁹	Ocular rosacea/MGD	28 (5 mo)	TET 1 g/d for 4 wk then 500 mg/d vs. MGET	Neither TET nor MGET improved Schirmer test (tear secretion) vs. baseline TET but not MGET improved tear film break-up time vs. baseline

* > significantly better (*p* < 0.05).
 Note: BET, betamethasone; CIP, ciprofloxacin; CsA, cyclosporine; DEX, dexamethasone; DOX, doxycycline; FUS, fusidic acid; GEN, gentamicin; KET, ketoconazole; MER, mercuric oxide; MGD, meibomian gland dysfunction; MGET, meibomian gland expression therapy; NAC, *N*-acetylcysteine; NEO, neomycin; OXY, oxytetracycline; PL, placebo; POL, polymixin-B; PRED, prednisolone; RIF, rifamycin; TET, tetracycline; TOB, tobramycin.

INTERPRETATION

As illustrated by the case studies discussed in this article, blepharitis can present with a range of signs and symptoms, and its management can be complicated by a number of factors. A review of the evidence on the treatment of blepharitis supports the practice of careful lid hygiene, possibly combined with the use of topical antibiotics with or without topical steroids. Systemic antibiotics may be appropriate in some patients.

Members of the consensus panel meeting, Toronto, June 2006: Steven Bailey, ophthalmologist, London, U.K.; Hélène Boisjoly, ophthalmologist, Montréal, Qué.; Michael Csanadi, family physician, Fort Erie, Ont.; Marilyn Ekins, ophthalmologist, Winnipeg, Man.; W. Bruce Jackson (Moderator), ophthalmologist, Ottawa, Ont.; Ron Jans, ophthalmologist, Calgary, Alta.; William Lu, family physician, Oshawa, Ont.; Gary Morrow, ophthalmologist, Toronto, Ont.; Alicia Sarabia, microbiologist, Toronto, Ont.; Chris Seamone, ophthalmologist, Halifax, N.S.; Allan Slomovic, ophthalmologist, Toronto, Ont.

The consensus panel meeting was sponsored by an educational grant from LEO Pharma Inc. Financial support for the preparation of this manuscript was provided by LEO Pharma Inc. Editorial support was provided by Katherine Croom.

REFERENCES

1. American Academy of Ophthalmology, Ophthalmic News and Education Network. *Blepharitis: Preferred Practice Pattern Guideline*. 2003. Available at: <http://www.aao.org/education/guidelines/ppp/blepharitis.cfm>. Accessed August 15, 2007.
2. National Library for Health. Prodigy Guidance: Blepharitis. Available at: http://www.cks.library.nhs.uk/blepharitis/in_summary. Accessed August 15, 2007.
3. McCulley JP, Dougherty JM, Deneau DG. Chronic blepharitis: classification and mechanisms. In: Suran A, Gery I, Nussenblatt RB, eds. *Immunology of the Eye, Workshop III*; 1981:55–72.
4. Mathers WD, Jester JV, Shields WJ. Differentiation of chronic blepharitis by meibomian function: a new classification system. *Ophthalmology* 1990;97(Suppl.):138.
5. Tasman W, Vardhan A, Mahajan S. *Duane's Clinical Ophthalmology*. Philadelphia, Pa.: Lippincott Williams and Wilkins; 2000.
6. Bron AJ, Sci FM, Tiffany JM. The contribution of meibomian disease to dry eye. *Ocul Surf* 2004;2:149–65.
7. McCulley JP, Shine WE. Meibomian secretions in chronic blepharitis. *Adv Exp Med Biol* 1998;438:319–26.
8. Sowka JW, Gurwood AS, Kabat AG. *Handbook of Ocular Disease Management*. 2006. Available at: <http://www.revoptom.com/handbook>. Accessed August 15, 2007.
9. Dougherty JM, McCulley JP. Comparative bacteriology of chronic blepharitis. *Br J Ophthalmol* 1984;68:524–8.
10. Groden LR, Murphy B, Rodnite J, Genvert GI. Lid flora in blepharitis. *Cornea* 1991;10:50–3.
11. McCulley JP, Dougherty JM. Bacterial aspects of chronic blepharitis. *Trans Ophthalmol Soc U K* 1986;105 (Pt 3):314–8.
12. Seal DV, McGill JI, Jacobs P, Liakos GM, Goulding NJ. Microbial and immunological investigations of chronic non-ulcerative blepharitis and meibomianitis. *Br J Ophthalmol* 1985;69:604–11.

13. Kheirkhah A, Casas V, Raju VK, Tseng SC. Corneal manifestations of ocular demodex infestation. *Am J Ophthalmol* 2007;143:743–9.
14. Frith P, Gray R, MacLennan S, Ambler P, eds. *The Eye in Clinical Practice*. 2nd ed. London: Blackwell Science; 2001.
15. Alvarenga LS, Mannis MJ. Ocular rosacea. *Ocul Surf* 2005;3:41–58.
16. Cohen AF, Tiemstra JD. Diagnosis and treatment of rosacea. *J Am Board Fam Pract* 2002;15:214–7.
17. Akpek EK, Merchant A, Pinar V, Foster CS. Ocular rosacea: patient characteristics and follow-up. *Ophthalmology* 1997;104:1863–7.
18. Key JE. A comparative study of eyelid cleaning regimens in chronic blepharitis. *CLAO J* 1996;22:209–12.
19. Jackson WB, Low DE, Dattani D, Whitsitt PF, Leeder RG, MagDougall R. Treatment of acute bacterial conjunctivitis: 1% fusidic acid viscous drops vs. 0.3% tobramycin drops. *Can J Ophthalmol* 2002;37:228–37.
20. Rennie RP. Susceptibility of *Staphylococcus aureus* to fusidic acid: Canadian data. *J Cutan Med Surg* 2006;10:277–80.
21. Fleischer AB, Hoover DL, Khan JA, Parisi JT, Burns RP. Topical vancomycin formulation for methicillin-resistant *Staphylococcus epidermidis* blepharoconjunctivitis. *Am J Ophthalmol* 1986;101:283–7.
22. Kluytmans J, van Belkum A, Verbrugh H. Nasal carriage of *Staphylococcus aureus*: epidemiology, underlying mechanisms, and associated risks. *Clin Microbiol Rev* 1997;10:505–20.
23. Uttley L, Vardhan A, Mahajan S, Smart B, Hutchison A, Gokal R. Decrease in infections with the introduction of mupirocin cream at the peritoneal dialysis catheter exit site. *J Nephrol* 2004;17:242–5.
24. Kluytmans JA, Wertheim HF. Nasal carriage of *Staphylococcus aureus* and prevention of nosocomial infections. *Infection* 2005;33:3–8.
25. Wertheim HF, Verveer J, Boelens HA, van Belkum A, Verbrugh HA, Vos MC. Effect of mupirocin treatment on nasal, pharyngeal, and perineal carriage of *Staphylococcus aureus* in healthy adults. *Antimicrob Agents Chemother* 2005;49:1465–7.
26. Konvalinka A, Errett L, Fong IW. Impact of treating *Staphylococcus aureus* nasal carriers on wound infections in cardiac surgery. *J Hosp Infect* 2006;64:162–8.
27. Simor AE, Phillips E, McGeer A, et al. Randomized controlled trial of chlorhexidine gluconate for washing, intranasal mupirocin, and rifampin and doxycycline versus no treatment for the eradication of methicillin-resistant *Staphylococcus aureus* colonization. *Clin Infect Dis* 2007;44:178–85.
28. Frucht-Pery J, Sagi E, Hemo I, Ever-Hadani P. Efficacy of doxycycline and tetracycline in ocular rosacea. *Am J Ophthalmol* 1993;116:88–92.
29. Zengin N, Tol H, Gunduz K, Okudan S, Balevi S, Endogru H. Meibomian gland dysfunction and tear film abnormalities in rosacea. *Cornea* 1995;14:144–6.
30. Dougherty JM, McCulley JP, Silvany RE, Meyer DR. The role of tetracycline in chronic blepharitis. Inhibition of lipase production in staphylococci. *Invest Ophthalmol Vis Sci* 1991;32:2970–5.
31. Perry HD, Doshi-Carnevale S, Donnenfeld ED, Solomon R, Biser SA, Bloom AH. Efficacy of commercially available topical cyclosporine A 0.05% in the treatment of meibomian gland dysfunction. *Cornea* 2006;25:171–5.
32. Perry HD, Donnenfeld ED. Topical 0.05% cyclosporin in the treatment of dry eye. *Expert Opin Pharmacother* 2004;5:2099–107.

33. Adenis JP, Colin J, Verin P, Riss I, Saint-Blancat P. Ciprofloxacin ophthalmic solution in the treatment of conjunctivitis and blepharitis: a comparison with fusidic acid. *Eur J Ophthalmol* 1996;6:368–74.
34. Adenis JP, Colin J, Verin P, Saint-Blancat P, Malet F. Ciprofloxacin ophthalmic solution versus rifamycin ophthalmic solution for the treatment of conjunctivitis and blepharitis. *Eur J Ophthalmol* 1995;5:82–7.
35. Bloom PA, Leeming JP, Power W, Laidlaw DA, Collum LM, Easty DL. Topical ciprofloxacin in the treatment of blepharitis and blepharoconjunctivitis. *Eur J Ophthalmol* 1994;4:6–12.
36. Donshik P, Kulvin SM, McKinley P, Skowron R. Treatment of chronic staphylococcal blepharoconjunctivitis with a new topical steroid anti-infective ophthalmic solution. *Ann Ophthalmol* 1983;15:162–7.
37. Goto E, Shimazaki J, Monden Y, et al. Low-concentration homogenized castor oil eye drops for noninflamed obstructive meibomian gland dysfunction. *Ophthalmology* 2002;109:2030–5.
38. Hyndiuk RA, Burd EM, Hartz A. Efficacy and safety of mercuric oxide in the treatment of bacterial blepharitis. *Antimicrob Agents Chemother* 1990;34:610–3.
39. Nelson ME, Midgley G, Blatchford NR. Ketoconazole in the treatment of blepharitis. *Eye* 1990;4:151–9.
40. Rubin M, Rao SN. Efficacy of topical cyclosporin 0.05% in the treatment of posterior blepharitis. *J Ocul Pharmacol Ther* 2006;22:47–53.
41. Seal DV, Wright P, Ficker L, Hagan K, Troski M, Menday P. Placebo controlled trial of fusidic acid gel and oxytetracycline for recurrent blepharitis and rosacea. *Br J Ophthalmol* 1995;79:42–5.
42. Shulman DG, Sargent JB, Stewart RH, Mester U. Comparative evaluation of the short-term bactericidal potential of a steroid-antibiotic combination versus steroid in the treatment of chronic bacterial blepharitis and conjunctivitis. *Eur J Ophthalmol* 1996;6:361–7.
43. Yalcin E, Altin F, Cinhuseyinoglu F, Arslan MO. N-acetylcysteine in chronic blepharitis. *Cornea* 2002;21:164–8.
44. Yoo SE, Lee DC, Chang MH. The effect of low-dose doxycycline therapy in chronic meibomian gland dysfunction. *Korean J Ophthalmol* 2005;19:258–63.
45. Hammersmith KM, Cohen EJ, Blake TD, Laibson PR, Rapuano CJ. Blepharokeratoconjunctivitis in children. *Arch Ophthalmol* 2005;123:1667–70.
46. Viswalingam M, Rauz S, Morlet N, Dart JK. Blepharokeratoconjunctivitis in children: diagnosis and treatment. *Br J Ophthalmol* 2005;89:400–3.

Key words: blepharitis, meibomian glands, ocular rosacea