

Presumed Bilateral Optic Nerve Sheath Meningiomas Presenting as Optic Neuritis

Raja A. Sawaya, MD, Charif Sidani, MD, Nadim Farah, MD, and Roula Hourani-Risk, MD

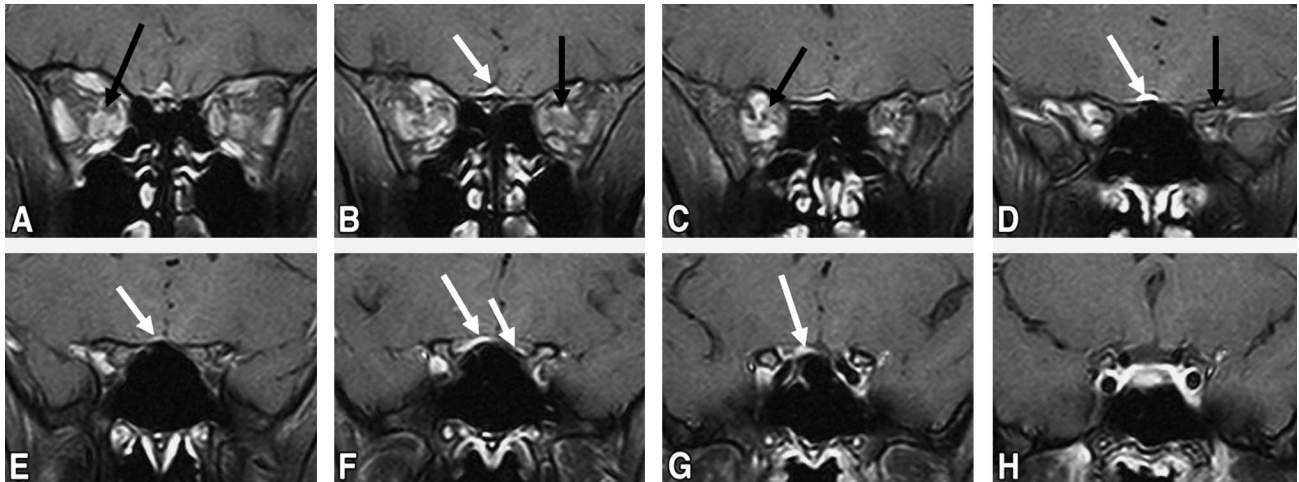


FIG. 1. Postcontrast coronal orbital MRI shows enhancing lesions that encase the orbital optic nerves (*black arrows*) and extend to partially encase their prechiasmatic portions (*white arrows*).

Abstract: A 30-year-old man who developed acute blurred vision in the right eye and right periorcular pain on eye movement proved to have a bilateral optic neuropathy and imaging evidence suggestive of bilateral optic nerve sheath meningiomas. This is an unusual presentation for optic nerve meningioma but a reminder that this entity may mimic optic neuritis.

(*J Neuro-Ophthalmol* 2008;28:55–57)

Departments of Neurology (RAS), Diagnostic Radiology (CS, RH-R), and Ophthalmology (NF), American University of Beirut Medical Center, Beirut, Lebanon.

Address correspondence to Raja A. Sawaya, MD, Associate Professor of Clinical Medicine, Neurologist, Director Clinical Neurophysiology Laboratory, American University Medical Center, PO Box 113-6044/C-27, Beirut, Lebanon; E-mail: rs01@aub.edu.lb

A 30-year-old healthy man presented with a 1-week history of blurred vision in the right eye and mild right eye pain upon eye movement. He had no headache, diplopia, or other neurologic symptoms.

Examination revealed a best-corrected visual acuity of 20/25 in the right eye and 20/20 in the left eye. An afferent pupillary defect was present in the right eye. The external ocular examination was otherwise normal. Mild optic disc edema of the right eye was visible on ophthalmoscopy. Results of the rest of the cranial nerve and neurologic examination were normal.

Visual fields, performed on the Octopus perimeter, were normal in the left eye but showed a dense nerve fiber bundle defect concentrated mainly in the inferior field of the right eye (Fig. 2).

Visual evoked potentials were severely delayed in both eyes with P100 latencies of 139 ms in the right eye and 133 ms in the left eye (Fig. 3). Optic neuritis of the right eye and a subclinical optic neuropathy of the left eye were diagnosed.

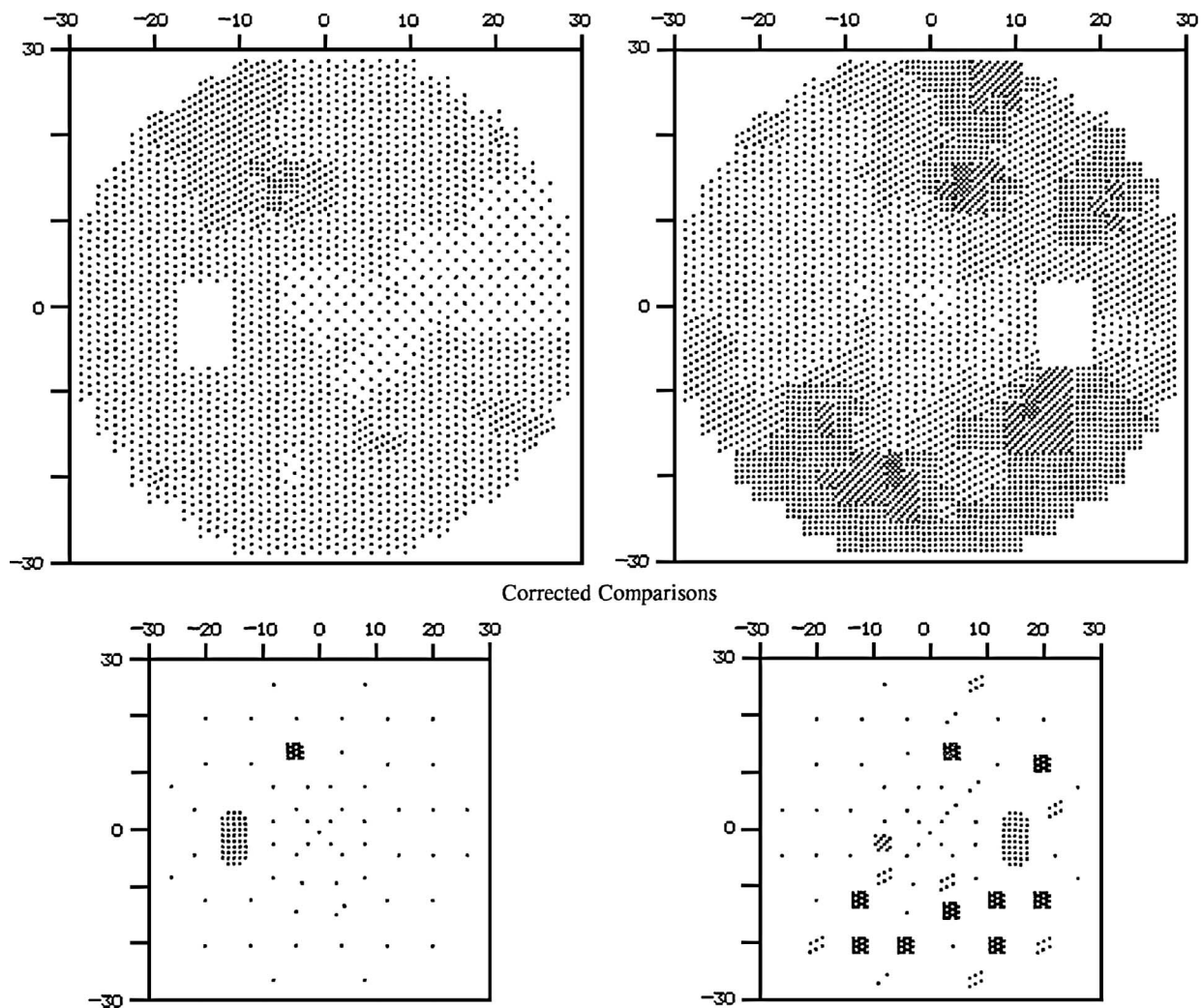


FIG. 2. Octopus perimetry shows a mostly inferior nerve fiber bundle defect in the right eye and no definite abnormalities in the left eye.

To our surprise, MRI revealed thickening and abnormal enhancement of the posterior intraorbital optic nerve sheaths bilaterally, extending into the optic canals, tuberculum sella, right anterior clinoid process, and planum sphenoidale (Fig. 1). Nonenhanced CT of the orbits revealed plaque-like calcifications along the optic nerve sheaths (Fig. 4). These imaging findings were consistent with a tuberculum sellae meningioma extending along the planum sphenoidale and into both orbits. The patient did not receive any treatment and is being followed closely for deterioration of vision.

Meningiomas that affect the optic nerve sheath meningiomas are bilateral in about 5% of patients (1).

In fact, bilateral involvement is so rare in meningiomas originating within the intraorbital sheath that it suggests an origin from the planum sphenoidale or tuberculum sella with secondary extension to the intraorbital optic nerve sheaths (2,3). What makes our patient unusual is that the presentation of unilateral visual loss was acute and associated with ipsilateral periocular pain. Such a presentation justifiably raised the suspicion of optic neuritis. MRI of the optic nerves revealed the bilateral abnormalities, which can sometimes be mimicked by inflammation. CT is helpful in distinguishing a meningioma from inflammation by showing calcification (4,5).

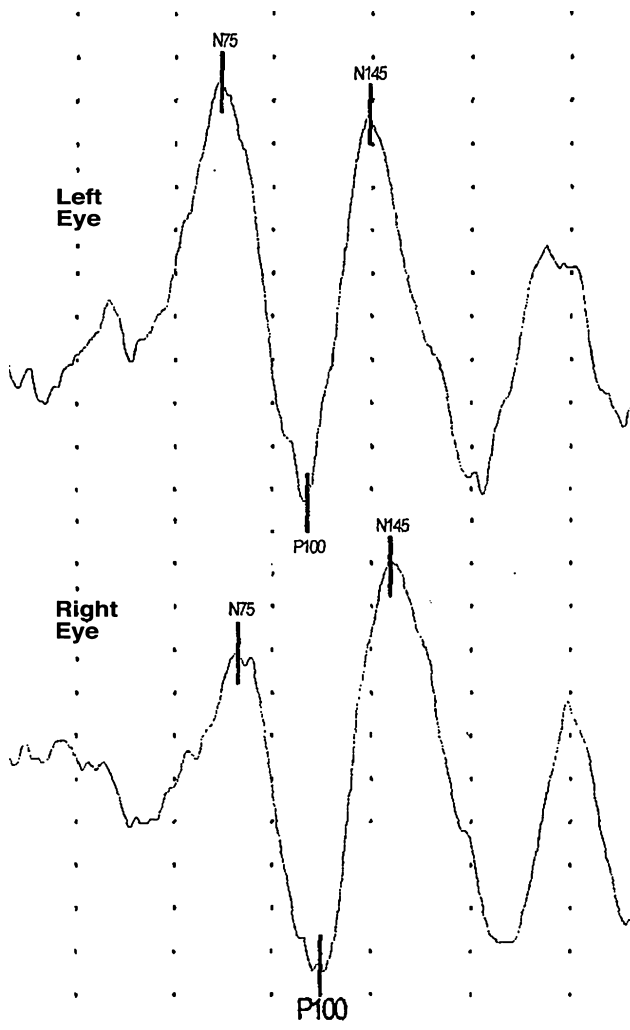


FIG. 3. Visual evoked potentials show prolonged P100 latencies in both eyes.

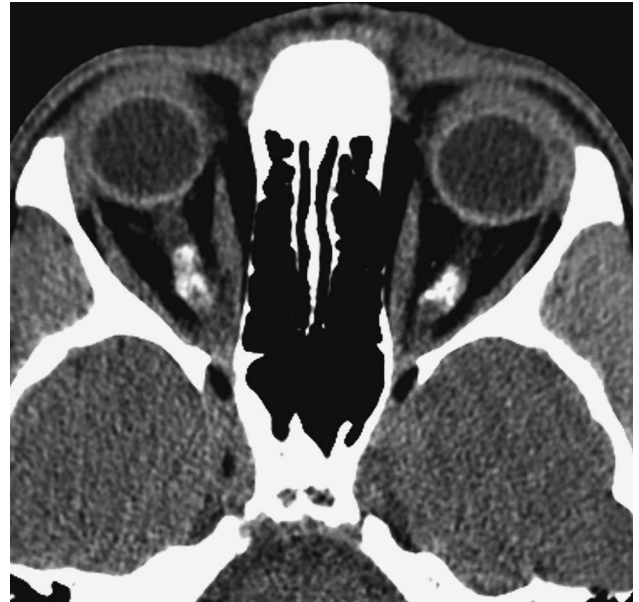

FIG. 4. Precontrast axial CT reveals thickening and calcification in the region of the orbital optic nerves bilaterally.

REFERENCES

1. Dutton JJ. Optic nerve sheath meningiomas. *Surv Ophthalmol* 1992; 37:167-83.
2. Lewis T, Kingsley D, Moseley I. Do bilateral optic nerve sheath meningiomas exist? *Br J Neurosurg* 1991;5:13-8.
3. Schick U, Hassler W. Surgical management of tuberculum sellae meningiomas: involvement of the optic canal and visual outcome. *J Neurol Neurosurg Psychiatry* 2005;76:977-83.
4. Lloyd GA. Primary orbital meningioma: a review of 41 patients investigated radiologically. *Clin Radiol* 1982;33:181-7.
5. Saeed P, Rootman J, Nugent RA, et al. Optic nerve sheath meningiomas. *Ophthalmology* 2003;110:2019-30.