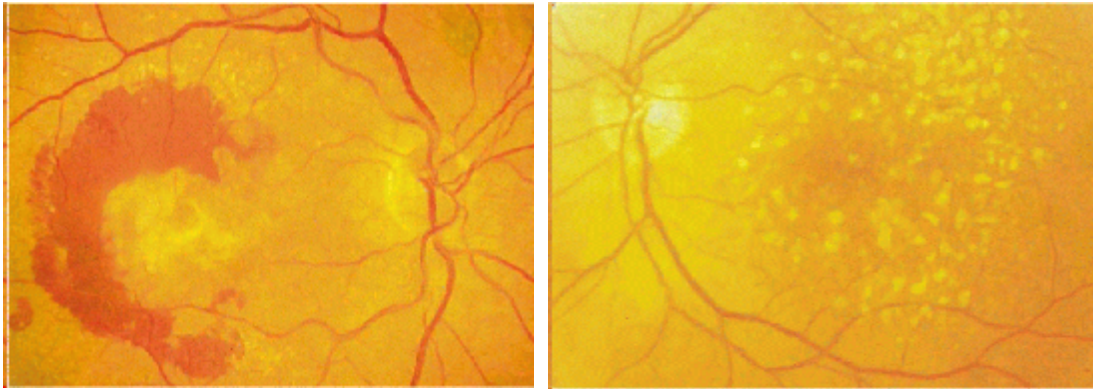


Macular Degeneration - Case Conference

Case 1 - A 72 year old woman has noticed distortion of her vision over the last month. Everything appears normal when only the left eye is opened. When the right eye is open straight lines appear to be bent in the middle.

1) What elements of the eye exam can be performed in the primary care setting to determine the cause of the visual loss?

The retinal exam of the right and left eyes are shown.



2) Describe the findings.

3) What is the diagnosis?

4) What do the findings represent at the histologic/microscopic level?

4) What additional testing can be performed to help decide management?

5) What are the management options and what are the goals of treatment?

Case 2 - A 72 year old man with a history of hypertension and heart disease related to smoking is noted to have increased blood pressure on exam today. On interviewing the patient you discover that he has discontinued taking his blood pressure medication. On further questioning, the embarrassed patient admits that he is unable to afford both the anti hypertensive you have prescribed and the vitamin pills for which he pays his eye doctor \$40/month. The patient has seen the terrible effect that macular degeneration has seen in his friends and says that he'd rather be dead than lose his sight.

1) How would you advise this patient?

2) What data exists regarding the role of smoking and macular degeneration?

3) What data exists regarding the role of nutrition and macular degeneration?