

Diabetes and the Eye - the Essentials

Diabetic Retinopathy is the leading cause of blindness in working age Americans. Appropriate referral and treatment reduces visual loss by 50%

Incidence of retinopathy is 23% in type I diabetics after 5 years and 80% after 15 years.

Etiology/Pathophysiology - Hyperglycemia leads to vascular endothelial dysfunction. Endothelial dysfunction leads to 1) leakage of blood or lipid into retina 2) capillary occlusion and ischemia of retina.

Stages

1) No retinopathy - retina appears normal, endothelial dysfunction can be detected using special techniques

2) Background retinopathy •microaneurysm

(MA) - tiny red dots, saccular outpouching of capillaries, these leak

•hemorrhages - evidence of leakage

--**dot** - tiny red dots difficult to tell from MA's in inner retinal layers

--**blot** - larger red splotches in inner retina

--**flame** - elongated hemorrhage in nerve fiber layer

3) Exudative retinopathy - leakage of plasma and lipid from MA's

•**hard exudates** - bright yellow dots with distinct borders, lipid deposits

•retinal thickening - accumulation of fluid in retinal layers

When these occur in the central retinal area or macula this is known as **macular edema**. When exudate or thickening occur close to the fovea the chance of visual loss is high and is called **clinically significant macular edema (CSME)**

4) Proliferative retinopathy (PPDR)

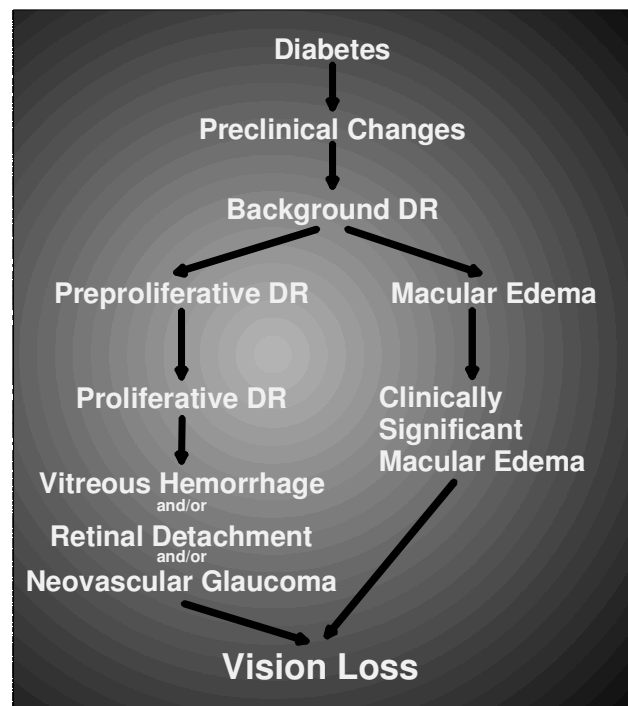
•cotton wool spots - retinal nerve fiber layer infarcts

•venous dilation and tortuosity

High risk for progression to proliferative retinopathy

5) **Proliferative retinopathy (PDR)** - as a response to ischemia, new blood vessels grow.

These blood vessels are fragile and grow into vitreous. Vitreous traction on these vessels can result in bleeding (vitreous hemorrhage) or detachment of the retina. Approximately 50% of patients with PDR progress to blindness in five years.



Screening and Treatment Guidelines			
Stage	Follow-Up	Laser	Comments
No diabetic retinopathy	12 month	no	all pts over 30 yo < 30 yo if had DM for 5 years or more Diabetic women should be examined prior to or in the first trimester of pregnancy. Gestational diabetics do not need screening.
Background Retinopathy	6-12 month	no	frequency dependent on severity
Macular Edema (not clinically significant)	4-6 month		
Clinically Significant Macular Edema	2-4 month	focal	
Preproliferative Retinopathy	4-6 month	no	will sometimes perform PRP if PPDR is severe or ability to follow-up is in question
Proliferative Retinopathy	2-4 months	PRP	

*follow-ups are dilated retinal exams with ophthalmologist

*focal - focal laser in macular area to seal microaneurysms

*PRP-panretinal photocoagulation to decrease angiogenic drive and cause regression of neovascularization

Other manifestations of DM in the eye

- 1) rapid changes in eyeglass prescription with blood sugar fluctuation causing acute blurry vision
- 2) cornea - dry eye, poor wound healing, contact lens intolerance
- 3) iris - poorly reactive pupils, light-near dissociation
- 4) lens - diabetics get cataracts earlier
- 5) glaucoma - slightly more likely to get open-angle glaucoma,
in severe DM neovascularization of the iris and angle can occur causing neovascular glaucoma
- 6) EOM deficits - can have spontaneous paresis of CN III,IV or VI due to microangiopathy