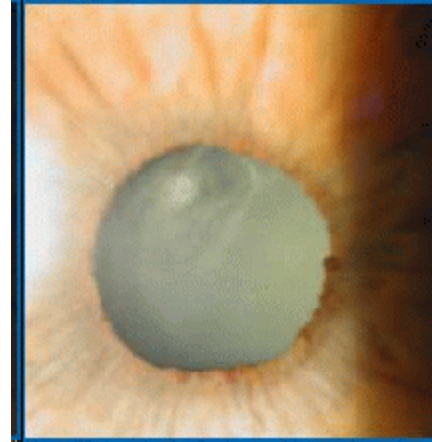


## Cataract Case Conference

**Case 1** - A 65 year old man complains of difficulty seeing street signs while driving and glare from headlights that interferes with driving. On exam, his visual acuity with his current glasses is 20/50 OD and 20/40 OS.

- 1) Describe the findings.
- 2) What is the diagnosis?
- 3) What other elements of the eye exam are important in deciding on management?
- 4) Further exam demonstrates that the vision is unimproved with a change in glasses prescription and that the remainder of the exam is normal. Discuss the medical and surgical management options. Be sure to compare the risks of further observation vs the risk of cataract surgery.



- 5) The patient asks for more detail on how cataract surgery is done and what he can expect during the surgery. In particular, he wants to know how the laser is used and how often he'll need to have his implant replaced. Also, how long will the eye be removed from the socket?

**Case 2** - A 72 year old man is brought in by his wife for a second opinion regarding cataracts. He had recently seen another doctor who told them that he needed to have his cataracts removed as soon as possible. The patient does not drive and has no complaint about his vision. His current medical history is significant for Alzheimer's disease, hypertension and diabetes.

On exam, his visual acuity with his current glasses is 20/50 OD and 20/40 OS. Vision is unimproved with a change in glasses prescription. Anterior segment exam show 2+ nuclear sclerotic cataracts. Examination of the retina reveals some changes consistent with dry macular degeneration.

- 1) Discuss the medical and surgical management options. Make sure to include the indications for cataract surgery. When is cataract surgery "needed as soon as possible?"
- 2) What is your advice to the patient and his wife?
- 3) Would this advice be different if the patient's vision was 20/400 in each eye and the wife noted that the patient was having trouble getting around the house?

**Case 3** - You are the acting intern on the neo-natal unit. As you are using the direct ophthalmoscope to examine a 1 day old baby girl you notice the finding below.

1) Describe the finding.

2) What is the possible diagnoses? Which is most likely?

3) Assuming that this represents a unilateral cataract what are the management options? What are the indications for cataract surgery?

