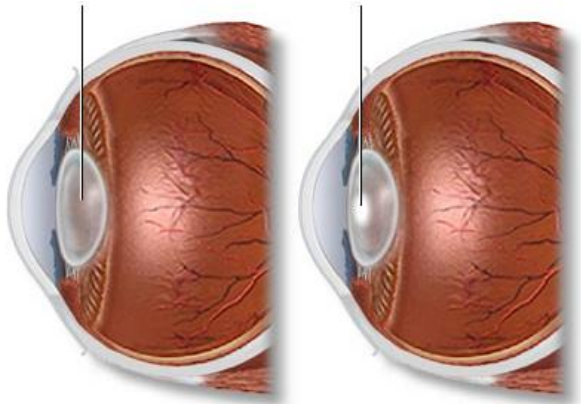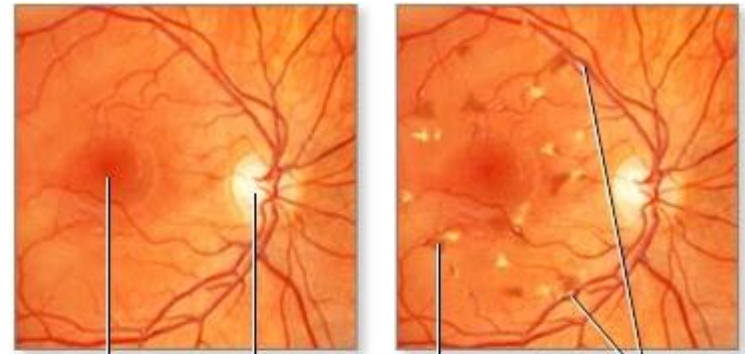


ADAM.



Macula    Optic disk    Hemorrhage    Aneurysms

