

Blepharoptosis

Ana Rosa Pimentel de Figueiredo

*Oculoplastics Department, Hospital São Geraldo, Federal University of Minas Gerais,
Belo Horizonte, Minas Gerais, Brazil*

ABSTRACT

Blepharoptosis is the downward displacement of the upper eyelid secondary to structural abnormalities (muscle or aponeurosis) or neurologic problems. It is a frequent condition and its clinical picture varies from a cosmetic discomfort to severe visual dysfunction, depending on the pathogenesis and the degree of ptosis. The diagnosis of ptosis is complex and goes beyond simple clinical examination. Ptosis surgery is perhaps the most challenging in the field of oculoplastics, especially in congenital cases and neuromuscular disorders. This paper discusses some concepts in blepharoptosis with emphasis on diagnosis and surgical principles.

KEYWORDS: blepharoptosis; ptosis; diagnosis; treatment; review

INTRODUCTION

Blepharoptosis is the downward displacement of the upper eyelid secondary to structural abnormalities (muscle or aponeurosis) or neurologic problems. It is a frequent condition among oculoplastic patients and its clinical picture varies from a cosmetic discomfort to severe visual dysfunction, depending on the pathogenesis and the degree of ptosis. The diagnosis of ptosis is complex and goes beyond the simple clinical examination. The appropriate selection of the treatment depends on the semiology. Ptosis surgery is perhaps the most challenging in the field of oculoplastics, especially in congenital cases and neuromuscular disorders.

CLASSIFICATION

Several classifications have been proposed, usually based on time of onset, dividing ptosis in two groups: congenital and acquired.^{1,2,3} In the 1980s, some authors described new classifications based on the pathophysiology of the disease, largely dictated by the role of the levator aponeurosis in the development of ptosis.^{4,5,6,7} In our practice we have adopted a combination of these classifications based on the time of onset but relating it to pathophysiology and etiology. This approach can help in planning the treatment and pre-

dicting prognosis and possible negative outcomes that could compromise the doctor-patient relationship.

Congenital Ptosis

Congenital ptosis is present at birth and usually recognized by the parents or pediatrician during the first weeks of life. It should not be mistaken with late-onset hereditary ptosis.

Myogenic Ptosis

Myogenic ptosis is caused by a levator muscle dysgenesis.^{5,8,9} Some authors theorize that it is a localized muscle dystrophy, but in most cases of congenital ptosis there is no hereditary pattern.¹⁰ Myogenic ptosis, isolated or associated to other defects, presents with a levator muscle that has a weak contraction and does not relax well. The clinical picture shows ptosis, lid lag at down gaze, weak levator function, and absent or indistinguishable lid fold (Figures 1 and 2).

Pure congenital ptosis is usually unilateral with no associated ocular motility or facial defects. It is mostly sporadic, but a few cases have an autosomal dominant inheritance (Figure 3). It is the most frequent form among congenital ptosis.

Congenital ptosis associated with superior rectus dysfunction (double elevator palsy) occurs in a small percentage of cases. There is a deficiency in eye elevation secondary to malformation of the superior rectus (Figure 4). It is important to recognize this association because in such cases surgery should aim for hypercorrection. Recently, there were a few reports of

Correspondence: Ana Rosa Pimentel de Figueiredo, Oculoplastics Department, Hospital São Geraldo, Federal University of Minas Gerais, Belo Horizonte, Minas Gerais, Brazil. E-mail: anarpimentel@globocom

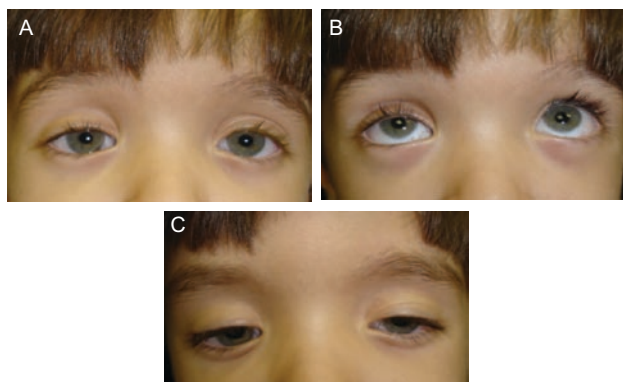


FIGURE 1 Congenital myogenic ptosis.

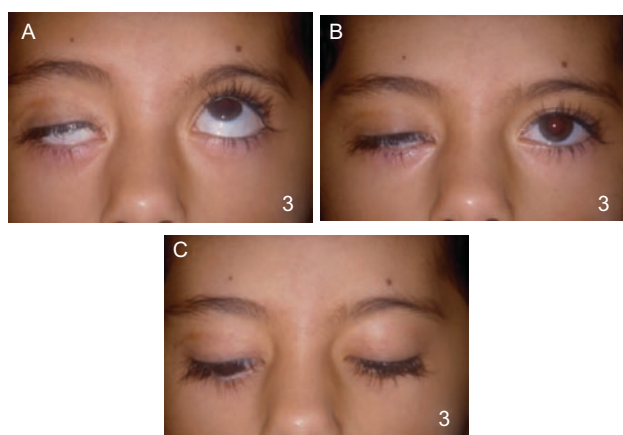

FIGURE 2 Congenital ptosis (courtesy of Alfredo Bonfioli, MD).




FIGURE 3 Congenital ptosis with positive familial history.

congenital ptosis associated with superior rectus hyperfunction (Figure 5).^{11,12}

Congenital ptosis associated with fibrosis of the extraocular muscles is a rare hereditary disorder.¹³ There is severe bilateral restriction of ocular motility and the eyes are practically frozen in a downward position. The Bell phenomenon is absent and the patient compensates by elevating the chin. Fibrosis of the extraocular muscles is related to abnormalities in the development of the III, IV and VI nerve nucleus.^{14,15} It would be better classified with the neurogenic ptosis because the final muscle changes result from paresis. High-resolution magnetic resonance imaging shows structural changes at the extraocular muscles and nerves.¹⁶

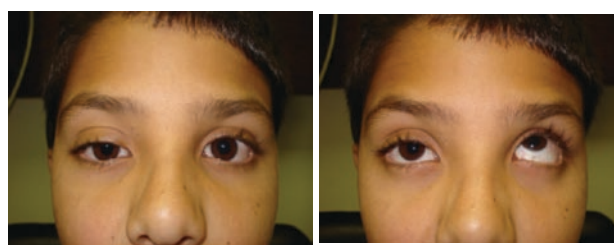

FIGURE 4 Congenital ptosis with superior rectus hypofunction.

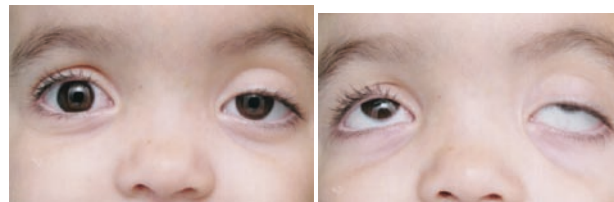

FIGURE 5 Congenital ptosis with superior rectus hyperfunction.

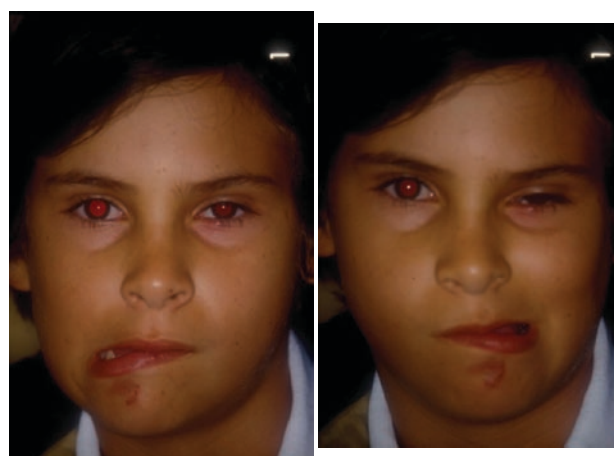

FIGURE 6 Ptosis associated with Marcus Gunn phenomenon (courtesy of Alfredo Bonfioli, MD).

Ptosis associated with Marcus Gunn phenomenon (jaw-winking syndrome) is sporadic and unilateral (Figure 6). There are multiple aberrant retractions of the eyelid following jaw movements because of a connection between the third nerve and fifth nerve fibers for the mastication muscles. The treatment is difficult because there is no solution for the synkinesis. The surgery consists of completely sectioning the levator and performing an eyebrow suspension. The anomalous movements tend to decrease after puberty, which usually leads the family to opt for the correction of the ptosis alone. On the other hand, when the retraction is very pronounced and triggered by minimum movements like speaking and smiling, the condition may cause important psychological problems.

Blepharophimosis syndrome has most frequently autosomal dominant inheritance. The clinical picture includes severe bilateral ptosis, usually symmetric,

epicanthus inversus, and telecanthus. There may be a reduction of the palpebral fissure, ectropion of the lateral half of the lower lid, elongation of the inferior canaliculus and lateralization of the inferior punctum, hypoplasia of the superolateral orbital margin, and flattening of the nasal bridge and glabella.

Ptosis occurs in association with other craniofacial malformations such as Turner syndrome, Noonan syndrome, Rubenstein-Taybi, and Saethre-Chotzen syndromes. These are rare conditions that will not be discussed in this article. It is important to point out that, independent of other malformations, the visual impact of the ptosis should not be overlooked in children and treatment should not be delayed. The nature of this ptosis is mostly myogenic and surgical planning should consider the degree of ptosis and levator function, as well as associated orbital and periorbital abnormalities.¹⁷

Other Congenital Ptosis

Other forms of congenital ptosis have been described. Dystocia, with the use of forceps or not, may damage the aponeurosis.¹⁸ Congenital paralysis of the third nerve may also result from labor but is usually associated with other congenital neurological disorders, and aberrant regeneration is frequent (Figure 7). Third nerve palsy in a newborn may be a sign of a compressive mass and the evolution should be watched closely.¹⁹ The transmission of antibodies from a mother with myasthenia gravis may cause short-term ptosis in the newborn. Congenital Horner syndrome may result from labor trauma with

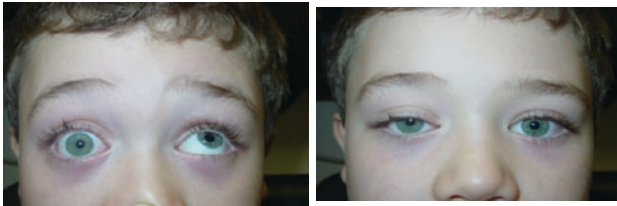


FIGURE 7 Aberrant regeneration.

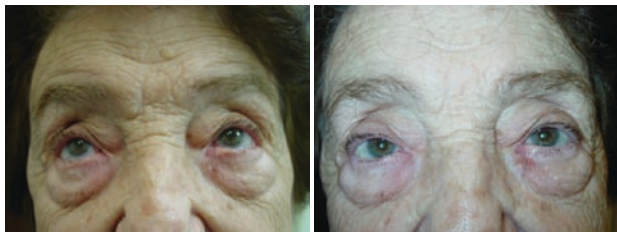
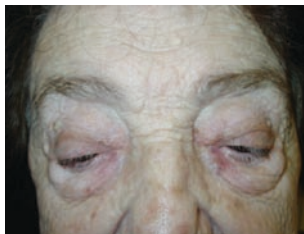

FIGURE 8 Involutional ptosis.



brachial plexus injury, congenital tumors related to the sympathetic chain, or malformations of the internal carotid artery. Although rare, these conditions should be part of the differential.

Acquired Ptosis

Acquired ptosis is by definition any ptosis that appeared after birth. The diagnosis requires careful examination, attention to the clinical history, and the analysis of old photographs. The age of onset is an important clue to the diagnosis since it indicates the most probable pathophysiological mechanism.

Aponeurotic Ptosis

Aponeurotic ptosis is caused by a defect at the levator aponeurosis, the muscle itself being normal. The levator function is therefore preserved even in severe cases. The aponeurosis may be deinserted from the tarsus or attenuated and infiltrated by fat tissue. The lid crease is typically high, there is deepening of the upper sulcus, elevation of the eyebrow, and compensating frontal muscle contraction. Because the connections between the aponeurosis and the tarsus are weak, the lid descends more on down gaze, practically covering the entire cornea.

Aponeurotic ptosis is more frequent at old age (involutional mechanism; Figure 8) but it is also recognized in younger patients with a history of recurrent eyelid edema (Figure 9) or trauma, including contact lens wear (Figure 10). Some patients report a sudden appearance of the ptosis. Analysis of old photographs shows that most individuals had at least subtle asymmetry of the lid crease or eyebrow prior to the diagnosis. Ptosis after intraocular surgery seems to follow this principle and occur in predisposed patients independent of the type of anesthesia or suture (Figure 11). Although more frequently related to cataract surgery,

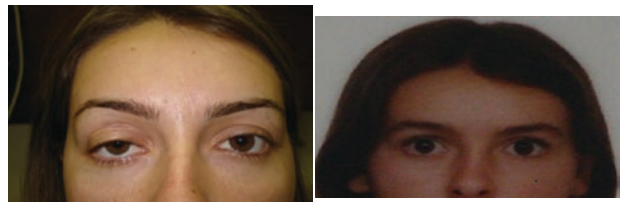


FIGURE 9 Ptosis secondary to recurrent eyelid edema. (A) 19 years old (B) 12 years old.

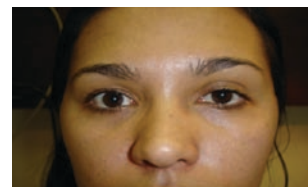

FIGURE 10 Ptosis secondary to contact lens wear.

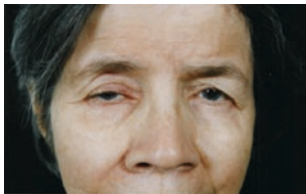

FIGURE 11 Ptosis following cataract surgery.

post operative ptosis may occur in young patients following refractive surgery²² or after subtenonian injection of triamcinolone.²³ The proposed mechanism is attenuation or desinsertion of the aponeurosis in anatomically predisposed individuals.

The recognition of the aponeurotic mechanism is relatively recent^{7,18,24} and it changed the diagnosis of acquired ptosis in young patients with typical aponeurotic ptosis that were submitted to extensive and invasive investigation to rule out neurological and myogenic etiology.^{6,25,26,27}

Myogenic Ptosis

Myasthenia gravis is an autoimmune disease in which antibodies act against acetylcholine receptors at the neural plate preventing neurotransmission. The disease usually begins with unilateral or bilateral asymmetric ptosis and diplopia. The presentation can remain localized in a few cases or progressively involve other skeletal muscles. The main characteristic of myasthenia is muscle fatigue. Ptosis severity fluctuates during the day and depending on activity of the disease. The examination of young patients with acquired ptosis should always include fatigue testing, like asking the patient to look up and down several times or to sustain the up gaze for some time.²⁵ In myasthenia patients the degree of ptosis increases and lid fasciculation is frequently observed during prolonged up gaze. The Cogan's lid twitch is the palpebral retraction observed after prolonged down gaze. Recently, the ice test was introduced as an option to therapeutic tests and has been considered a simple, sensitive, and specific diagnostic tool.^{28,29,30} It consists of applying an ice pack over the eyelids for 5 minutes. Myasthenic ptosis will practically disappear. It is also useful to diagnose myasthenic diplopia.³¹ Cooling acts at the neuromuscular junction, reducing cholinesterase activity and improving acetylcholine efficiency.³⁰ Approximately 90% of myasthenia cases are detected by the ice test and referred to appropriate neurological evaluation. Treatment of myasthenic ptosis is clinical but some patients have an aponeurotic component that may benefit from surgery. Severe cases, refractive to clinical treatment, are also candidates for surgery.²⁵ It is important to point out the frequent association between Graves's orbitopathy and Myasthenia gravis. In these cases, instead of palpebral retraction, Grave's patients may present with ptosis, caused by the myasthenia.

Myopathies are degenerative diseases, usually hereditary, that affect the levator muscle. The ptosis can occur isolated or in association with systemic involvement. Myopathy suspects should be evaluated by a neuromuscular specialist. The electromyography often shows a myopathic pattern with no conduction defect. Muscle biopsy with immunohistochemistry defines the diagnosis in most cases. The orbicularis muscle may be used for the biopsy, but the most common sites are biceps and lateral thigh.³²

Muscle dystrophies associated with ptosis include oculopharyngeal dystrophy and Steinert's myotonic dystrophy. Oculopharyngeal dystrophy has autosomal dominant inheritance and begins in the fifth and sixth decades of life with slowly progressive bilateral ptosis, dysphagia, dysarthria, and mild proximal weakness. The involvement of extrinsic ocular muscles is variable. It should be differentiated from mitochondrial myopathies. Steinert's myotonic dystrophy has autosomal dominant inheritance with variable penetrance, and can present at any age, from the neonatal period to adulthood. Findings include slow and progressive weakness of facial muscles and the sternocleidomastoid, bilateral symmetric ptosis, and frontal baldness. Cataract is frequent. Characteristic signs are weakness of hand muscles, drooping foot and myotonic phenomenon, which can be observed during the percussion of the thenar muscles. Cardiomyopathy and cardiac block are common and can lead to sudden death. Other findings are hypogonadism, insulin resistance, drowsiness, nausea, and vomiting.

Mitochondrial myopathies associated with ptosis are chronic progressive external ophthalmoplegia and Kearns-Sayre syndrome (Figure 12). Chronic progressive external ophthalmoplegia is a localized myopathy manifested by progressive ptosis and ophthalmoplegia. It is hereditary in half of all cases and symptoms begin in childhood. Weakness of the orbicularis is observed. Kearns-Sayre syndrome is Kearns-Sayre syndrome is a systemic disease that affects young patients causing ptosis and ophthalmoplegia, retinitis pigmentosa, cerebellar ataxia, cardiac conduction block and an increase in cerebrospinal fluid proteins. These patients may have short stature, hypoparathyroidism, diabetes, and nephropathy.

Neurogenic Ptosis

Ptosis associated with third nerve palsy may result from peripheral, nuclear or supranuclear lesions. The classic presentation is severe ptosis, incomitant exotropia, and mydriasis (Figure 13). Most often, paralysis is the result of micro vascular damage in the subarachnoid space or the cavernous sinus. The prevalence is high in diabetes mellitus patients and the signs tend to start recovering spontaneously within weeks. Other causes of third nerve palsy include compression (aneurysm or tumor), inflammation (vasculitis and sarcoidosis), infections (meningitis), tumor infiltration of the nerve, and trauma. The degree of

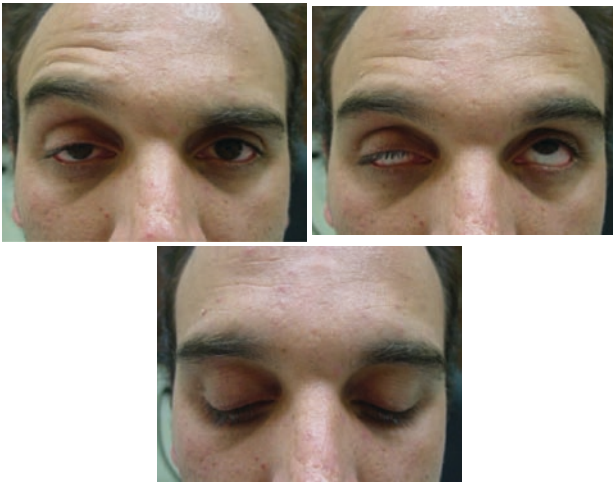


FIGURE 12 Kearns-Sayre syndrome.

involvement of the pupil has great importance in defining the cause. The presence of fixed mydriasis suggests nerve compression and requires immediate neurological examination. Even in cases in which the pupil is spared, it is prudent to reexamine the patient periodically to detect the onset or progression of the pupil defect. Acute third nerve paralysis, without pupil involvement, after the fourth decade, suggests a vascular cause and diabetes and hypertension should be excluded. Moreover, persistence of paralysis signs after 3 months requires neurological examination to discard tumors or infiltrative lesions at the cranial base and cavernous sinus. The occurrence of third nerve paralysis in children is usually transitory, due to viral infection or vaccination, but the persistence of signs, especially with involvement of the pupil, asks for neurological investigation to exclude an aneurysm or other structural etiology. Ophthalmoplegic migraine, also common in children, begins with a headache and progresses with third nerve dysfunction a few days after the onset of pain.¹⁹ It has spontaneous resolution. Surgical correction of the ptosis should only be proposed after the recovery of third nerve function and stability for a few months. Strabismus surgery should be done before or even in the same procedure.

Aberrant regeneration of the third nerve is especially common after traumatic lesions and may be occasionally associated with slowly progressive tumor compression, but it does not occur due to diabetes. Primary regeneration, without previous third nerve lesion, occurs with expansive parasellar lesions (meningioma or intracavernous aneurysm).³³ The classic picture is palpebral retraction during adduction and depression of the eye.

Horner syndrome is secondary to lesions anywhere in the oculosympathetic pathway. It is characterized by miosis with normal papillary reflexes, mild ptosis and lower lid elevation, anhidrosis and skin pallor of the face ipsilateral to the lesion. Anhidrosis and pallor may be absent in postganglionic defects (Figure 14).

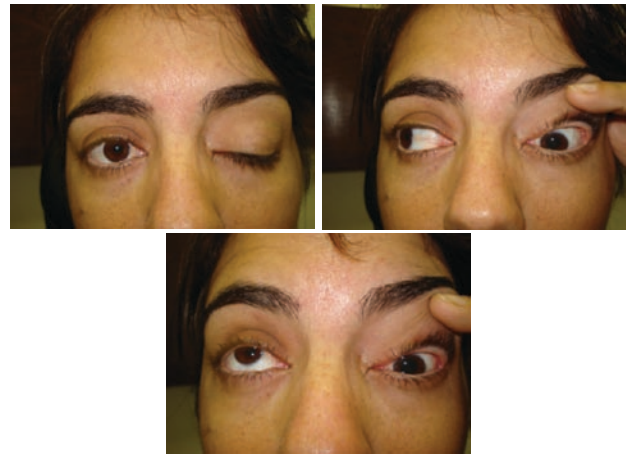


FIGURE 13 Ptosis associated with third nerve palsy.

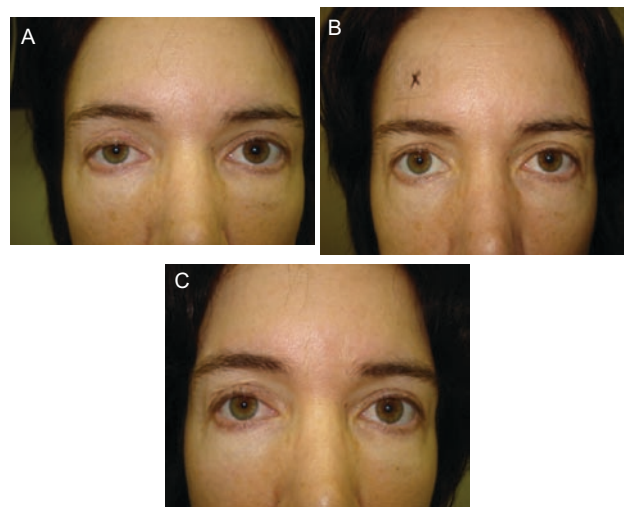


FIGURE 14 Horner syndrome. (A) Miosis and Heterochromia; (B) Phenylephrine test; (C) post operative result.

There is an enophthalmic appearance, not confirmed by exophthalmometry, secondary to a reduction of Muller muscle tonus. Heterochromia, characterized by a lighter iris ipsilateral to the lesion, is a classic sign of congenital Horner syndrome and may also be seen in acquired cases.³⁴ Oculosympathetic lesions may be pre or postganglionic. The preganglionic defects are located at the first neuron, occurring after high cervical lesions, or the second neuron, following thoracic lesions. Postganglionic defects are located at the third neuron and are caused by internal carotid or cavernous sinus. Pharmacological testing used for diagnosis of Horner syndrome and localization of the lesion consist of 10% cocaine and 1% hydroxyamphetamine drops. 2.5% or 10% phenylephrine hydrochloride will cause, at the affected side, an elevation of the ptotic eyelid and pupil dilation if there is a preganglionic lesion.

Mechanical Ptosis

Mechanical ptosis is determined by a reduction at the margin-reflex distance secondary to a lesion causing

a gravitational effect at the eyelid or to conjunctival scars that traction the palpebral margin downwards. The ptosis will completely disappear if the cause is removed. It is important to note that, depending on the duration of the mechanical effect and patient's age, it can lead to associated aponeurotic damage that will need correction.

Pseudoptosis

Pseudoptosis should be differentiated from true ptosis. The normal eyelid maintains its relationship with the globe and vertical strabismus or any change in the eye position may result in a ptotic appearance with no true ptosis. The diagnosis of ocular hypotropia is made using cover-test. When the dominant eye is occluded and the deviated eye assumes fixation, the ptosis disappears. There may be an aspect of ptosis with contralateral upper lid retraction, explained by the simultaneous innervation phenomenon. When occluding the eye with the lid retraction, the ptosis will disappear. Anophthalmic cavity may be associated with pseudoptosis caused by the lack of eyelid support. The appearance can be improved by an adequate prosthesis, but if there is an associated aponeurotic defect, which is frequent, surgical correction is indicated.

Traumatic Ptosis

The term traumatic ptosis has been used in some classifications but is considered inadequate. The etiology is trauma (penetrating or blunt) but the resulting ptosis may be mechanical, neurogenic, muscular, or aponeurotic (Figure 15). The pathophysiological mechanism should be identified. In general, definite treatment should be postponed until maximum spontaneous recovery is reached. The surgery should then explore and reconstruct all the structural damage as best as possible. If there is complete lesion of the levator muscle, frontal suspension is indicated.

PATIENT EVALUATION

History

The history should be directed according to the type of ptosis. Patients and family members do not always value systemic signs and symptoms and will not provide the necessary information unless specifically asked. The main aspects of the history are: time of onset, progression pattern, associated congenital defects or neuromuscular signs and symptoms, previous treatments and their results, birth history, and the presence of other cases in the family. During the interview the examiner should be attentive to compensating movements such as head position and frontal muscle contraction, aberrant movements or even artifices used by the patient to try to hide the

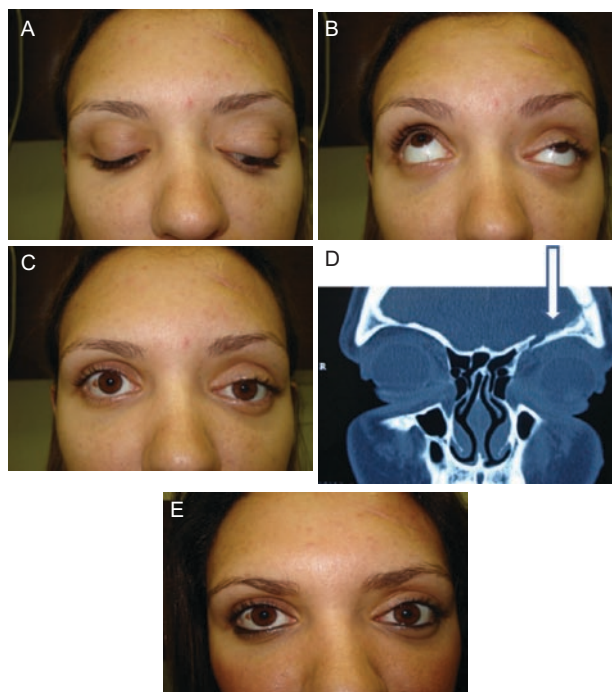


FIGURE 15 Traumatic ptosis- orbital roof fracture and levator muscle damage. (A,B,C) Ptosis. (D) CT scan showing the orbital roof fracture; (E) Post operative result.

defect (cover the eyes with the hair or constantly move the hand in front of the face). Collecting information is key to diagnosis, treatment definition, and prognosis in ptosis cases. Analysis of old photography is also essential, especially to define the time of onset.

Physical

To examine the ptosis and levator function, the patient should sit in front of the examiner, at the same height. A ruler and a light are all that is needed for the measurements. Younger children are usually not cooperative, but the examiner should try to get the best measurements possible.

Ptosis Severity

In order to get precise information about the eyelid position, the examiner should eliminate all frontal contraction or record the fact that it was not possible to do so. The upper lid in its normal position covers 2mm of the cornea. The palpebral fissure is measured at its highest point, slightly nasal to the pupil; the normal value is approximately 10mm (Figure 16). Following the contour of the lid, paracentral measurements are 7mm at a lateral point and 5mm at a medial point. The canalicular portions of the lid should be separated from each other and the caruncle and semilunar fold should be exposed.

The vertical opening of the eyelid is not considered a valid parameter if there is malposition of the lower lid. To

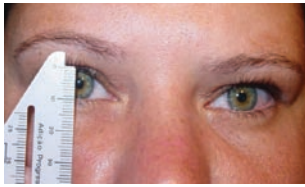


FIGURE 16 Palpebral fissure measurement.

adjust for this error the margin-reflex distance (MRD1) should be obtained. MRD1 is the distance between the upper lid margin and the corneal reflex when the patient is fixating the light source. The normal value is around 4mm. It is mandatory that the eye is fixating during the test. The MRD1 is the most important measurement in clinical practice to determine if there is ptosis, the degree, and bilateralism. Severe cases, in which the margin obscures the corneal reflex, register negative values or simply zero. Less important is the measuring of the distance between the lower lid margin and the corneal reflex (MRD2). The scleral show is more prominent at the lateral portion of the eyelid and paracentral measurements are considered more reliable to define the contour. The concept of multiple measurements for ptosis has been widely adopted and needs to be pointed out to younger oculoplastic surgeons. The use of a schematic drawing to register the values is very useful.

Levator Muscle Function

Levator muscle function is the most important isolated factor for ptosis surgery planning. It is determined by the excursion of the upper lid from down gaze to up gaze (Figure 17), without the contribution of the frontal muscle. The examiner should keep moderate pressure above the eyebrows to eliminate this factor. Normal excursion has values greater than 15 mm.

In children and patients with mental disorders levator function is difficult to assess. It is possible to estimate the excursion by watching the patient from a distance and observing eye and lid elevation, frontal contraction, lid crease position. Patients with excessive frontal contraction and discreet or absent lid crease have poor levator function.

Eyelid Crease and Superior Sulcus

The eyelid crease is the superficial expression of the levator function, since it is formed by connections between the aponeurosis and the skin, passing through the orbicularis. The orbital septum fuses with the aponeurosis at the level of the crease and between them is located the preaponeurotic fat. From the anatomy of this fusion results the crease height and the lid fat distribution. The crease is located at approximately 10 mm of height in men and 8 mm in women. Individuals of Asian descent have a much lower crease, usually obscured by a fold of skin and fat. The connections

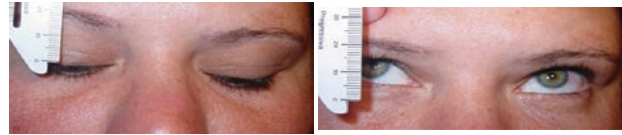

FIGURE 17 Levator muscle function assessment.

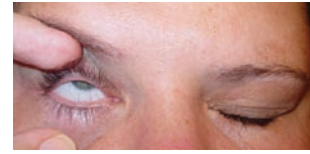

FIGURE 18 Bell's phenomenon assessment.

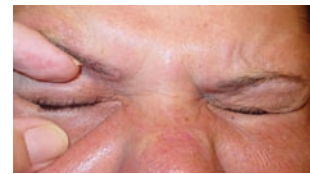

FIGURE 19 Orbicularis tonus assessment.

between the aponeurosis and the orbital septum may be wider, leaving no room for preaponeurotic fat and resulting in a continuous appearance between pretarsal and preseptal portions, undistinguishable crease and deep superior sulcus. It is important to determine these constitutional aspects using old photographs.

Eyelid Position at Down Gaze

With the eyes in the primary position, eyelid tonus positions the lid 1 or 2mm below the superior limbus. The upper lid follows gaze movements and at down gaze the same relationship should persist. The analysis of the position of the ptotic lid at down gaze is extremely important to determine the pathophysiological mechanisms involved. In myogenic congenital ptosis the levator is a fibrotic muscle, unable to contract or relax properly. The eyelid is almost frozen at down gaze, leaving the superior cornea, and sometimes the sclera, exposed. In aponeurotic ptosis the upper margin tend to touch the lower lid at down gaze, and keeping the visual axis free requires great effort.

Other Tests

Further examination should include ocular motility testing, pupils, Bell's phenomenon (Figure 18), orbicularis tone (Figure 19), aberrant lid movements, presence of scars and masses (Figure 20), slit lamp exam, and tear production measurement, if necessary. Especially in children, a complete ophthalmological exam is mandatory, recording the cycloplegic refraction. Even if there is no amblyopia, myogenic ptoses are associated to astigmatism and anisometry. Visual field testing may be used to record the functional defect caused by the ptosis.

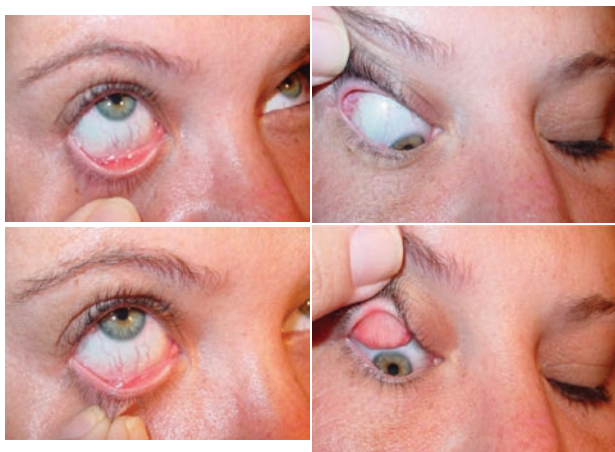

FIGURE 20 Conjunctival assessment.

Pharmacological Tests

The use of 10% phenylephrine for Horner's syndrome was described above. The same test has been used for aponeurotic ptosis and it is especially useful in supposedly unilateral cases. After 10 minutes of a drop of phenylephrine the correction of the ptosis is observed. If there is contralateral ptosis that was previously compensated by the simultaneous innervation phenomenon, it will be clearly demonstrated after the correction of the most ptotic side. There have been no reported systemic adverse events with the use of 10% phenylephrine drops.

Ice Test

The ice test is extremely useful to diagnose Myasthenia gravis ptosis and select the patients that should be referred to neurological testing.³³

Photographic Documentation

Photographic documentation is mandatory for all surgical cases, at least in primary eye position. If there is compensatory head position or aberrant movements, it is advised that they are photographed as well.

SURGICAL INDICATION AND TECHNIQUE SELECTION

The success of any surgery depends on the correct diagnosis and identification of the mechanisms involved in the pathophysiology of the disease. The technique of choice should be able to correct these factors with the smallest possible risk of complications. The function of the levator muscle is the single most important factor to consider when selecting the procedure and it is strongly related to the surgery outcome.

General anesthesia is recommended for children and some less cooperative patients. In most other cases the surgery may be performed under local anesthesia with light sedation, allowing the patient to respond to the

surgeon when necessary. Subcutaneous infiltration of a low volume of anesthetics with epinephrine is superior to nerve blocks in ptosis surgery because it preserves orbicularis function during the procedure. Even under general anesthesia, local infiltration is advised to improve hemostasis and reduce postoperative discomfort.

Levator Aponeurosis Surgery

Levator aponeurosis surgery is the procedure of choice if there is good levator function (above 4 to 5 mm eyelid excursion). Surgical techniques surgeries include aponeurosis advancement with resection or reinsertion.

Levator Aponeurosis Resection

This technique is used in myogenic ptosis with at least some levator function, even if it is only weakly active below the orbital margin. The aponeurosis is resected with or without the subjacent Muller muscle. The extent of the resection depends on the degree of ptosis and the function of the levator muscle. Ptosis is classified, based on the degree, as mild (2 mm or less), moderate (3 mm) or severe (4 mm or more). Levator function can be good (8 to 12 mm), fair (5 to 7 mm), poor (4 mm or less), or absent.

The resection is planned preoperatively according to classic guidelines (1,2,5,8): (a) moderate ptosis with good levator excursion – 14 to 17 mm resection without incision of aponeurosis expansions; (b) moderate ptosis with excursion between 5 and 7 mm – resection of 18 to 22 mm associated with incision of medial and lateral aponeurosis expansions; (c) moderate ptosis with poor levator function – maximum aponeurosis resection of 23 to 26 mm; (d) severe ptosis with excursion between 5 to 7 mm – maximum aponeurosis resection of 23 to 26 mm; (e) severe ptosis with poor levator function – supermaximal resection of 27 to 30 mm may be performed but eyebrow suspension is an option (see Table 1).

These are general rules, especially useful for the less experienced surgeon, but may be subject to adjustments according to personal experience. It is important to remember that the larger the resection the more pronounced the post-operative lagophthalmos and the lid retraction on down gaze will be.

Depending on the amount of levator aponeurosis advancement, it may be necessary to section, to a variable extent, the lateral and medial expansions of the aponeurosis. This allows the shortening of the levator aponeurosis without the imprisonment of the eyelid. For moderate resections, a conservative weakening of these extensions is indicated. For resections of 20 mm or larger, it is necessary to completely release the expansions until the Whitnall ligament and traction the levator muscle to obtain the maximum effect without complications related to lid closure. During this proce-

TABLE 1 Guidelines for levator aponeurosis resection

Ptosis	Levator function	Resection	Incision of aponeurosis expansions
Moderate (3mm)	Good (8 to 12mm)	Moderate (14 to 17mm)	No
Moderate (3mm)	Fair (5 to 7mm)	Large (18 to 22mm)	Yes
Moderate (3mm)	Poor (4mm or less)	Maximum (23 to 26mm)	Yes
Severe (4mm or more)	Fair (5 to 7mm)	Maximum (23 to 26mm)	Yes
Severe (4mm or more)	Poor (4mm or less)	Supermaximal (27 to 30mm)	Yes

dures, any damage to superior oblique muscle and lacrimal gland should be avoided. Maximum resections (25 to 30 mm) require extensive dissection until the upper fornix, which may result in conjunctival prolapse and exteriorization under the upper margin.

Aponeurosis resection may be performed through anterior (transcutaneous) or posterior (transconjunctival) approaches. The transcutaneous approach is indicated for larger resections when it is necessary to remove excessive skin and fat.

Anterior (Transcutaneous) Approach

The skin incision is placed at the eyelid crease (Figure 21A) or, when it is undistinguishable, approximately 7 mm above the margin. In unilateral ptosis the height of the crease on the normal side should be measured to achieve better symmetry. A mark is drawn at the skin, slightly medial to the papillary axis, and corresponding to the highest curvature point of the lid margin. A traction suture using 4-0 silk is placed at the margin at the plane of the previous mark. The skin is incised and the orbicularis dissected with blunt scissors towards the tarsus (Figure 21B). The tissue above the tarsal plate contains the fibrotic aponeurosis extensions to the skin and it is firmly attached to orbicularis. The dissection to expose the anterior surface of the tarsus should preserve this tissue and its attachments to the orbicularis, as it will be reconnected with the aponeurosis in the end of the surgery.

Superior dissection carefully exposes the anterior surface of the aponeurosis and the Whitnall ligament (Figure 21C). During this process, it is necessary to open the orbital septum and expose the preaponeurotic fat. These fat pockets are important anatomical landmarks for the levator aponeurosis.

The dissection of the upper lid retractors (aponeurosis and Muller muscle) begins at the upper margin of the tarsus, separating them from the subjacent conjunctiva (Figure 21D, E, F). The exposed conjunctiva should appear transparent and without any vascularized tissue (Muller muscle). A specialized clamp, such as the Berke's clamp, should be used to secure the lower end of the retractor and facilitate posterior dissection. With the clamp still in place, the retractor should be reattached to the tarsus using 6-0 double-armed sutures. The first stitch is placed at the curvature's highest point, passing the needle horizontally through the tarsus without transfixing it (Figure 21G). The distance between the two arms of the suture should be

approximately 3 mm. The needles are passed through the retractors at the desired height and tightened (Figure 21H). A temporary knot allows the surgeon to evaluate the position of the lid and make the necessary adjustments (Figure 21I). Two other sutures are placed medially and laterally to the first and adjusted to achieve a regular eyelid contour (Figure 21J). After tying the sutures, the distal portions of the aponeurosis and Muller muscle are sectioned (Figure 21K). To redefine the lid crease three or four 6-0 absorbable sutures are passed from the pretarsal orbicularis to the anterior surface of the aponeurosis, approximately 2 mm above the previous stitches. Excessive skin is excised, if necessary, and the incision is closed using 6-0 non absorbable sutures (Figure 21L). Traction using 4-0 silk should be kept for 24 to 48 hours in order to protect the cornea. The sutures are removed after 5 days.

Posterior or Transconjunctival Approach

A mark is drawn at the skin corresponding to the highest curvature point of the lid margin. A traction suture using 4-0 silk is placed at the margin so that the lid can be everted over a Desmarres retractor (Figure 22A). Conjunctiva and Muller muscle are incised at the upper margin of the tarsus (Figure 22B). The anterior surface of the tarsal plate is dissected horizontally to its medial and lateral limits and vertically until half of the extension. The conjunctiva is released until the upper fornix detaches the Muller muscle from the aponeurosis (Figure 22D). Using the Berke's clamp, the distal portion of the retractors is secured and the aponeurosis is dissected anteriorly (Figure 22C). The next steps are similar to the anterior approach described above (Figure 22E). After the desired resection the sutures are placed at the anterior surface of the tarsus (Figure 22F). Some difficulty may be experienced by less experienced surgeons, but it is important to bury the knots. This is not a popular technique since it is associated with complications such as eyelid crease defects and entropion.

Levator Aponeurosis Reinsertion

The aponeurosis reinsertion surgery has been widely used for the past two decades through anterior or posterior approaches.^{18,24,36,37} It is indicated for almost all cases of acquired ptosis with levator function.

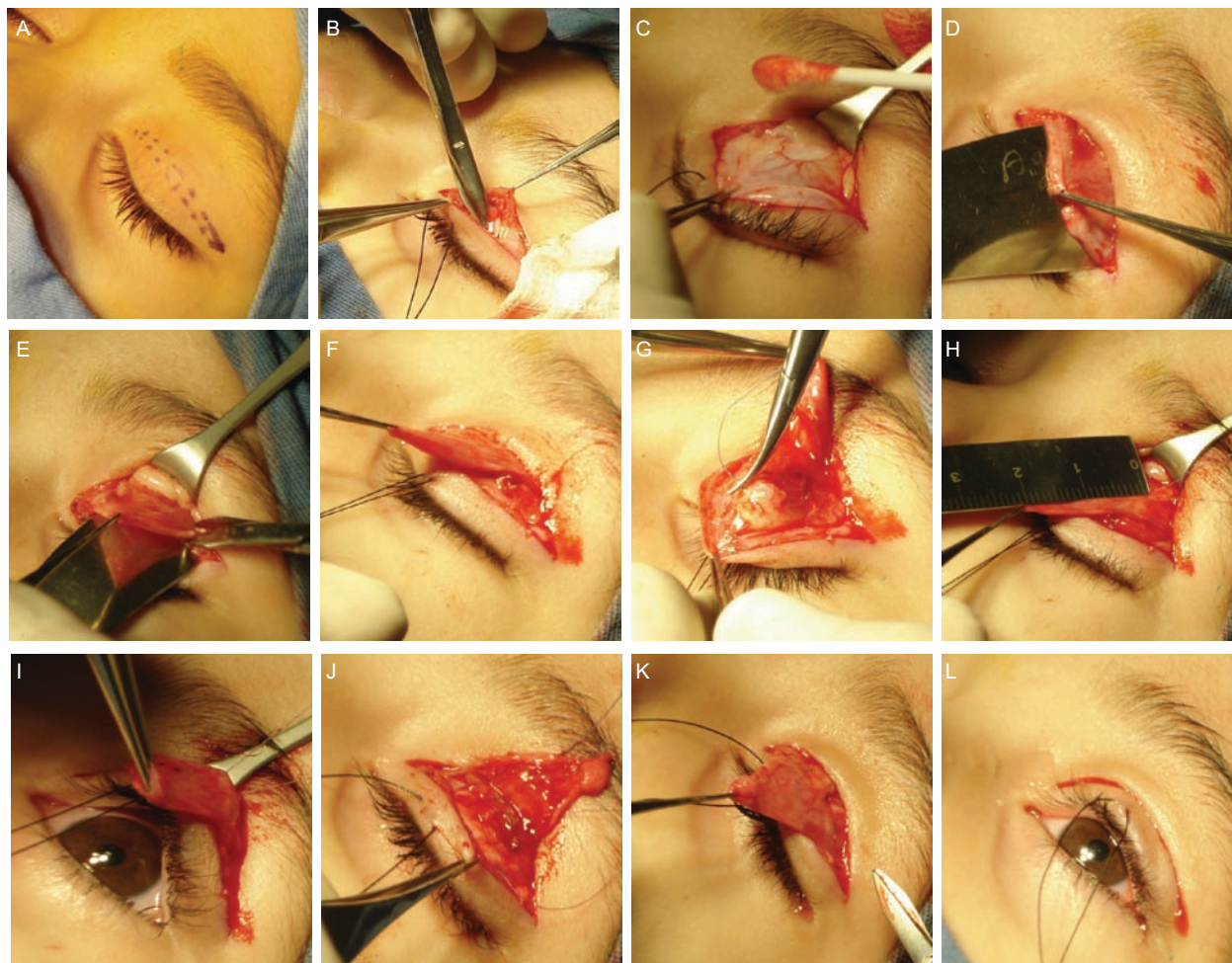


FIGURE 21 Levator aponeurosis resection via anterior (transcutaneous) approach. (A) Skin incision placed at the eyelid crease. (B) Skin incision and orbicularis dissection. (C) Orbital septum incision exposing the anterior surface of the aponeurosis and the Whitnall ligament. (D) Dissection of the upper lid retractors (aponeurosis and Muller muscle). (E) Sectioning of the lateral and medial expansions of the aponeurosis. (F) Dissected aponeurosis. (G) First stitch placed at the tarsus. (H) Sutures passed through the retractors. (I) Height adjustment. (J) Medial and lateral sutures. (K) Section of the distal portions of the aponeurosis and Muller muscle. (L) Final position.

Anterior (Transcutaneous) Approach

Transcutaneous aponeurosis reinsertion follows basically the same steps described for the resection using an anterior approach. When the aponeurosis is disinserted or thinned, the tissue observed above the tarsus is composed of conjunctiva and Muller muscle. There are several ways to identify the aponeurosis, but the author recommends globe compression to project the preaponeurotic fat. The fat pockets are located over the levator aponeurosis, observed as a whitish fibrous tissue. The distal portion of the aponeurosis is advanced towards the tarsal plate and fixated using three separate sutures as described above. If possible, the patient should be asked to look up and down so the final position can be established. Hypercorrection should be avoided because the lid margin tends to move up approximately 1 mm during the post-operative period. Estimating the hypercorrection is easier when the lid is

examined in down gaze. If the margin is located at the superior limbus or higher, the suture should be loosened. It is usually necessary to remove excessive skin. If a blepharoplasty is not indicated, ptosis surgery may be performed through a small central incision at the lid crease. The aponeurosis may be advanced and reattached with only one suture with optimal results.^{37,38}

Posterior (Transconjunctival) Approach

A mark is drawn at the skin corresponding to the highest curvature point of the lid margin. A traction suture using 4-0 silk is placed at the margin so that the lid can be everted over a Desmarres retractor (Figure 23A). Conjunctiva and Muller muscle are incised at the upper margin of the tarsus (Figure 23B). The anterior surface of the tarsal plate is dissected horizontally to its medial and lateral limits and vertically until half of the extension (Figure 23C). Because the aponeurosis

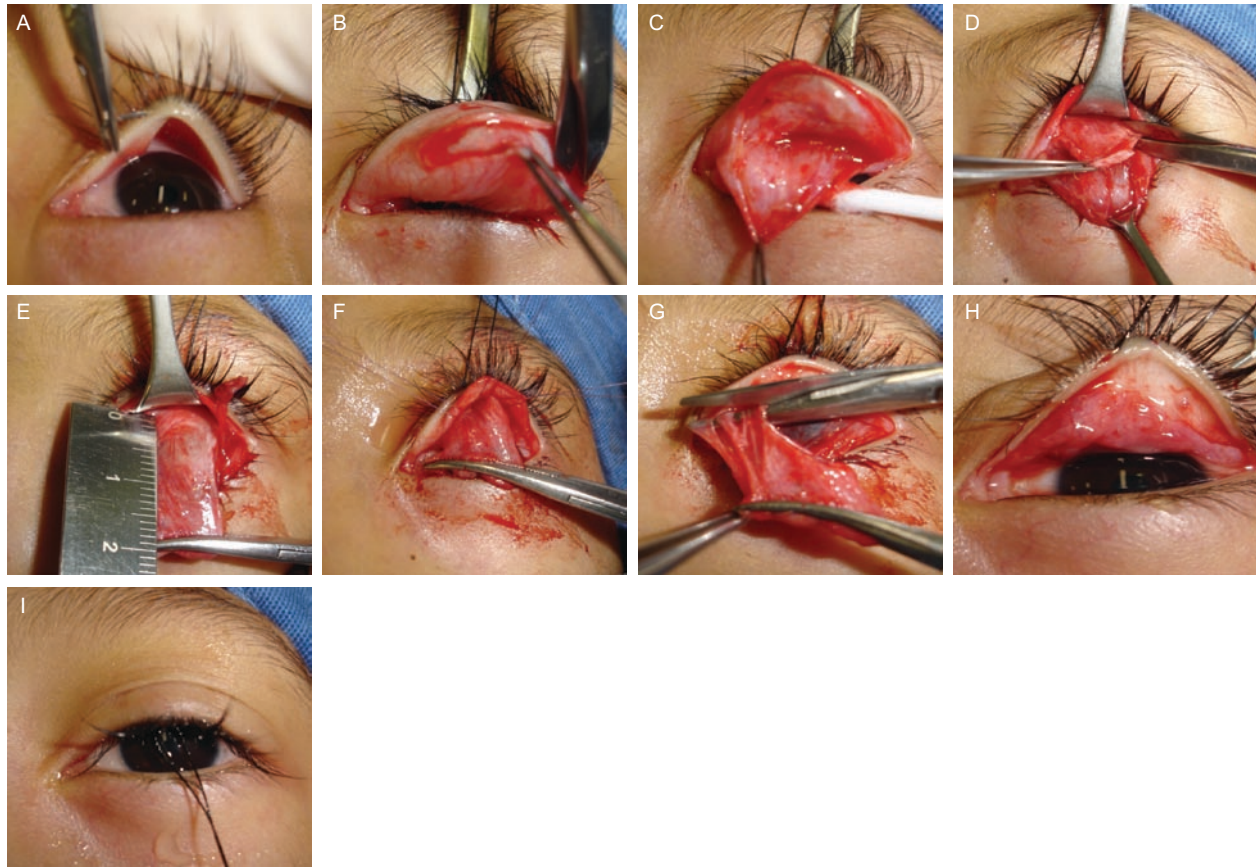


FIGURE 22 Levator aponeurosis resection via posterior (transconjunctival) approach. (A) Traction suture. (B) Incision of the conjunctiva and Muller muscle. (C) Dissection of the anterior surface of the aponeurosis. (D) Dissection of the posterior surface of the aponeurosis and incision of the medial and lateral expansion. (E) Measuring the resection. (F) Sutures placed at the anterior surface of the tarsus. (G) Aponeurosis suture and resection. (H) Final aspect of the conjunctiva. (I) Frost suture.

is disinserted or thinned, the distal portion is localized approximately 10 mm above the upper margin of the tarsus. Aponeurosis identification is facilitated by loosening the traction suture and grasping the conjunctiva with forceps, forming a tent. The whitish color of the aponeurosis may be observed. It should be grasped with forceps and pulled without dissecting the Muller muscle or opening the orbital septum. The advancement will naturally reposition the septum and the fat. The aponeurosis is reattached to the anterior surface of the tarsus using one, two or three sutures. It is not necessary to close the conjunctiva (Figure 23D, E, F).

This is an excellent technique to correct unilateral ptosis in which the sulcus is deeper than the contralateral side, especially if blepharoplasty is not necessary. The simple aponeurosis advancement and reattachment close to its original position restores the lid crease, and tractions the septum and the fat filling the superior sulcus. Patients of Asian descent need sutures to fixate the crease, which can be removed after two weeks.^{36,39} This procedure does not involve the resection of tarsus, conjunctiva, or Muller muscle.

Conjunctivomullerectomy

Initially indicated to correct Horner syndrome ptosis,⁴⁰ this technique may be used in all cases that present good response to the phenylephrine test.²⁵ The lid is everted over a Desmarres retractor and the height of the resection is marked in relation to the superior tarsus margin. A continuous suture is passed through the tarsus and the remnant conjunctiva and Muller muscle. The extremities are buried or exteriorized through the skin. It is the author's experience that the same results can be achieved when the distal portion of the aponeurosis and Muller are properly fixated to the anterior tarsus without any resection. The author favors the aponeurosis surgery through posterior or transconjunctival approach.

Frontalis Suspension Surgery

This technique is indicated when there is poor or absent levator function in severe ptosis. It is based on eyelid suspension to the frontalis muscle, above the eyebrow, using autogenous or alloplastic materials. The frontalis should present normal function. The material of choice for this procedure is autogenous fascia lata harvested from the lateral thigh, except in children younger than

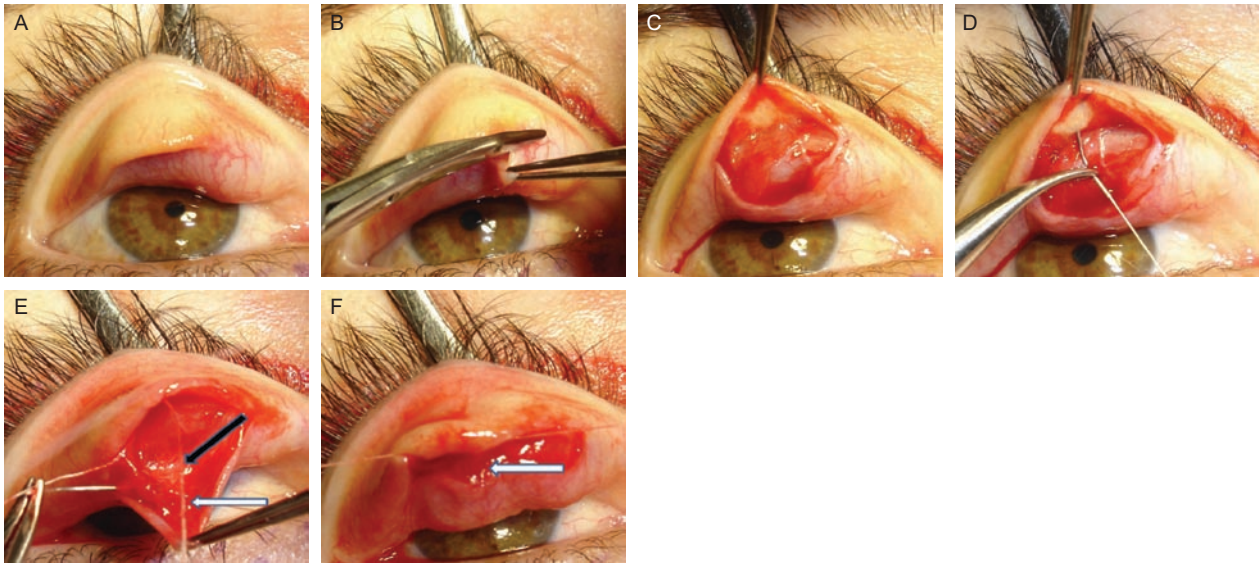


FIGURE 23 Levator aponeurosis reinsertion via posterior (transconjunctival) approach. (A) Lid eversion. (B) Conjunctiva and Muller muscle incision. (C) Exposure of the anterior surface of the tarsus. (D) Needle passed through the anterior surface of the tarsus. (E) Sutures passed through the desinserted aponeurosis (black arrow). Muller muscle and conjunctiva (white arrow). (F) Sutures attaching the aponeurosis to the tarsus. Muller muscle and conjunctiva are not sutured (white arrow).

4 years old due to the risk of muscular hernia. Recently, temporal fascia has been considered a better graft.⁴¹ Other material may be used, such as silicon rods or nonabsorbable sutures.

The most used techniques were described by Crawford⁴² using two fascia lata triangles, and by Fox,⁴³ employing a pentagon fixation using alloplastic material. The authors use a variation with one triangle with its large base attached to the anterior surface of the tarsus and the vertex located 1cm above the eyebrow. At this location, a single incision of 8mm is made, parallel to the eyebrow, corresponding to the central point of the triangle's base. At the lid crease, the incision should expose the anterior tarsus. The suspension material is fixated with three nonabsorbable sutures. Each end of the suspension material is mounted at semicircular needles or at the Wright needle for fascia lata. The needles are passed under the orbicularis towards the superior orbital margin and the central incision, and exteriorized. A temporary knot allows the evaluation of the final lid height and contour. After finalizing the suture, they should be cut leaving long ends that can be buried into the frontalis muscle. The eyelid incision is closed in two planes to restore the crease.

Complications

Hypercorrection is more frequent in aponeurotic ptosis. Besides being a risk for the ocular surface, it is also cosmetically unacceptable. Discrete retraction may be solved with massages and rarely needs surgical correction.

Hypocorrection is more common in aponeurosis resection for myogenic congenital ptosis. Many times it is expected and should be explained to the family

prior to the surgery. Hypocorrection might be part of the proposed planning, to avoid serious complications such as corneal exposure and ulcer, especially if the Bell phenomenon is absent or inadequate.

Lagophthalmos is universal in large resections over 20mm. Some exposure will occur during the first weeks and should be treated with lubricants and nocturnal patching. Children are usually more tolerant of lagophthalmos.

A second procedure, when necessary, may be indicated after the first week, depending on the severity of the case and the surgeon's experience.

Orbital hemorrhage is rare, but it is a medical emergency due to the threat to vision.

Refraction changes may follow ptosis surgery, some symptomatic.⁴⁴ It is important to perform a complete eye exam prior to the surgery and after three months.

Careless dissection, excessive coagulation, and suture misplacement may compromise the result of a good surgical plan. Reported complications include: entropion, ectropion, defective lid crease, irregular margin contour, madarosis, symblepharon and even ocular motility defects secondary to superior rectus or superior oblique muscle damage. All patients should be informed that additional procedures might be necessary, especially in complex myogenic ptosis, myopathies, and paralyses.

REFERENCES

- [1] Beard C. *Ptosis*. St. Louis: Mosby, 1969; 39–75.
- [2] Fox SA. *Lid Surgery - Current Concepts*. New York: Grune & Stratton, 1972.

- [3] Berke RN, Hackensack NJ. Congenital ptosis: a classification of two hundred cases. *Arch Ophthalmol*. 1949; 41L: 188–197.
- [4] Frueh BR. The mechanistic classification of ptosis. *Ophthalmology*. 1980; 87: 1019.
- [5] Frueh BR. Evaluation of blepharoptosis. In Waltman SR, et al., *Surgery of the Eye*. New York: Churchill Livingstone, 1988; 421–427.
- [6] Tyers AG, Collin JR. Senile ptosis-introduction and anterior approach. *Trans Ophthalmol Soc UK*. 1985; 104: 11–16.
- [7] Anderson RL, Dixon RS. Aponeurotic ptosis surgery. *Arch Ophthalmol*. 1979; 97: 1123.
- [8] Schaefer AJ, Schaefer DP. Classification and correction of ptosis. In Stewart WB, *Surgery of the Eyelid, Orbit and Lacrimal System*. San Francisco: American Academy of Ophthalmology, 1994; 84–133.
- [9] Edmunds B, Manners RM, Weller RO, et al. Levator palpebrae superioris fiber size in normals and patients with congenital fibrosis. *Eye*. 1998; 12: 47–50.
- [10] Baldwin HC, Manners RM. Congenital blepharoptosis. A literature review of the histology of levator palpebrae superioris muscle. *Ophthalm Plast Reconstr Surg*. 2002; 18(4): 301–307.
- [11] Steel DHW, Harrad RA. Unilateral congenital ptosis with ipsilateral superior rectus muscle overaction. *American Journal of Ophthalmology*. 1996; 122(4): 550–556.
- [12] Harrad R. Superior rectus-levator synkinesis. A previously unrecognized cause of failure of ptosis surgery. *Ophthalmology*. 2000; 107: 1975–1981.
- [13] Yazdani A, Traboulsi EI. Classification and surgical management of patients with familial and sporadic forms of congenital fibrosis of the extraocular muscles. *Ophthalmology*. 2004; 111: 1035–1042.
- [14] Engle EC. Applications of molecular genetics to the understanding of congenital ocular motility disorders. *Ann NY Acad Sci*. 2002; 956: 55–63.
- [15] Hanisch F, Bau V, Zier S. Congenital fibrosis of extraocular muscles (CFEOM) and other phenotypes of congenital cranial dysinnervation syndromes (CCDD). *Nervenarzt*. 2005; 76: 395–402.
- [16] Kau HC, Tsai CC, Ortube MC, Demer JL. High-resolution magnetic resonance imaging of the extraocular muscles and nerves demonstrates various etiologies of third nerve palsy. *Am J Ophthalmol*. 2007; 143: 280–287.
- [17] Bartlett SP, Mackay GJ. Craniosynostosis syndromes. In Beasley RW, Thome CHN, Aston SJ, *Grabb and Smith's Plastic Surgery*. Philadelphia: Lippincott-Raven, 1997; 295–304.
- [18] Anderson RL, Gordy DD. Aponeurotic defects in congenital ptosis. *Ophthalmology*. 1979; 86: 1493–500.
- [19] Trobe JD. Managing oculomotor nerve palsy. *Arch Ophthalmol*. 1998; 116: 798.
- [20] Zafeiriou DI, Economou M, et al. Congenital Horner's syndrome associated with cervical neuroblastoma. *Eur J Paediatr Neurol*. 2006; 10: 90–92.
- [21] Momtchilova M, Pelosse B, et al. Congenital Horner syndrome associated with hypoplasia of the internal carotid artery. *J Fr Ophthalmol*. 2009; 32: 126–130.
- [22] Linberg JV, McDonald MB. *Ophthalmology*. 1986; 93: 1509–1512.
- [23] Ideta S, Noda M, et al. Dehiscence of levator aponeurosis in ptosis after sub-Tenon injection of triamcinolone acetonide. *Can J Ophthalmol*. 2009; 44(6): 668–678.
- [24] Jones LT, Quicker MH, Wobig JL. The cure of ptosis by aponeurotic repair. *Arch Ophthalmol*. 1975; 93: 629–634.
- [25] Bassin RE, Putterman AM. Ptosis in young adults. *Int Ophthalmol Clin*. 2002; 42(2): 31–43.
- [26] Kersten RC, de Conciliis C, Kulwin DR. Acquired ptosis in the young and middle-aged adult population. *Ophthalmology*. 1995; 102(6): 924–928.
- [27] Deady JP, Morrell AJ, Sutton GA. Recongnising aponeurotic ptosis. *J Neurol Neurosurg Psychiatry*. 1989; 52: 996–998.
- [28] Saavedra J, Femminini R, Kochen S, deZarade JC. A cold test for myasthenia gravis [letter]. *Neurology*. 1979; 29: 1075.
- [29] Golnik KC, Pena R, Lee AG, et al. An ice test for the diagnosis of myasthenia gravis. *Ophthalmology*. 1999; 106: 1282–1286.
- [30] Kubis KC, Danesh-Meyer HV, Savino PJ, et al. The ice test versus the rest test in myasthenia gravis. *Ophthalmology*. 2000; 107: 1995–1998.
- [31] Chatzistefanou KI, Kouris T, et al. The ice pack test in the differential diagnosis of myasthenic diplopia. *Ophthalmology*. 2009; 116(11): 2236–2243.
- [32] Almousa R, Charlton A, Rajesh ST, Sundar G, Amrith S. Optimizing muscle biopsy for the diagnosis of mitochondrial myopathy. *Ophthalm Plast Reconstr Surg*. 2009; 25(5): 366–370.
- [33] Carrasco JR, Savino PJ, Bilyk JR. Primary aberrant oculomotor nerve regeneration from a posterior communicating artery aneurysm. *Arch Ophthalmol*. 2002; 120(5): 663–665.
- [34] Beynat J, Soichot P, Bidot S, et al. Iris heterochromia in acquired Horner's syndrome. *J Fr Ophthalmol*. 2007; 30(7): e19.
- [35] Maloney WF, Younger BR, Moyner NJ. Evaluation of the causes and accuracy of pharmacologic location of Horner's syndrome. *Am J Ophthalmol*. 1980; 90: 394–402.
- [36] Collin JRO. A ptosis repair of aponeurotic defects by the posterior approach. 1979; 63: 586–590.
- [37] Lucarelli MJ, Lemke BN. Small incision external levator repair: technique and early results. *Am J Ophthalmol*. 1999; 127(6): 637–644.
- [38] Frueh BR, Musch DC, McDonald HM. Efficacy and efficiency of a small-incision, minimal dissection procedure versus a traditional approach for correcting aponeurotic ptosis. *Ophthalmology*. 2004; 111(12): 2158–2163.
- [39] Ichinose A, Tahara S. Transconjunctival levator aponeurotic repair without resection of Muller's muscle. *Aesth Plast Surg*. 2007; 31: 279–284.
- [40] Glatt HJ, Putterman AM, Fett DR. Muller's muscle-conjunctival resection procedure in the treatment of ptosis in Horner's syndrome. *Ophthalmic Surg*. 1990; 21(2): 93–96.
- [41] Baker RH, de Silva JD, Henderson HW, et al. A novel technique of harvesting temporalis fascia autografts for correction of recurrent blepharoptosis. *Ophthalm Plast Reconstr Surg*. 2005; 21(4): 298–300.
- [42] Crawford JS. Repair of ptosis using frontalis muscle and fascia. *Trans Am Acad Ophthalmol Otolaryngol*. 1956; 60: 672.
- [43] Fox SA. Congenital ptosis, II. Frontalis sling. *J Pediatr Ophthalmol*. 1966; 3: 25.
- [44] Shao W, Byrne P, Harrison A, et al. Persistent blurred vision after blepharoplasty and ptosis repair. *Arch Facial Plast Surg*. 2004; 6: 155–157.
- [45] Hornblass A, Kass LG, Ziffer AJ. Amblyopia in congenital ptosis. *Ophthalm Surg*. 1995; 26: 334–337.
- [46] Agatston, SA. Resection of levator palpebrae muscle by the conjunctival route for ptosis. *Arch Ophthalmol*. 1942; 27: 994.
- [47] Matsuo K. Restoration of involuntary tonic contraction of the levator muscle in patients with aponeurotic blepharoptosis or Horer syndrome by aponeurotic advancement using the orbital septum. *Scand J Plast Reconstr Surg Hand Surg*. 2003; 37: 81–89.