

Severe Loss of Central Vision in Patients With Advanced Glaucoma Undergoing Trabeculectomy

Simon K. Law, MD; Anne M. Nguyen, BS; Anne L. Coleman, MD, PhD; Joseph Caprioli, MD

Objective: To evaluate the visual outcomes in patients with advanced visual field (VF) loss undergoing trabeculectomy with mitomycin C.

Methods: The records of patients with severe preoperative VF defects undergoing trabeculectomy from June 1, 1998, through October 31, 2005, were retrospectively reviewed. Severe loss of central vision was defined as visual acuity (VA) of 20/200 or less in the affected eye, counting fingers or less if preoperative VA was less than 20/200, or more than a 4-line reduction in Snellen VA.

Results: Central vision loss occurred in 7 of 117 patients (eyes) (6%) because of hypotony maculopathy (3 cases), uncontrolled elevated intraocular pressures (2 cases), posterior subcapsular cataract increase (1 case), and inflammatory reaction (1 case). A statistically sig-

nificant mean VA reduction after surgery from -0.32 to -0.39 (logMAR, $P=.01$) was found. Differences in VF parameters before and after surgery were not statistically significant. Patients who had severe loss of central vision had statistically significantly higher mean \pm SD preoperative intraocular pressures (27.1 ± 8.8 mm Hg vs 19.7 ± 8.1 mm Hg; $P=.04$) and higher rates of surgical complications (43% vs 4%; $P=.001$) compared with those who did not.

Conclusions: Severe loss of central vision after a trabeculectomy with mitomycin C occurred in 6% of patients who had glaucoma with marked VF loss. These patients had higher preoperative intraocular pressures and higher rates of surgical complications. Unexplained severe loss of central vision (snuff-out) was rare.

Arch Ophthalmol. 2007;125(8):1044-1050

PATIENTS WITH ADVANCED glaucomatous optic neuropathy have a high risk of further disease progression, which may affect the central vision. Large clinical trials have shown that successfully lowering intraocular pressures (IOPs) is associated with a decrease in visual field (VF) progression.¹⁻⁵ Although glaucoma procedures such as trabeculectomies are often required to effectively reduce or stabilize IOP, surgeons may be hesitant to recommend intraocular procedures in patients with glaucoma who have severely constricted VFs that involve central fixation because of concerns about the possibility of a loss or "snuff-out" of central vision after surgery. This belief probably stems from early reports that suggested that patients with advanced glaucoma were at high risk for loss of central vision after surgery.⁶⁻⁸ However, the exact reasons for sudden loss of central vision were unclear, and some ophthalmologists have suggested that surgery should be performed despite the risk of snuff-out.⁹⁻¹¹ Early studies^{7,9,12} that evaluated different types of glaucoma surgery,

such as full-thickness sclerectomy, thermal sclerostomy, iridencleisis, and Scheie procedures, may have limited applicability to current practice. In the 5 studies^{6,10,11,13,14} that evaluated the rate of severe loss of central vision after trabeculectomy, the rate ranged from 0% to 7.7%. This variability may be secondary to the small sample sizes in these studies. For example, the 2 prospective studies by Aggarwal and Hendeles⁶ and Topouzis et al¹¹ had 26 and 21 patients enrolled, respectively, and 2 of the 21 patients in the latter study had a combined trabeculectomy and cataract extraction. Two retrospective reviews on the incidence of central vision loss after trabeculectomy by Martinez et al¹⁰ and Langerhorst et al¹³ had larger sample sizes (50 eyes of 42 patients and 54 eyes of 44 patients, respectively); however, both studies did not take into account the correlation of 2 eyes for a patient being enrolled in the analysis. In another retrospective study, Costa et al¹⁴ identified 4 cases of central vision loss after a trabeculectomy; however, advanced VF defects were not an inclusion criterion for the study.

Author Affiliations: Jules Stein Eye Institute, University of California, Los Angeles.

Because the decision to proceed with trabeculectomy in patients with advanced glaucomatous VF loss remains controversial, we performed a comprehensive review, taking advantage of the practice environment of a tertiary glaucoma referral center with a large proportion of patients with advanced glaucoma, to evaluate the outcomes of visual acuity (VA) and perimetry in patients with advanced VF defects undergoing trabeculectomy with mitomycin C.

METHODS

Institutional review board approval was obtained through the University of California, Los Angeles, to conduct this retrospective review. The medical records of all patients who underwent trabeculectomy performed by 2 surgeons (S.K.L. and J.C.) from June 1, 1998, through October 31, 2005 (89 months), were reviewed. Patients who had severe preoperative glaucomatous VF defects were enrolled. The requirement for automated VF tests in recently published studies^{6,10,13} includes VF defects that encroached on the central 10°, which corresponds to the central 8 test points (or 15% of the test points, excluding the foveal test point) of standard automated perimetry with a 24-2 program. To be comparable with previous studies in identifying patients with advanced VF defects, severe VF defects were defined as those with a sensitivity of 5 dB or less either in more than 85% of test points, excluding the central 4 test points, or in more than 75% of test points, including 3 of the central 4 test points with threshold automated perimetry (full threshold or Swedish Interactive Threshold Algorithm [SITA] standard 24-2 program of the Humphrey Field Analyzer-750; Carl Zeiss Meditec, Dublin, California), with consistent optic nerve cupping. Patients were excluded if they had uveitic glaucoma, neovascular glaucoma, nonglaucomatous optic neuropathy, corneal or retinal disease, or aphakia or had undergone a concurrent procedure with a trabeculectomy. One eye of each patient was enrolled. If both eyes of a patient qualified, the eye with the greater VF damage was selected.

Medical data collected in this review included general medical diagnoses and systemic medications. Ocular data collected included ocular history, diagnoses, ocular examination results, ophthalmic medications used before and after the operation, surgical technique, and surgical complications. Surgical complications were defined as complications that resulted in decreased VA or required additional surgical intervention. Complications included, but were not limited to, hypotony maculopathy, flat anterior chamber that needed reformation, choroidal hemorrhage, and retrobulbar hemorrhage. Hypotony maculopathy was considered to be present if chorioretinal folds were noted in the macular area according to slitlamp examination with a noncontact fundus lens and with a decrease in VA. Information collected from the ophthalmic examination included VA, VF test results, anterior segment slitlamp examination results, IOP, gonioscopy findings, and fundus examination findings. Preoperative VA and IOP were recorded from the closest visit before surgery, and postoperative VA and IOP were recorded at 1 day, 1 week, 1 month, 3 months, and 6 months after the operation. The VA at 3 months postoperatively was used for analysis to allow enough time for recovery of vision after surgery and avoid transient vision decreases related to the surgery. The VA was measured with a Snellen chart and was converted to the logMAR VA scale for comparison. LogMAR values of -1.40, -2.70, and -4.70 were assigned to counting fingers, hand motions, and light perception, respectively.¹⁴ Severe loss of central vision was defined as best-corrected VA of 20/200 or less in the affected eye, counting fingers or less if preoperative vision was less than 20/200, or a reduction of more than 4 lines of Snellen VA at 3 months post-

operatively. Medical records were carefully reviewed to determine if any evident cause was responsible when there was a severe loss of central vision.

Anesthesia consisted of a peribulbar injection of a 1-to-1 mixture of 2% lidocaine hydrochloride and 0.75% bupivacaine hydrochloride without epinephrine. Two milliliters of the solution was injected into the inferior lateral orbit and 2 mL into the superior orbit with a 23-gauge 38-mm Atkinson needle (Eagle Laboratories, Rancho Cucamonga, California). Monitored anesthesia care was provided by an anesthesiologist, and no general anesthesia was required. A topical anesthetic supplement was used (0.5% tetracaine hydrochloride) as needed during surgery to enhance patient comfort.

The dissection of the conjunctiva was performed with either a fornix-based or limbus-based approach according to the preference and discretion of the surgeon. A 4.0 × 3.0-mm scleral flap was outlined with a surgical blade at the 12-o'clock position. Pieces of cut Weck-cel (Medtronic Xomed, Inc, Jacksonville, Florida) soaked in 0.3 mg/mL of mitomycin C were placed under the Tenon capsule and conjunctiva, covering an area of approximately 4.0 × 8.0 mm on the sclera at the outlined flap area for 1 minute. The Weck-cel pieces were removed, followed by thorough irrigation of the area exposed to mitomycin C with balanced salt solution. Then a partial-thickness, 4.0 × 3.0-mm rectangular sclera flap was dissected. A block of trabecular section was removed anterior to the scleral spur with a Kelly punch or No. 75 microsurgery blade and Vannas scissors, and a peripheral iridectomy was performed. The scleral flap was sutured at its 2 corners with interrupted 10-0 nylon sutures to ensure a slight egression of aqueous, and yet they were tied tight enough to maintain a deep anterior chamber. Finally, the limbus-based conjunctiva and Tenon capsule incision was sutured with a continuous 9-0 polyglactin suture, or the fornix-based peritomy incision was sutured to the limbus with an interrupted 9-0 polyglactin suture.

Postoperatively, patients received a 4- to 6-week tapering dose of 1% prednisolone acetate ophthalmic drops starting at 4 times daily. Suture lysis was performed with an argon laser for inadequate IOP control or a low filtering bleb 1 to 4 weeks after surgery. The target IOP before laser suture lysis or the addition of ocular hypotensive therapy was in the low teens or less, with the goal of preventing further progression of functional visual loss.

Statistical analysis was performed with SPSS statistical software, version 13.0, for Windows (SPSS Inc, Chicago, Illinois). Descriptive statistics were used to report the incidence of loss of VA after the surgery. The VAs in logMAR values and the VF test results before and after surgery were compared with the *t* test. The VF test results within 6 months before and after surgery were used for comparison. Forty-six patients had reliable VF test results before and after the trabeculectomy for analysis, which provided an 80% power level to detect a difference of 2 dB of average mean deviation (MD) or a 3-dB difference in the central 4-point mean before and after trabeculectomy at an α level of .05. A logistic regression model was used to compare patients who had severe loss of vision with the remaining group of patients who did not lose vision. Statistical significance was defined as $P < .05$.

RESULTS

The medical records of 1304 patients who underwent trabeculectomy with mitomycin C were retrospectively reviewed. A total of 117 patients (117 eyes, 9%) had severe VF defects without other exclusion criteria. The MD ± SD of the preoperative VF was 25.2 ± 5.1 dB. **Figure 1** and **Figure 2** display the IOP and VA levels during 1 year of follow-up, respectively. Seven patients (6%) had severe loss

of central vision after surgery; causes of vision loss included hypotony maculopathy (3 cases), uncontrolled elevated IOPs (2 cases), increase in a posterior subcapsular cataract (1 case), and a severe noninfectious inflammatory reaction (1 case). The patient with increase in posterior subcapsular cataract recovered vision to 20/50 in the affected eye after cataract surgery, but the other 6 patients did not. **Table 1** summarizes the demographic and clinical data of the 7 patients.

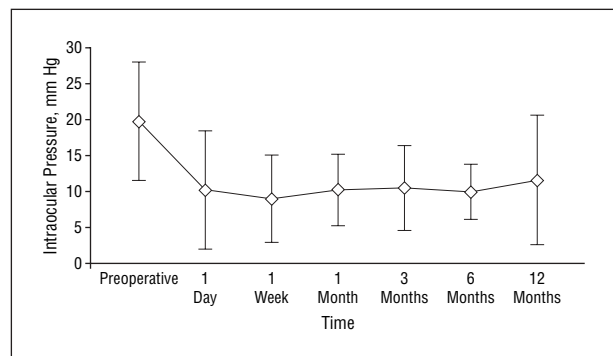


Figure 1. Mean intraocular pressure of all patients during 1 year of follow-up. Error bars indicate SDs.

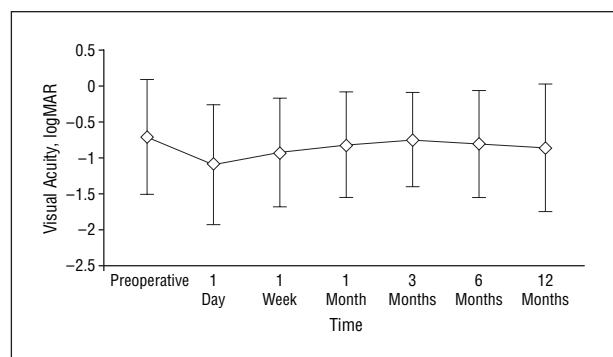


Figure 2. Mean visual acuity of all patients during 1 year of follow-up. Error bars indicate SDs.

Eighty-five patients (73%) had a VA better than 20/200 in the affected eye before the trabeculectomy. In these 85 patients, a small but statistically significant reduction in mean VA was found after surgery from -0.32 to -0.39 (logMAR), corresponding to a reduction from approximately 20/40 to 20/50 Snellen VA ($P = .01$). **Figure 3** represents the frequency distribution of VA changes in

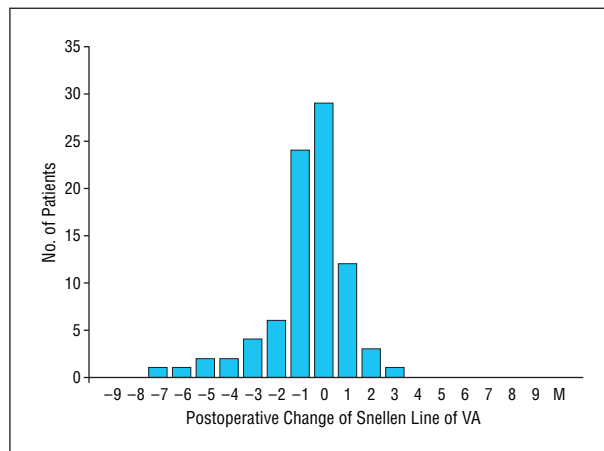


Figure 3. Frequency distribution of visual acuity (VA) change after surgery in 85 patients with preoperative visual acuity better than 20/200 in the affected eye.

Table 2. Ranked Reasons for Visual Acuity Decrease of More Than 1 Line of Snellen Visual Acuity in 16 Patients

Reason	Patients, No. (%)
Cataract increase	7 (44)
Disease progression	2 (12)
Hypotony maculopathy	3 (19)
Epiretinal membrane and/or cystoid macular edema	2 (12)
Without identifiable cause	1 (6)
Severe inflammation	1 (6)
Total	16 (100)

Table 1. Ophthalmic Information of the 7 Patients With Primary Open-Angle Glaucoma Who Had a Loss of Central Vision

Race/Sex/ Age, y	Medical Diagnosis	Lens Status	IOP, mm Hg				VA		Time of Postoperative VA Loss/Cause of Loss
			Preoperative	Day 1	Week 1	Month 3	Preoperative	Month 3	
B/F/73 ^a	DM	PCIOL	26.0	15.0	11.0	7.0	20/40	20/300	3 mo/Hypotony maculopathy
W/M/78	History of CVA, history of MI, kidney disease	Phakic	26.0	2.0	3.0	5.0	20/50	20/200	3 mo/Cataract increase
W/M/83	DM	Phakic	36.0	12.5	5.0	11.0	20/50	20/300	1 d/Severe postoperative inflammation
B/F/88 ^b	Hypertension, asthma, thyroid disease	PCIOL	25.0	2.0	4.0	19.5	20/60	20/200	1 wk/Uncontrolled IOP
W/M/37	Kidney disease, fatty liver	Phakic	32.0	0.5	0.5	1.0	20/80	CF	1 d/Hypotony maculopathy
W/F/72	SLE	Phakic	16.5	34.5	27.5	8.0	20/400	CF	1 d/Uncontrolled IOP
W/M/77 ^b	None	PCIOL	38.0	0	2.0	5.0	20/400	CF	1 d/Hypotony maculopathy

Abbreviations: CF, counting fingers; CVA, cerebrovascular accident; DM, diabetes mellitus; IOP, intraocular pressure; MI, myocardial infarction; PCIOL, posterior chamber intraocular lens; SLE, systemic lupus erythematosus; VA, visual acuity.

^a Only this patient had previously undergone trabeculectomy.

^b All patients underwent limbus-based dissection of the conjunctiva except for these 2 patients, who underwent fornix-based dissection.

Table 3. Comparison of Patients With and Without Severe Loss of Central Vision

Variable	No. (%) of Patients ^a		P Value
	With Severe Loss of Vision (n = 7)	Without Severe Loss of Vision (n = 110)	
Age, mean (SD), y	72.6 (17)	76.1 (14)	.52
Sex			
Male	4 (57)	63 (57)	.99
Female	3 (43)	47 (43)	
Eye			
Right eye	5 (71)	49 (44)	.19
Left eye	2 (29)	61 (55)	
Race			
White	5 (71)	66 (60)	.55
Other	2 (29)	40 (40)	
Diagnosis			
POAG	7 (100)	84 (76)	.99
Non-POAG	0	26 (24)	
Lens status			
Phakic	4 (57)	55 (52)	.68
Pseudophakic	3 (43)	51 (46)	
Prior operation			
Yes	3 (43)	55 (52)	.72
No	4 (57)	51 (48)	
Medical condition			
Hypertension	1 (14)	35 (32)	.35
Diabetes mellitus	2 (29)	19 (17)	.46
Cardiovascular disease	2 (29)	14 (13)	.91
Receiving anticoagulation therapy	0	4 (4)	.99
Surgical technique			
Fornix based	2 (29)	20 (18)	.50
Limbus based	5 (71)	90 (82)	
Surgeon			
J.C.	4 (57)	63 (57)	.99
S.K.L.	3 (43)	47 (43)	
Preoperative visual acuity, mean (SD), logMAR	-0.72 (0.82)	-0.68 (0.43)	.90
IOP, mean (SD), mm Hg			
Preoperative	27.1 (8.8)	19.7 (8.1)	.04
Postoperative, day 1	10.0 (12.8)	10.2 (7.9)	.94
Postoperative, week 1	7.1 (9.3)	9.1 (5.8)	.44
Postoperative, month 3	8.1 (5.9)	10.3 (4.0)	.52
Preoperative minus postoperative, day 1	17.1 (18.2)	9.6 (11.0)	.15
Preoperative visual field, mean (SD)			
Mean deviation	-26.9 (5.3)	-25.1 (5.1)	.36
Pattern standard deviation	5.4 (3.7)	6.4 (2.9)	.37

Abbreviations: IOP, intraocular pressure; POAG, primary open-angle glaucoma.

^a Data are presented as number (percentage) of patients unless otherwise indicated.

the 85 patients. Sixteen of the 85 patients (19%) had a decrease of more than 1 line of Snellen VA at 3 months postoperatively. **Table 2** ranks the reasons for the decreased VA in the 16 patients. Eleven of the 16 patients (69%) were phakic before the trabeculectomy. Seven of the 11 patients (64%) had an increase in their cataracts that was determined to be the cause of their VA decrease if it was documented on clinical examination in the absence of other causes of VA decrease (3 patients) or on

Table 4. Comparison of Surgical Complications in Patients With and Without Severe Loss of Central Vision

Complication	No. (%) of Patients	
	Patients With Severe Loss of Central Vision (n = 7)	Patients Without Severe Loss of Central Vision (n = 110)
Complication by patient	3 (43)	4 (4)
Hypotony maculopathy	2 (29)	2 (2)
Flat anterior chamber needed reformation	1 (14)	1 (1)
Choroidal hemorrhage	0	1 (1)
Retrobulbar hemorrhage	0	1 (1)

the basis that the VA improved to or was better than baseline after subsequent cataract surgery (4 patients). The 3 patients with cataracts documented on clinical examination as the cause of their VA decrease chose not to receive the cataract surgery. One of the 16 patients had no identifiable cause of the decrease of more than 1 line of Snellen VA. This patient had a preoperative VA of 20/50 in the affected eye that decreased to 20/60 at 1 month and to 20/70 at 3 months postoperatively, despite IOP reduction from 19 mm Hg preoperatively to 12 mm Hg postoperatively.

Not every patient underwent VF testing after the trabeculectomy in this retrospective study. Forty-six of 85 patients (39%) had reliable VF test results before and after the trabeculectomy. The average MD ± SD was -24.8 ± 4.1 dB. No statistically significant differences were found between the VF test results before and after trabeculectomy for the mean value of all test points, mean value of the central 4 test points, MD, pattern standard deviation, and area under the curve of the VF (sum of thresholds in decibels of all test points, $P = .80$, $.99$, $.07$, and $.67$, respectively).

Table 3 and **Table 4** summarize the comparison with a logistic regression model between the 7 patients who had severe loss of central vision after surgery and the 110 patients who did not. Patients who experienced a severe loss of central vision had statistically significantly higher preoperative IOP (mean ± SD, 27.1 ± 8.8 mm Hg vs 19.7 ± 8.1 mm Hg; $P = .04$) and higher rates of surgical complications (43% vs 4%; $P = .001$) compared with patients without severe loss of central vision. No statistically significant differences were found between the 2 groups with regard to different surgeons, age, race, sex, diagnosis, lens status, prior operations, preoperative VA, medical conditions (such as hypertension, diabetes mellitus, and cardiovascular disease), use of systemic anticoagulation therapy, and fornix- vs limbus-based surgical techniques. Reanalysis with preoperative IOP and surgical complications entered as covariates in a multivariate logistic regression model showed surgical complications to be the only statistically significant factor in association with severe loss of central vision in patients with advanced glaucomatous VF defects undergoing trabeculectomy with mitomycin C (odds ratio, 15.32; 95% confidence interval, 2.38-98.63; $P = .004$).

Table 5. Existing Studies on Incidence of Vision Loss After Glaucoma Procedures

Source	No. of Eyes (No. of Patients)	Study Design	Procedures Studied (No.)	VF Defect Requirement (Type of VF Test)	No. (%) With Severe Vision Loss After Glaucoma Surgery ^a	Reasons for Severe Vision Loss (No.)	No. (%) With Unexplained Severe Vision Loss
Lichter and Ravin, ⁹ 1974	Total: 52 (?) (38 eyes with severe VF defects)	Retrospective	Thermal sclerostomy (49), trabeculectomy (3)	Involve central 5° (unknown)	0		0
O'Connell and Karseras, ¹² 1976	46 (46)	Retrospective	Trabeculectomy (25), Scheie procedure (12), iridencleisis (8), Stallard procedure (2)	Encroaching central fixation (Goldmann)	10 (21.7)	Refractive error changes or cataract formation (4), preexistent maculopathy (3), flat A/C and choroidal effusion (1)	1 (2.2)
Kolker, ⁷ 1977	Total: 101 (76) (22 eyes of 19 patients had undergone glaucoma surgery)	Retrospective	Trabeculectomy (11), posterior lip sclerectomy (2), thermal sclerotomy (7), goniotomy (2)	Within central 5° (Goldmann, tangent screen)	3 (13.6)	Flat A/C (1), severe postoperative inflammation (1)	0
Aggarwal and Hendeles, ⁶ 1986	26 (26)	Prospective	Trabeculectomy (26)	10° Central island or encroaching central 10° (Goldmann)	4 (15.4)	CME (1), shallow A/C (1)	2 (7.7)
Langerhorst et al, ¹³ 1990	50 (42)	Retrospective	Filtering procedure (37), cataract surgery (13)	Involving central 10° (automated static perimetry)	3 (6.0)	Corneal edema and neovascular changes (1), corneal decompensation (2)	1 (2.0, uncertain from filtering vs cataract surgery)
Levene, ⁸ 1992	86 (69) (Additional 10 eyes of 10 patients as controls)	Retrospective	Through-and-through glaucoma procedure (30), guarded procedure (66) (fluorouracil used in 20 eyes)	Sensitivity loss of at least 10 dB at the 1.4° eccentricity points (Goldmann, Humphrey)	1 (1.0) (3 [3.0] with any decrease in vision from all eyes)	Not specified	
Martinez et al, ¹⁰ 1993	54 (44)	Retrospective	Trabeculectomy (limbus based)	Absolute defect within central 10° (Goldmann) 2 unseen points within central 10° (Humphrey)	0		0
Costa et al, ¹⁴ 1993	508 (440) (4 cases of VA wipe-out were compared with 75 controls)	Retrospective	Trabeculectomy (fluorouracil used in 24 eyes), trabeculectomy with anterior vitrectomy (3), trabeculectomy with Molteno implantation (6)	No requirement (Goldmann, Humphrey)	42 of 421 eyes at risk (9.29%) had VA decrease > 1 line	Cataract, hypotony, maculopathy, CME, PCO, VH, SCH, RD, IOP increase	4 of 421 eyes at risk (0.95), older patients, preoperative VF with macular splitting, and severe postoperative hypotony were associated with wipe-out
Topouzis et al, ¹¹ 2005	21 (21)	Prospective	Trabeculectomy with mitomycin C (19), trabeculectomy with mitomycin C and cataract operation (2)	AGIS score >16 (Humphrey)	0		0
Current study	117 (117)	Retrospective	Trabeculectomy with mitomycin C	> 85% test points ≤ 5 dB or > 75% test points ≤ 5 dB and 3/4 of central test points ≤ 5 dB (Humphrey)	7 (6.0)	Hypotony, maculopathy, inflammation, cataract, uncontrolled IOP	0

Abbreviations: A/C, anterior chamber; AGIS, Advanced Glaucoma Intervention Study²; CME, cystoid macular edema; IOP, intraocular pressure; PCO, posterior capsule opacity; RD, retinal detachment; SCH, suprachoroidal hemorrhage; VA, visual acuity, VF, visual field; VH, vitreous hemorrhage.

^aGenerally defined as visual acuity less than or equal to 20/200 in the affected eye (Snellen).

COMMENT

We have found that unexplained snuff-out or loss of central vision after a trabeculectomy with mitomycin C is rare. Existing data on the occurrence of severe loss of vision are limited.⁶⁻¹⁴ Although a few studies^{6,10,11,13,14} have evaluated glaucoma surgery with more current surgical

techniques, the inclusion of trabeculectomy with and without an antimetabolite as adjuvant, trabeculectomy with concurrent procedures such as cataract extraction, anterior vitrectomy, Molteno implantation, and even cataract extraction in the analysis render the interpretation and application of the results difficult. **Table 5** summarizes the available studies in the English literature on

the incidence of severe loss of central vision after glaucoma surgery. Reasons for severe loss of central vision are listed, and the rates of unexplained severe loss of central vision are reported separately.

Of the 9 published studies, 2 prospective studies^{6,11} had small sample sizes. Aggarwal and Hendeles⁶ prospectively studied 26 patients (eyes) whose VF had only a central island remaining or had a defect that was encroaching on the central 10° who were undergoing trabeculectomy without antimetabolites. Four patients (15.4%) were reported to have a loss of central vision. One patient developed cystoid macular edema, and another had a shallow anterior chamber after surgery. The remaining 2 patients (7.7%) had no explainable cause for the vision loss. The authors concluded that there was a considerable risk of sudden loss of VF in patients with small residual VFs undergoing trabeculectomy.⁶

In another prospective study by Topouzis et al,¹¹ in which 21 patients (eyes) who had advanced glaucomatous VF defects on automated perimetry with scores of more than 16 (of 20) on the VF scoring system of the Advanced Glaucoma Intervention Study,² no patient experienced severe loss of central vision with trabeculectomy with mitomycin C, with or without cataract extraction and intraocular lens implantation.

Among the studies that reported cases of severe loss of central vision, most cases had explainable causes. In the review by Costa et al¹⁴ of 508 eyes of 440 patients, who underwent trabeculectomy with or without postoperative subconjunctival injection of fluorouracil or with concurrent anterior vitrectomy or Molteno implantation, 9.3% of the patients had reduction of more than 1 line of Snellen VA at 3 months after the procedure. Reasons for vision loss included hypotony maculopathy, cystoid macular edema, cataract, posterior capsule opacity, vitreous hemorrhage, choroidal hemorrhage, retinal detachment, and uncontrolled IOP. Four eyes (0.95%) had postoperative VA decreased to 20/200 or less. These 4 cases were described as having a “snuff-out” or “wipe-out” of vision. However, it is uncertain if the postoperative occurrence of IOP greater than 22 mm Hg at 1 day postoperatively, hyphema, encapsulated bleb, and choroidal detachment in these 4 cases were the actual causes for the vision loss.¹⁴ In our review, in which only trabeculectomy with mitomycin C was studied, all patients who had severe loss of central vision had an explainable cause. This is consistent with the overall impression summarized in Table 5 that unexplained severe loss of central vision from trabeculectomy is rare, even in patients with advanced VF defects that involve central fixation.

Although all patients who had severe loss of central vision had an explainable cause, a rate of 6% with severe loss of central vision after trabeculectomy in this group of patients with advanced glaucomatous optic neuropathy still represents a significant risk and should dictate appropriate caution in planning this procedure. In our retrospective review, patients who had severe loss of vision after trabeculectomy with mitomycin C had higher rates of surgical complications and higher preoperative IOPs. Although patients with severe loss of central vision had greater reductions in IOP after surgery

(mean ± SD preoperative IOP minus postoperative IOP, 17.1 ± 18.2 mm Hg) than patients without severe loss of vision (9.6 ± 11.0 mm Hg), this difference was not statistically significant, probably because of the small number of patients. Three of the 7 patients who had central vision loss in our study had hypotony maculopathy. This finding is consistent with the review by Costa et al,¹⁴ in which severe postoperative hypotony was associated with severe loss of vision (snuff-out) after glaucoma surgery. Hypotony maculopathy and flat anterior chamber that required reformation were probably the result of overfiltration, which should be carefully avoided in performing glaucoma procedures. Planned argon laser suture lysis to allow a gradual reduction of IOP after trabeculectomy may lower the rate of overfiltration.

In our subgroup analysis of the 85 patients who had preoperative Snellen VA better than 20/200, a small but statistically significant reduction in acuity was found. Sixteen patients (19%) had a decrease of more than 1 line of Snellen VA 3 months postoperatively. Seven of 11 patients (64%) who were phakic preoperatively had a vision decrease secondary to an increase in cataract. Cataract development or progression is a common cause of VA reduction after trabeculectomy. The Advanced Glaucoma Intervention Study¹⁵ reported an increased risk of 78% for cataract formation.

Limitations of this study are its retrospective design and short-term follow-up. In addition, our findings may not be generalizable to patients who are younger than those in this study. Although no statistically significant changes in VF test results were found after trabeculectomy in this study, the small proportion of patients (46 patients, 39%) with reliable preoperative and postoperative VF test results available for analysis makes it difficult to draw any conclusion.

In summary, approximately 6% of patients who had glaucoma with advanced preoperative VF defects who underwent trabeculectomy with intraoperative mitomycin C had a severe reduction in their central VA. Patients who lost central vision had statistically significantly higher rates of surgical complications and higher preoperative IOPs. Unexplained snuff-out or loss of central vision was not observed.

Submitted for Publication: November 1, 2006; final revision received January 4, 2007; accepted January 22, 2007.

Correspondence: Simon K. Law, MD, 100 Stein Plaza 2-235, Jules Stein Eye Institute, Los Angeles, CA 90095 (law@jsei.ucla.edu).

Author Contributions: Dr Law has full access to all the data in the study and takes responsibility for the integrity of the data and the accuracy of the data analysis.

Financial Disclosure: None reported.

Previous Presentation: Presented in part as a poster at the Association for Research in Vision and Ophthalmology meeting; May 4, 2006; Fort Lauderdale, Florida.

REFERENCES

1. Migdal C, Gregory W, Hitchings R. Long-term functional outcome after early surgery compared with laser and medicine in open-angle glaucoma. *Ophthalmology*. 1994;101(10):1651-1656.

2. The AGIS Investigators. The Advanced Glaucoma Intervention Study (AGIS) 4: comparison of treatment outcomes within race: seven-year results. *Ophthalmology*. 1998;105(7):1146-1164.
3. Collaborative Normal-Tension Glaucoma Study Group. Comparison of glaucomatous progression between untreated patients with normal-tension glaucoma and patients with therapeutically reduced intraocular pressures. *Am J Ophthalmol*. 1998;126(4):487-497.
4. Lichter PR, Musch DC, Gillespie BW, et al. Interim clinical outcomes in the Collaborative Initial Glaucoma Treatment Study comparing initial treatment randomized to medications or surgery. *Ophthalmology*. 2001;108(11):1943-1953.
5. Heijl A, Leske MC, Bengtsson B, Hyman L, Bengtsson B, Hussein M; Early Manifest Glaucoma Trial Group. Reduction of intraocular pressure and glaucoma progression: results from the Early Manifest Glaucoma Trial. *Arch Ophthalmol*. 2002;120(10):1268-1279.
6. Aggarwal SP, Hendeles S. Risk of sudden visual loss following trabeculectomy in advanced primary open-angle glaucoma. *Br J Ophthalmol*. 1986;70(2):97-99.
7. Kolker AE. Visual prognosis in advanced glaucoma: a comparison of medical and surgical therapy for retention of vision in 101 eyes with advanced glaucoma. *Trans Am Ophthalmol Soc*. 1977;75:539-555.
8. Levene RZ. Central visual field, visual acuity, and sudden visual loss after glaucoma surgery. *Ophthalmic Surg*. 1992;23(6):388-394.
9. Lichter PR, Ravin JG. Risks of sudden visual loss after glaucoma surgery. *Am J Ophthalmol*. 1974;78(6):1009-1013.
10. Martinez JA, Brown RH, Lynch MG, Caplan MB. Risk of postoperative visual loss in advanced glaucoma. *Am J Ophthalmol*. 1993;115(3):332-337.
11. Topouzis F, Tranos P, Koskosas A, et al. Risk of sudden visual loss following filtration surgery in end-stage glaucoma. *Am J Ophthalmol*. 2005;140(4):661-666.
12. O'Connell EJ, Karseras AG. Intraocular surgery in advanced glaucoma. *Br J Ophthalmol*. 1976;60(2):124-131.
13. Langerhorst CT, de Clercq B, van den Berg TJ. Visual field behavior after intraocular surgery in glaucoma patients with advanced defects. *Doc Ophthalmol*. 1990;75(3-4):281-289.
14. Costa VP, Smith M, Spaeth GL, Gandham S, Markovitz B. Loss of visual acuity after trabeculectomy. *Ophthalmology*. 1993;100(5):599-612.
15. AGIS (Advanced Glaucoma Intervention Study) Investigators. The Advanced Glaucoma Intervention Study 8: risk of cataract formation after trabeculectomy. *Arch Ophthalmol*. 2001;119(12):1771-1779.

From the Archives of the Archives

Soon after the publication in 1866 of Donder's work on refraction, American ophthalmologists began to busy themselves with this subject, and by the end of the century had become expert in the determination of refractive errors. Following the lead of Weir Mitchell, a neurologist, many convinced themselves that uncorrected or improperly corrected refractive errors not only often caused headaches and ocular discomfort but caused or contributed to a variety of other symptoms, and even to organic disease. They did not devise any basically new methods of testing, but applied with meticulous care methods already known. It was believed that astigmatism of $\frac{1}{8}$ D could cause serious so-called eyestrain.

Reference: Verhoeff FH. American ophthalmology during the past century. *Arch Ophthalmol*. 1948;39:462.