

Revised Recommendations on Screening for Chloroquine and Hydroxychloroquine Retinopathy

Michael F. Marmor, MD,¹ Ulrich Kellner, MD,² Timothy Y. Y. Lai, MD,³ Jonathan S. Lyons, MD,⁴ William F. Mieler, MD,⁵ for the American Academy of Ophthalmology

Background: The American Academy of Ophthalmology recommendations for screening of chloroquine (CQ) and hydroxychloroquine (HCQ) retinopathy were published in 2002, but improved screening tools and new knowledge about the prevalence of toxicity have appeared in the ensuing years. No treatment exists as yet for this disorder, so it is imperative that patients and their physicians be aware of the best practices for minimizing toxic damage.

Risk of Toxicity: New data have shown that the risk of toxicity increases sharply toward 1% after 5 to 7 years of use, or a cumulative dose of 1000 g, of HCQ. The risk increases further with continued use of the drug.

Dosage: The prior recommendation emphasized dosing by weight. However, most patients are routinely given 400 mg of HCQ daily (or 250 mg CQ). This dose is now considered acceptable, except for individuals of short stature, for whom the dose should be determined on the basis of ideal body weight to avoid overdosage.

Screening Schedule: A baseline examination is advised for patients starting these drugs to serve as a reference point and to rule out maculopathy, which might be a contraindication to their use. Annual screening should begin after 5 years (or sooner if there are unusual risk factors).

Screening Tests: Newer objective tests, such as multifocal electroretinogram (mfERG), spectral domain optical coherence tomography (SD-OCT), and fundus autofluorescence (FAF), can be more sensitive than visual fields. It is now recommended that along with 10-2 automated fields, at least one of these procedures be used for routine screening where available. When fields are performed independently, even the most subtle 10-2 field changes should be taken seriously and are an indication for evaluation by objective testing. Because mfERG testing is an objective test that evaluates function, it may be used in place of visual fields. Amsler grid testing is no longer recommended. Fundus examinations are advised for documentation, but visible bull's-eye maculopathy is a late change, and the goal of screening is to recognize toxicity at an earlier stage.

Counseling: Patients should be aware of the risk of toxicity and the rationale for screening (to detect early changes and minimize visual loss, not necessarily to prevent it). The drugs should be stopped if possible when toxicity is recognized or strongly suspected, but this is a decision to be made in conjunction with patients and their medical physicians.

Financial Disclosure(s): Proprietary or commercial disclosure may be found after the references. *Ophthalmology* 2011;118:415–422 © 2011 by the American Academy of Ophthalmology.

Retinal toxicity from chloroquine (CQ) and its analogue, hydroxychloroquine (HCQ), has been recognized for many years. The first reports concerned long-term use of CQ for malaria, and later reports showed retinopathy after treatment of anti-inflammatory diseases.^{1,2} Chloroquine toxicity remains a problem in many parts of the world, but it is seen infrequently in the United States, where the drug has largely been replaced by HCQ for the treatment of systemic lupus erythematosus, rheumatoid arthritis, and other inflammatory and dermatologic conditions. Retinal toxicity from HCQ has a low incidence, but many thousands of individuals take this drug for medical indications.³ Toxicity from these drugs is of serious ophthalmologic concern because even after cessation of the drugs, there is little if any visual recovery,

and sometimes progression of visual loss.⁴ Thus, it is imperative that ophthalmologists and other physicians be aware of this disorder and take measures to minimize its occurrence and effects.

The 2002 version of this document⁵ was prepared because different screening regimens had been proposed, which varied considerably in practicality, costs, and cost/benefit ratio. There was need for a consensus recommendation. The *Physicians' Desk Reference*, for example, recommended quarterly examinations that would represent an enormous burden on health care resources. Yet most authors concur that some screening for early toxicity is reasonable.

This revised recommendation has significant changes in light of new data on the prevalence of retinal toxicity and

the sensitivity of new diagnostic techniques. It recognizes that the risk of toxicity after years of HCQ use is higher than previously believed. It removes the Amsler grid from the list of acceptable screening techniques and advises strongly that 10-2 visual fields be supplemented with sensitive objective tests, such as multifocal electroretinogram (mfERG), spectral domain-optical coherence tomography (SD-OCT), and fundus autofluorescence (FAF). It emphasizes the value of fundus examination for detecting unrelated retinal pathology that may affect the recognition of toxicity, but fundus changes are not considered sensitive enough for screening. The goal of screening should be the recognition of toxicity before bull's-eye retinopathy is visible on fundus examination. There is no change in the recommendation (for routine cases) to obtain a baseline examination when the drug is started and to begin annual screening 5 years later. However, recommendations on dosage and criteria for judging risk have been revised. These guidelines should provide a basic framework for the management of most patients.

Whatever screening regimen is followed, one key to early recognition of toxicity and the avoidance of liability is patient counseling to emphasize the risk of toxicity and need for periodic examinations. These admonitions should be noted carefully in the record. Patients should understand that screening can recognize toxicity early and minimize visual loss, but cannot necessarily prevent all toxicity or guarantee there will be no visual loss. Screening seeks to recognize the earliest hints of functional or anatomic change, before the toxic damage is well developed. A second key to proper management is awareness of the importance of duration of use (cumulative dose).

Chloroquine and Hydroxychloroquine Toxicity

The mechanism of CQ and HCQ toxicity is not well understood. These drugs have acute effects on the metabolism of retinal cells, including the photoreceptors, but it is not clear whether these short-term metabolic effects are the cause of the slow and chronic damage that characterizes the clinical state of toxicity. Both agents bind to melanin in the retinal pigment epithelium (RPE), and this binding may serve to concentrate the agents and contribute to, or prolong, their toxic effects. However, no anatomic features of the RPE layer correlate with the macular bull's-eye pattern seen in the later stages of CQ and HCQ toxicity. One could also argue that melanin binding serves as a mechanism for removing toxic agents from intracellular sites of damage. The macular localization of the disease suggests that light absorption or cone metabolism may play a role, but these are speculations.

The clinical picture of CQ and HCQ toxicity is characterized classically by bilateral bull's-eye maculopathy, a ring of RPE depigmentation that spares a foveal island. Although visual acuity may be excellent, perceptive patients will notice paracentral scotomas associated with reading difficulties. Because subtle functional loss in the paracentral retina may occur before biomicroscopic changes in the RPE, careful testing of the paracentral retina with threshold visual

Table 1. Factors Increasing the Risk of Chloroquine and Hydroxychloroquine Retinopathy

Duration of use	>5 yrs
Cumulative dose	
HCQ	>1000 g (total)
CQ	>460 g (total)
Daily dose	
HCQ	>400 mg/day (>6.5 mg/kg ideal body weight for short individuals)
CQ	>250 mg/day (>3.0 mg/kg ideal body weight for short individuals)
Age	Elderly
Systemic disease	Kidney or liver dysfunction
Ocular disease	Retinal disease or maculopathy

CQ = chloroquine; HCQ = hydroxychloroquine.

fields or mfERG is the key to early detection of toxicity.⁶⁻⁸ If drug exposure continues, the area of functional disturbance and RPE atrophy will spread into the fovea, with a resultant loss of visual acuity, and eventually the degeneration may spread over the entire fundus. Advanced cases show widespread RPE and retinal atrophy with loss of visual acuity, peripheral vision, and night vision.

There may be a stage of very early functional loss when cessation of the drug will allow a reversal of the toxicity. However, cases with visible bull's-eye maculopathy do not show significant clinical recovery, and there is often continuing depigmentation and functional loss for 1 year or more after the drug has been stopped. The point of screening is to catch toxicity early enough in its development so the maculopathy can stabilize without any serious loss of visual acuity. It is not clear whether the late progression of damage results from a continued reservoir of the drug or a gradual decompensation of cells that were injured during the period of drug exposure. Clearance of these drugs from the body can take many months after they are stopped.

Chloroquine, and to a smaller degree HCQ, can cause whorl-like intraepithelial deposits in the cornea (verticillata). Although these corneal changes are not a direct marker for retinal damage, they do suggest drug retention and reinforce the need for regular screening.

Risk of Toxicity

Although no one disputes the potential seriousness of retinal toxicity from these drugs, the rationale (cost-effectiveness) for prospective screening depends on the prevalence of toxicity and the ability to prevent adverse clinical effects (Table 1). The risk of toxicity from CQ and HCQ is low, even after many years of use, but there were little prevalence data in older literature. The largest series of rheumatologic patients showed only 1 case of clear toxicity among 1207 users.⁹ A smaller ophthalmologic cohort showed less than 0.5% toxicity.⁴ A new study of approximately 4000 unrelated patients found a higher prevalence of HCQ toxicity (6.8/1000 users), but the prevalence was dependent on the duration of use (cumulative dose). The prevalence was only a few per 1000 within the first 5 years of use and

increased sharply after 5 to 7 years to approximately 1%.¹⁰ The risk to patients after 15 to 20 years of exposure was even higher. Another study, based on referral patients, found a 4-fold increase in toxicity among patients taking HCQ for more than 7 years.¹¹ This document takes the assumption that screening is justified as the risk of toxicity approaches 1%, which suggests that annual screening should be performed on all patients who exceed 5 years of exposure. However, earlier, more frequent screening may be indicated where there are unusual risk factors or a suspicion of early toxicity.

Risk Factors

Dosage Factors

Cumulative Dose. Most reported cases of toxicity have occurred in patients using the drug for more than 7 years or with a cumulative dose that exceeds 1000 g HCQ (or 460 g CQ) (Table 1). The number of reported cases of likely toxicity begins to increase sharply after approximately 5 years of use.¹⁰ A cumulative dose of 1000 g HCQ is reached in 7 years with a typical daily dose of 400 mg, and a cumulative dose of 460 g CQ is reached in 5 years with a typical daily dose of 250 mg.

Daily Dose. Older literature (and the original version of this document⁵) emphasized an association of toxicity with daily HCQ doses >6.5 mg/kg of body weight (equivalent to CQ >3.0 mg/kg). However, recent surveys of patients taking HCQ^{10,12,13} found that the risk of toxicity depended on cumulative exposure and was independent of daily dose or dose/kilogram. However, this result must be put into context. Most subjects in these surveys simply received the “typical” dose of 400 mg (2 tablets) of HCQ or 250 mg (1 tablet) of CQ regardless of weight, which in fact complies with the older dose guidelines except for short individuals. There were too few subjects receiving high or unusual doses to evaluate upper limits.

We caution that overdosage of these drugs is dangerous. A significant percentage of the reported HCQ toxic cases have been associated with daily doses >6.5 mg/kg, which hasten the accumulation of drug and may enhance the rate or degree of tissue damage. Overdosage is most likely to occur with individuals of short stature for whom the “typical” dose is too high. We suggest that daily doses be limited to 400 mg HCQ or 250 mg CQ, and that lower doses (in the range of 6.5 mg/kg HCQ or 3.0 mg/kg CQ, calculated on the basis of ideal body weight) be used for individuals who are of short stature. Chloroquine and HCQ are not retained in fatty tissues, so patients who are obese could be seriously overdosed if medicated on the basis of weight alone. Obese individuals should be dosed on the basis of height, which allows estimation of an asthenic or “ideal” body weight. Because CQ and HCQ have a long clearance time in the blood, and clinical effects build up slowly, intermediate dosing can be achieved easily by varying the daily intake. For example, 300 mg daily results from taking 200 mg and 400 mg on alternate days.

A recent study reported that the clinical effectiveness of HCQ in preventing recurrences of systemic lupus erythematosus correlates with blood concentrations >1000 ng/ml.¹⁴ Patients in this study used 400 mg daily, and their blood levels did not correlate with the dose/kilogram. For patients who are dosed on the basis of blood concentration, risk should be assessed by cumulative dose.

Renal or Liver Disease. Chloroquine and HCQ are cleared by both the kidney and the liver. Disease of either organ system can decrease the effective rate of drug removal, which in effect increases the blood level.

Other Factors

Age. Elderly patients may be at higher risk, given the possibility that age-related changes within the retina could increase susceptibility to toxic damage (although this is not proven). The assessment of toxicity is also more difficult in the elderly because the diffuse loss of fundus pigmentation with age makes bull’s-eye depigmentation hard to recognize.

Retinal and Macular Disease. Patients with underlying retinal disease may be at higher risk for toxicity, although there are no specific data to show that diseased retinas are more susceptible. There is an additional concern with those who have maculopathy because the earliest findings of CQ and HCQ toxicity are subtle functional loss or pigmentary alterations in the parafoveal region. Maculopathy is considered by many to be a contraindication for CQ or HCQ use because it masks these signs of early toxicity and renders screening less effective or impossible.

Genetic Factors. There have been suggestions about genetic predisposition to toxicity from these drugs,¹⁵ but no confirmatory studies have been published.

Clinical Assessment Tools

Screening Tests: Subjective

Ophthalmologic Examination. A thorough ophthalmologic examination is important for documentation of visual status and ocular findings. Visual acuity should be measured with best correction in place. The corneal epithelium should be examined to detect verticillata. A dilated fundus examination should be performed and the macula assessed for drusen or pigmentary changes that might be confused with toxicity, with attention to the earliest signs of bull’s-eye maculopathy. Pigmentation or atrophy in the periphery and the status of the retinal vasculature should be noted. Although fundus examination is important for documentation and the recognition of unrelated retinal pathology, it should not be considered a screening tool. Visible bull’s-eye retinopathy indicates that toxicity has persisted long enough to cause RPE degeneration, and is a relatively late finding.

Automated Threshold Visual Fields. Parafoveal loss of visual sensitivity may appear before changes are seen on fundus examination. Automated threshold visual field testing with a white 10-2 pattern (i.e., testing with white targets within 10 degrees of the fovea) gives high resolution within the macular region. Larger test patterns (e.g., 24-2 or 30-2) do not have a sufficient number of central targets for effective

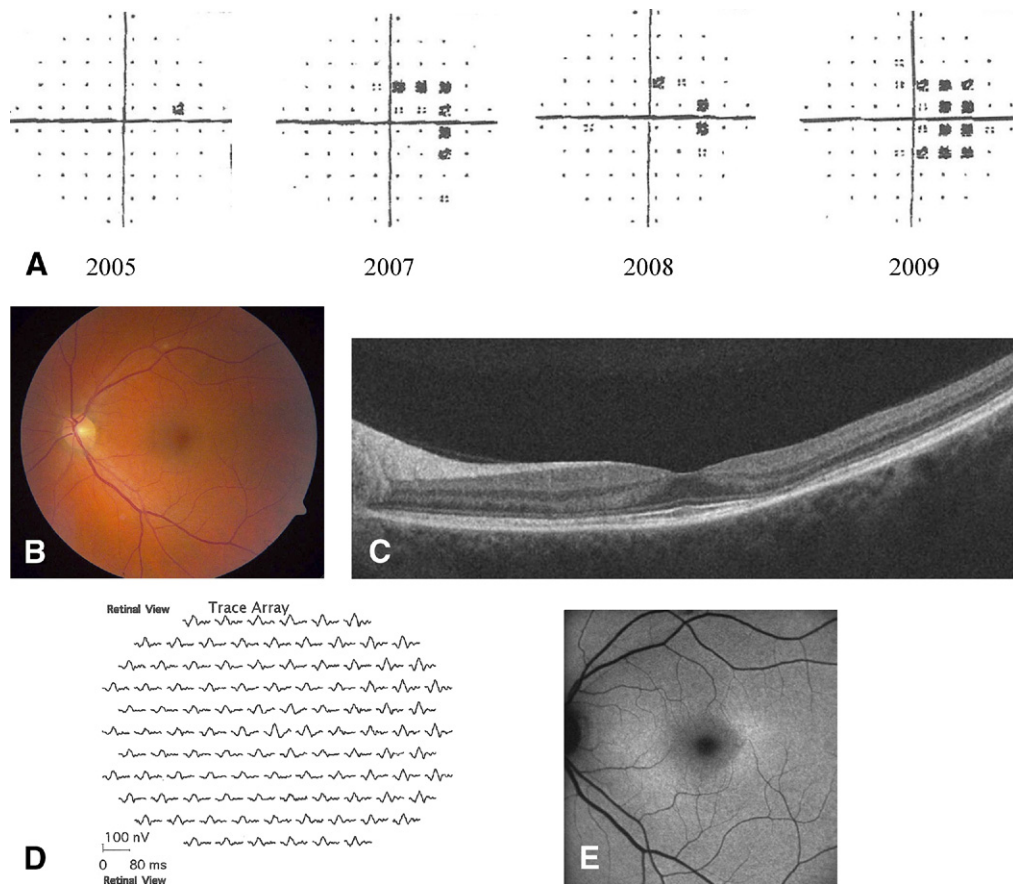


Figure 1. Case of HCQ toxicity illustrating the relative sensitivity of different screening tests. Spectral domain-OCT, mfERG, and FAF showed damage both nasally and temporally, although field loss was only nasal. The patient is a 48-year-old woman who took 400 mg HCQ/day (8 mg/kg) for most of 25 years. No visual symptoms. All images are from the left eye in 2009, except for visual fields. **A**, Automated 10-2 visual fields from 2005 to 2009. From 2005 to 2008, the abnormalities were judged of no clinical significance. In 2009, nasal parafoveal scotomas were obvious, and she was referred to a specialist. **B**, Fundus photograph (and retinal examination) shows no bull's-eye retinopathy. **C**, Spectral domain-OCT shows parafoveal thinning of photoreceptor layers and loss of the inner-/outer-segment line. **D**, Multifocal ERG trace array shows decreased parafoveal waveform amplitudes (confirmed by ring ratio analysis of amplitudes in the parafovea relative to other regions). **E**, Fundus autofluorescence is increased in a bull's-eye pattern.

tive screening. Attention should be given to the “pattern deviation display” of visual fields, because it can filter out effects of cataract and media opacities in causing visual field loss. This procedure is widely available, and results from different locations are comparable because they are standardized.

There are important caveats if 10-2 fields are to be effective for screening. There are many instances in which CQ or HCQ retinopathy was unrecognized for years because field changes were dismissed as “nonspecific” until the damage was severe (Fig 1). Thus, visual fields should always be repeated promptly when central or parafoveal changes are observed to determine whether the changes are reproducible. This is important, even if the changes are subtle or of uncertain significance on the basis of attention, fatigue, refraction, learning effects, and so forth. The finding of any reproducibly depressed central or parafoveal spots can be indicative of early toxicity (Fig 1) and should trigger further testing with the objective procedures listed next. Advanced toxicity will typically show a well-developed paracentral scotoma (with or

without central sensitivity loss), but the goal of screening is to recognize toxicity *before* such a severe degree of visual field loss occurs. Amsler grid testing is *not* equivalent to threshold visual field testing and is greatly dependent on patient understanding and compliance. It should not be used for screening (see below).

Screening Tests: Objective

A number of tests can objectively document anatomic or functional damage from CQ or HCQ, and these can be extremely useful in verifying and quantifying toxicity. However, there are limited studies comparing sensitivity and specificity of these procedures relative to automated visual field testing,^{16–18} and the optimal test or combination of tests is still unknown. At present, some of these tests are only available in subspecialty offices, but screening physicians need to be aware of these testing modalities and should use at least one of these objective tests if readily available. Patients should be referred to specialty centers for

confirmatory tests when there are unusual risks or suspicious findings.

Spectral Domain-Optical Coherence Tomography. Optical coherence tomography shows a cross-section of retinal layers in the macula. Newer high-resolution instruments (SD or Fourier domain OCT) can show localized thinning of the retinal layers in the parafoveal region and confirm toxicity. It should be noted that these changes cannot be appreciated well on the older time-domain OCT instruments. Loss of the inner-/outer-segment line may be an early objective sign of parafoveal damage. Further work is needed to evaluate the sensitivity of SD-OCT relative to visual fields or mfERG, but a number of cases (Fig 1) have shown prominent SD-OCT changes before visual field loss.^{16,19–22} SD-OCT testing is rapid and the equipment is available in many offices and clinics.

Fundus Autofluorescence. Autofluorescence imaging may reveal subtle RPE defects with reduced autofluorescence or show areas of early photoreceptor damage (which appear as increased autofluorescence from an accumulation of outer segment debris).^{16,20} It has the advantage over fluorescein angiography of being faster and not requiring dye injection. Some cases have demonstrated FAF abnormalities before visual field loss (Fig 1), but the sensitivity of FAF relative to other tests is still being evaluated. The equipment is available in specialty offices and on some newer fundus camera systems.

Multifocal Electroretinogram. The mfERG generates local ERG responses topographically across the posterior pole and can objectively document localized paracentral ERG depression in early CQ and HCQ retinopathy.^{6,11,12,17–20} There is evidence that the mfERG may be more sensitive to early paracentral functional loss than the white 10-2 field (Fig 1). Multifocal ERG testing is performed in many large clinical centers and some specialty offices.

Tests Not Recommended for Screening

Fundus Photography. Photography documents the fundus appearance against which later changes can be compared, and it may detect the presence of retinopathy from other causes. It is strongly recommended at baseline, and periodically for higher-risk patients or when any changes are noted in the fundus. However, it is not sensitive enough for screening because recognizable bull's-eye retinopathy signifies relatively advanced CQ or HCQ toxicity.

Time-Domain Optical Coherence Tomography. The resolution of time-domain OCT instruments is not sufficient to detect early toxic changes.

Fluorescein Angiography. Fluorescein angiography can recognize subtle RPE defects, but it has not proven to be more sensitive than tests of functional loss or noninvasive retinal imaging.

Full-field Electroretinogram. The full-field ERG is a global test of retinal function and will only show abnormalities in very late CQ or HCQ toxicity. It is not sensitive to functional changes localized to the macula and, thus, has little role in screening for early toxicity. It is useful, how-

ever, in the evaluation of patients with manifest toxicity to judge how severe or widespread the damage may be.

Amsler Grid. The initial American Academy of Ophthalmology Guidelines⁵ proposed the use of the Amsler grid as an alternative to automated 10-2 testing on the basis of older literature. However, Amsler grid results depend heavily on patient understanding and alertness, and on the ability to recognize rather slow subtle changes in paracentral sensitivity (in contrast with the more rapid central visual changes of neovascular macular degeneration). Therefore, Amsler grid testing is not consistent enough in general use for reliable screening. Some physicians may choose to use it as a supplemental test, but it should not be used in lieu of annual 10-2 testing.

Color Vision Testing. Color vision testing has been reported to be abnormal in early CQ or HCQ toxicity, but there is disagreement about its sensitivity or specificity. Color errors are not specific for CQ and HCQ toxicity, and may occur in other macular or optic nerve diseases. We do not consider color testing to be a routine component of screening for these drugs, although some practitioners may choose to use it as a supplemental test. If color testing is performed, it is important to obtain a baseline to rule out any underlying abnormalities (including congenital red-green color deficiency in men).

Electro-oculogram. Some older reports suggested that the electro-oculogram (EOG) may be an early indicator of toxicity, but other reports have documented normal EOG results in patients with CQ or HCQ toxicity. Overall evidence has not validated the EOG as a reliable screening test.

Screening Recommendations

It is important to be aware of risk factors (including daily dose, cumulative dose, and underlying medical conditions) that would indicate a need for special diligence (Table 2). Practitioners need to remember that there are no established criteria for diagnosing drug toxicity before a stage where some minor permanent visual loss is likely. Screening is aimed primarily at early detection of toxicity to avoid serious visual loss. The goal is to recognize early signs of paracentral field loss, or paracentral tissue damage, before the development of visible bull's-eye retinopathy. The balance of frequency and extent of screening, relative to cost and legal considerations, is a judgment that individual physicians and health plans must make in light of the risk status of individual patients.

Reports in older literature on toxicity focused on daily dose/kilogram, whereas newer literature emphasizes cumulative dose as the most critical factor. However, the literature does contain individual cases with toxicity at low cumulative doses or within the first few years of use. After the baseline evaluation, screening for toxicity should be initiated no later than 5 years after starting the medication (when the risk increases toward 1%). The patients receiving CQ or HCQ and their physicians must understand that rare cases of toxicity do occur earlier.

Table 2. Chloroquine and Hydroxychloroquine Screening Procedures

Timeline	Baseline examination within first year of use Annual screening after 5 yrs of use
Recommended Screening Procedures	
Ocular examination	Dilated retinal examinations are important for detection of associated retinal disorders, but should <i>not</i> be relied on for screening (low sensitivity).
Automated visual field	White 10-2 threshold testing. Interpret with a low threshold for abnormality, and retest if abnormalities appear.
In addition, if available, perform one or more of the following objective tests	
SD-OCT	Rapid test that can be done routinely; can show abnormalities very early, even before field loss
mfERG	Valuable for evaluation of suspicious or unreliable visual field loss; may show damage earlier than visual field testing
FAF	May validate other measures of toxicity; can show abnormalities earlier than field loss
Not Recommended for Screening	
Fundus photography	Recommended for documentation, especially at baseline, but not sensitive for screening
Time-domain OCT	Insufficient resolution for screening
Fluorescein angiography	Use only if corroboration of pigmentary changes is needed
Full-field ERG	Important for evaluation of established toxicity, but not for screening
Amsler grid	Use only as adjunct test
Color testing	Use only as adjunct test
EOG	Questionable sensitivity
EOG = electro-oculogram; FAF = fundus autofluorescence; mfERG = multifocal electroretinogram; SD-OCT = spectral domain optical coherence tomography.	

Baseline Examination

We strongly advise that all patients beginning CQ or HCQ therapy have a baseline examination within the first year of starting the drug to document any complicating ocular conditions and to establish a record of the fundus appearance and functional status. This examination also allows for counseling about risk and the importance of regular examinations. This counseling should be documented in the medical record.

Every baseline examination (Table 2) should include careful biomicroscopy, automated threshold testing with a white 10-2 protocol, and, where available, testing with one or more of the recommended objective tests: SD-OCT, mfERG, or FAF. Baseline fundus photography may be useful to document the appearance relative to any later changes and the presence of maculopathy that may be a contraindication to initiating therapy (see "Risk Factors"). If these drugs are to be used in a patient with underlying maculopathy or who is otherwise at unusual risk, it is especially important that a baseline be established with several tests so that early changes related to toxicity can be recognized. For higher-risk patients, annual screening should begin immediately (i.e., without a 5-year delay).

Annual Screening

Annual screening should be performed after 5 years of use in all patients (and from the initiation of therapy for patients with maculopathy or unusual risk factors), as described in Table 1. It must be emphasized that these are minimal screening guidelines, and some physicians may choose to screen earlier or more often, or expand the battery of tests, to achieve greater diligence with patients at higher degrees of risk. We continue to recommend automated 10-2 fields because they are readily available and demonstrate the degree of functional loss directly to patients. However, as noted above and shown in Figure 1, fields may be less sensitive than objective procedures. Thus, we also recommend that, if possible, at least one of the listed objective procedures also be a component of both baseline and annual screening examinations. In particular, SD-OCT is widely available, sensitive, and easy to perform as a routine screening procedure.^{16,22} The mfERG is more complex to perform, but it provides sensitive and objective documentation of visual function. Fundus autofluorescence also can be sensitive. We recognize that these objective procedures are not readily available in many offices, and practitioners will need to use judgment as to the choice and frequency of procedures, weighing risk, cost, time, and so forth. Even the periodic addition of objective tests will strengthen a screening regimen based primarily on visual field testing. Clinicians should keep in mind that patients should also follow the American Academy of Ophthalmology Preferred Practice Guidelines for general ophthalmologic exams²³ relative to their age or to other ocular or systemic risk factors.

It is important to counsel patients at every visit about relative risk and the importance of regular screening to minimize the risk of serious visual loss. Patients should be instructed to return ahead of scheduled visits if there are any new visual symptoms (especially reduced visual sensitivity, reading difficulty, or blind spots), new retinal disease, or changes in systemic status, such as major weight loss or kidney or liver disease.

Retinal Toxicity

No medical therapy has proven effective in CQ or HCQ toxicity other than cessation of the drug, which is always recommended (if medically acceptable) when toxicity is suspected. However, CQ or HCQ is, for many patients, an effective and safe way to control a serious systemic disease, and cessation carries some risk of worsening that disease or of having to add other drugs (e.g., corticosteroids and anti-metabolites) that have their own side effects. Thus, decisions to change medication should be made in conjunction with the internist or rheumatologist who is managing the patient, and with careful disclosure to the patient of the systemic and ophthalmologic implications. Chloroquine and HCQ clear very slowly from the body, so the medical effects of any decision to stop the drug may not manifest for 3 to 6 months. Visual function may continue to deteriorate slowly even after the drug is stopped, and it is unclear how much recovery is possible even from the earliest recognizable stages of toxicity.

Suggestive Findings

If a patient returns with suggestive visual symptoms or any of the screening examinations raise a question of early toxicity (e.g., new paracentral visual field defects), then more careful evaluation is needed. Subjective tests, such as automated fields, should be repeated to verify possible abnormalities. If not already obtained, further procedures such as mfERG, SD-OCT, or FAF should be performed (by referral if necessary) to corroborate the findings.

Possible Toxicity

Patients with “possible” early toxicity may elect to stop the drug if it is not considered medically important or to be followed at 3- to 6-month intervals until there is further evidence to rule toxicity in or out. There is no firm definition of “early” toxicity, so that subtle changes (especially if parafoveal) in visual field sensitivity, macular pigmentation, or any of the objective screening tests (SD-OCT, mfERG, FAF) should be taken seriously. If such changes occur, the tests should be repeated for verification or verified with other procedures. However, mild and nonspecific changes can appear in all tests for reasons other than toxicity (including cataract, early macular degeneration, and testing variation of the visual field and mfERG), and a relationship to CQ or HCQ is difficult to confirm without evidence of paracentral functional or structural loss.

Probable Toxicity

Patients with “probable” or clearly evident toxicity (e.g., bilateral bull’s-eye scotoma, bilateral paracentral mfERG loss, bilateral bull’s-eye depigmentation, or parafoveal abnormalities on FAF, SD-OCT, or fluorescein angiography) should have the drug stopped immediately if at all possible, because stoppage will minimize the progression of visual loss. If the medication is thought to be critical to management of the underlying disease, there should be close (e.g., every 3 months) follow-up to assess progression, and it should be documented that the patient accepts a risk of permanent visual loss.

Patients with probable toxicity may benefit from a full-field ERG to evaluate the degree to which retinal damage may extend beyond the macula. Further use of the drugs has a high likelihood of damaging central (reading) vision and eventually peripheral vision. Patients who are losing visual acuity or who show a reduction in the full-field ERG should not continue these drugs unless needed so desperately for quality of life that severe loss of vision or blindness is acceptable as an outcome. When the drugs are discontinued because of suspicion of toxicity, a reevaluation is recommended 3 months later and then annually until the findings are stable.

References

- Easterbrook M. Long term case of antimalarial toxicity after cessation of treatment. *Can J Ophthalmol* 1992;27:237–9.
- Elman A, Gullberg R, Nilsson E, et al. Chloroquine retinopathy in patients with rheumatoid arthritis. *Scand J Rheumatol* 1976;5:161–6.
- Mavrikakis M, Papazoglou S, Sfikakis PP, et al. Retinal toxicity in long term hydroxychloroquine treatment. *Ann Rheum Dis* 1996;55:187–9.
- Mavrikakis I, Sfikakis PP, Mavrikakis E, et al. The incidence of irreversible retinal toxicity in patients treated with hydroxychloroquine: a reappraisal. *Ophthalmology* 2003;110:1321–6.
- Marmor MF, Carr RE, Easterbook M, et al for the American Academy of Ophthalmology. Recommendations on screening for chloroquine and hydroxychloroquine retinopathy. *Ophthalmology* 2002;109:1377–82.
- Lai TY, Chan WM, Li H, et al. Multifocal electroretinographic changes in patients receiving hydroxychloroquine therapy. *Am J Ophthalmol* 2005;140:794–807.
- Elder M, Rahman AM, McLay J. Early paracentral visual field loss in patients taking hydroxychloroquine. *Arch Ophthalmol* 2006;124:1729–33.
- Tzekov RT, Serrato A, Marmor MF. ERG findings in patients using hydroxychloroquine. *Doc Ophthalmol* 2004;10:87–97.
- Levy GD, Munz SJ, Paschal J, et al. Incidence of hydroxychloroquine retinopathy in a large multicenter outpatient practice. *Arthritis Rheum* 1997;40:1482–6.
- Wolfe F, Marmor MF. Rates and predictors of hydroxychloroquine retinal toxicity in patients with rheumatoid arthritis and systemic lupus erythematosus. *Arthritis Care Res (Hoboken)* 2010;62:775–84.
- Lyons JS, Severns ML. Detection of early hydroxychloroquine retinal toxicity enhanced by ring ratio analysis of multifocal electroretinography. *Am J Ophthalmol* 2007;143:801–9.
- Lyons JS, Severns ML. Using multifocal ERG ring ratios to detect and follow Plaquenil retinal toxicity: a review: Review of mfERG ring ratios in Plaquenil toxicity. *Doc Ophthalmol* 2009;118:29–36.
- Ingster-Moati I, Crochet M, Manchon E, et al. Analysis of 925 patients on long-term hydroxychloroquine or chloroquine treatment: results of ophthalmological screening [in French]. *J Fr Ophtalmol* 2004;27:367–73.
- Costedoat-Chalumeau N, Amoura Z, Hulot JS, et al. Low blood concentration of hydroxychloroquine is a marker for and predictor of disease exacerbations in patients with systemic lupus erythematosus. *Arthritis Rheum* 2006;54:3284–90.
- Shroyer NF, Lewis RA, Lupski JR. Analysis of the ABCR (ABCA4) gene in 4-aminoquinoline retinopathy: is retinal toxicity by chloroquine and hydroxychloroquine related to Stargardt disease? *Am J Ophthalmol* 2001;131:761–6.
- Kellner S, Weinitz S, Kellner U. Spectral domain optical coherence tomography detects early stages of chloroquine retinopathy similar to multifocal electroretinography, fundus autofluorescence and near-infrared autofluorescence. *Br J Ophthalmol* 2009;93:1444–7.
- Lai TY, Ngai JW, Chan WM, et al. Visual field and multifocal electroretinography and their correlations in patients on hydroxychloroquine therapy. *Doc Ophthalmol* 2006;112:177–87.
- Maturi RK, Yu M, Weleber RG. Multifocal electroretinographic evaluation of long-term hydroxychloroquine users. *Arch Ophthalmol* 2004;122:973–81.
- Pasadhika S, Fishman GA. Effects of chronic exposure to hydroxychloroquine or chloroquine on inner retinal structures. 2010;24:340–6. Epub 2009 Apr 17.
- Kellner U, Renner AB, Tillack H. Fundus autofluorescence and mfERG for early detection of retinal alterations in patients using chloroquine/hydroxychloroquine. *Invest Ophthalmol Vis Sci* 2006;47:3531–8.
- Rodriguez-Padilla JA, Hedges TR III, Monson B, et al. High-speed ultra-high-resolution optical coherence tomography findings in hydroxychloroquine retinopathy. *Arch Ophthalmol* 2007;125:775–80.

22. Stepien KE, Han DP, Schell J, et al. Spectral-domain optical coherence tomography and adaptive optics may detect hydroxychloroquine retinal toxicity before symptomatic vision loss. *Trans Am Ophthalmol Soc* 2009;107:28–34.
23. American Academy of Ophthalmology. *Comprehensive Adult Medical Eye Evaluation Preferred Practice Pattern*. San Francisco, American Academy of Ophthalmology, 2010. Available at: www.aao.org/PPP. Accessed December 9, 2010.

Footnotes and Financial Disclosures

Originally received: March 25, 2010.

Final revision: November 15, 2010.

Accepted: November 15, 2010. Manuscript no. 2010-451.

¹ Eye Institute at Stanford, Stanford University, Palo Alto, California.

² AugenZentrum Siegburg, Siegburg, Germany, and RetinalScience, Bonn, Germany.

³ Department of Ophthalmology and Visual Sciences, The Chinese University of Hong Kong, Hong Kong.

⁴ Georgetown University/Washington National Eye Center, Washington, DC.

⁵ The University of Illinois Eye and Ear Infirmary, Chicago, Illinois.

Financial Disclosure(s):

The author(s) have made the following disclosure(s) for the years 2009 and 2010: Michael Marmor, consultant/advisor, CoMentis, Inc., Eli Lilly and Co., Merck & Co., Inc., Basilea Pharmaceutica, Bayer Corp USA, Johnson & Johnson. Ulrich Kellner, none. Timothy Y. Y. Lai, consultant/advisor, grant support, Novartis Pharmaceuticals; Jonathan S. Lyons, none. William F. Mieler, consultant/advisor, Alcon Laboratories, Allergan, Inc., Genentech, Inc.

Correspondence:

Flora Lum, MD, American Academy of Ophthalmology, Department of Quality of Care and Knowledge Base Development, 655 Beach Street, San Francisco, CA 94109-1336. E-mail: flum@aao.org.