

High IOP in Traumatic Hyphema

These patients require close observation and medical treatment, but surgery may become necessary to prevent serious complications such as secondary glaucoma.

BY KEVIN KAPLOWITZ, MD, AND NILS LOEWEN, MD, PhD

Blunt force is the most common cause of traumatic hyphema that stretches the globe and can tear the highly vascularized iris or ciliary body.¹ Any hyphema (Figure 1) therefore warrants a thorough yet careful examination for a ruptured globe or other intraocular injury (Figure 2). Medical treatment is required, but surgical intervention can later be indicated.

THE EXAMINATION

The physician should investigate the exact cause of the hyphema, including details of the trauma, history of sickle cell anemia, and coagulopathy. The clinician should also review any medications and supplements (eg, ginkgo extracts, vitamin E) the patient is using that may have anti-coagulative properties.

Gonioscopy with a lens that creates suction (eg, the three-mirror Goldmann lens) or deforms the anterior chamber should be deferred at the initial visit to reduce the risk of further bleeding. Examiners experienced with Posner and Zeiss-style lenses (Carl Zeiss Meditec, Inc.) feel that they touch the cornea only lightly and can provide helpful, early information about the site and extent of damage. For the reason stated earlier, B-scan ultrasonography must be used with caution. Retinal detachments can often be visualized with modern computed tomographic imaging, especially when hemorrhagic subretinal fluid is present.²

FOLLOW-UP

Because a rebleed in hyphema can often be more significant than the initial bleed, patients require close observation, especially from days 2 to 5 after the trauma. Although, historically, patients were admitted to the hospital for bed rest and close monitoring, a recent retrospective study with historic controls of 154 patients by Shiuey and Lucarelli found comparable outcomes with outpatient management³; rebleeding rates were 4.5% in the outpatient group versus 5% in the inpatient group, and

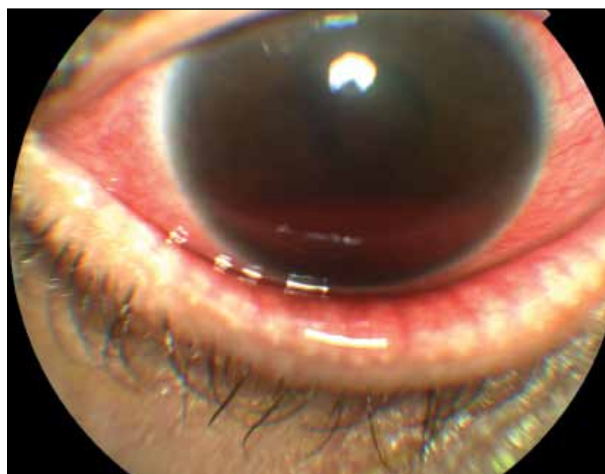

Figure 1. Traumatic hyphema.

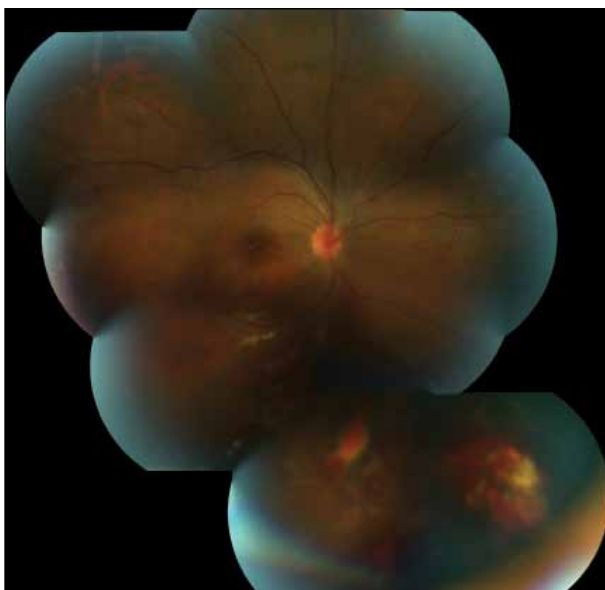


Figure 2. More extensive intraocular damage with a traumatic retinal detachment.

96% of the outpatients retained a visual acuity of 20/30 or better. The indications for admission stated by the study's authors included rebleeds, uncontrolled IOP, total hyphema, and possibly sickle cell anemia. Outpatients need to be counseled to avoid activity, keep the head of their bed elevated, wear a clear shield (that allows recognition of a rebleed) over the eye, and avoid anticoagulants.

TREATMENT

The standard initial treatment of hyphema is medical. The goal is to reduce the bleeding and acutely control the IOP with pressure-lowering drops (eg, β -blockers and α -2 agonists). Carbonic anhydrase inhibitors should be avoided in patients with sickle cell anemia, and the use of hyperosmotics should be limited.⁴ Although there is no direct evidence that topical dorzolamide causes enough acidosis to induce significant sickling, no study has demonstrated the agent's safety in these cases, either. Pilocarpine can increase the risk of pupillary block in an eye with a large clot, and the drug can worsen inflammation, as can prostaglandin analogues. Topical prednisolone decreases inflammation, and cycloplegics immobilize the iris and ciliary body, thereby reducing further bleeding and increasing patients' comfort. Randomized controlled trials of aminocaproic acid concluded that it does not significantly reduce the incidence of rebleeding.⁵ A recent Cochrane review showed that antifibrinolytics may decrease the amount of rebleeding but at the cost of prolonging a clot's presence in the anterior chamber.⁶

Surgical intervention is sometimes necessary to avoid the more serious complications of glaucoma and corneal blood staining. The classic indications for surgery to avoid glaucomatous damage to the optic nerve in the acute phase of hyphema were derived from a prospective, partly randomized study.⁷ Surgical intervention is advised if the IOP remains above 50 mm Hg for 5 days or higher than 35 mm Hg for 7 days or if the hyphema does not resolve within 9 days.⁸ No surgery should be performed earlier than 4 days to allow sufficient time for clotting. Because patients with the sickle cell trait already have increased sensitivity to poor perfusion of the optic nerve head, anterior chamber washout has been suggested for these individuals if they have an IOP above 25 mm Hg for 24 hours or repeatedly have an IOP over 30 mm Hg.⁴

SECONDARY GLAUCOMA

Delayed glaucomatous optic neuropathy after hyphema has multiple mechanisms that lead to secondary glaucoma. In Read and Goldberg's study, the motivation for surgery for a hyphema that failed to resolve after 9 days was to avoid the formation of peripheral anterior synechiae (PAS) that

would predispose the patient to secondary angle-closure glaucoma. No notable PAS formation was seen in the eyes of any patient until the hyphema had lasted 8 days. An inflammatory response can lead to the formation of PAS and the risk of pupillary block. In the same study, gonioscopy revealed angle recession in 87% of eyes.⁷


A third mechanism of glaucoma, in addition to PAS and angle recession, is hemolytic glaucoma, a secondary form of open-angle glaucoma that occurs days to weeks after hyphema, as the red blood cells are phagocytosed and/or lysed and subsequently clog the trabecular meshwork.⁹ These cells may be seen as a reddish discoloration of the trabecular meshwork. Like the original hemorrhage, the clot of red blood cells will often resolve with medical treatment, but anterior chamber washout may be necessary if the IOP cannot be controlled. If the trauma created a cyclodialysis cleft, spontaneous closure can also lead to a late increase in IOP.

CONCLUSION

Physicians should treat traumatic hyphema medically and pay special attention to the IOP in patients with sickle cell anemia. There are established indications for surgical intervention, which is only performed to prevent the acute complications. ■

Kevin Kaplowitz, MD, is a clinical glaucoma fellow in the Department of Ophthalmology & Visual Science at Yale School of Medicine in New Haven, Connecticut. He acknowledged no financial interest in the product or company mentioned herein. Dr. Kaplowitz may be reached at kevin.kaplowitz@yale.edu.

Nils A. Loewen, MD, PhD, is an assistant professor of ophthalmology and visual science and the director of the glaucoma section at Yale University School of Medicine in New Haven, Connecticut. He acknowledged no financial interest in the product or company mentioned herein. Dr. Loewen may be reached at (203) 533-1004; nils.loewen@yale.edu.



1. Sankar PS, Chen TC, Grosskreutz CL, Pasquale LR. Traumatic hyphema. *Int Ophthalmol Clin.* 2002;42(3):57-68.
2. Lane JJ, Watson RE, Witte RJ, McCannel CA. Retinal detachment: imaging of surgical treatments and complications. *Radiographics.* 2003;23(4):983-994.
3. Shieue Y, Lucarelli MJ. Traumatic hyphema: outcomes of outpatient management. *Ophthalmology.* 1998;105(5):851-855.
4. Deutsch TA, Weinreb RN, Goldberg MF. Indications for surgical management of hyphema in patients with sickle cell trait. *Arch Ophthalmol.* 1984;102(4):566-569.
5. Rahmani B, Jahadi HR. Comparison of tranexamic acid and prednisolone in the treatment of traumatic hyphema. A randomized clinical trial. *Ophthalmology.* 1999;106(2):375-379.
6. Gharalbeh A, Savage HJ, Scherer RW, et al. Medical interventions for traumatic hyphema. *Cochrane Database Syst Rev.* 2011(1):CD005431.
7. Read JE, Goldberg MF. Blunt ocular trauma and hyphema. *Int Ophthalmol Clin.* 1974;14(4):57-97.
8. Read J. Traumatic hyphema: surgical vs medical management. *Ann Ophthalmol.* 1975;7(5):659-662,664-666,668-670.
9. De Leon-Ortega JE, Girkin CA. Ocular trauma-related glaucoma. *Ophthalmol Clin North Am.* 2002;15(2):215-223.