

### Acute Surgical Management

Surgical closure should proceed in a timely manner to decrease the risk of endophthalmitis, avoid tissue necrosis, and decrease patient discomfort. In a controlled operating room setting, using an operating microscope, the surgeon initially inspects the wound before proceeding with closure. Surgical goals include restoration of optimal visual function, restoration of normal anatomic relationships, and the prevention of glaucoma, amblyopia, infection, or the need for a secondary reconstructive surgical repair. To accomplish these goals, the ophthalmologist has a surgical plan that includes adequate preparation of the ocular surface, conservation of tissue, and minimization of iatrogenic trauma. However, the surgeon is also prepared to abandon any preconceived plan if events during the operation warrant a change.

### Corneal laceration repair

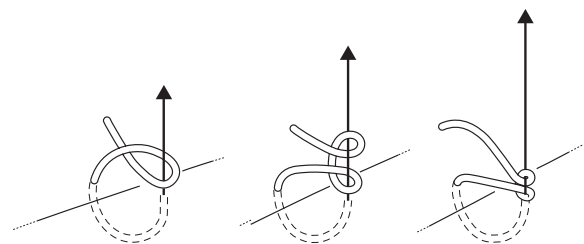
The challenge in repairing the lacerated cornea results from the inherent lack of elasticity of corneal tissue.<sup>40</sup> Unlike skin, the cornea will not stretch or replicate; hence the importance of the technique used for primary closure of a corneal wound. The micromechanical effects of a penetrating injury drastically alter corneal topography so that a number of different strategies are used to repair the cornea, minimize scarring, and restore the native corneal contour, thus minimizing both postoperative astigmatism and corneal scarring. Every corneal laceration is approached with these concepts in mind and the surgeon should neither preclude the future necessity of penetrating keratoplasty, nor allow this eventuality to decrease the care used in primary wound closure. Corneal wounds greater than 2 mm in size or those involving any tissue loss must be closed surgically. Careful inspection of the wound delineates any perpendicular versus shelved areas of the incision. Ideally, this is performed with the slit lamp (either preoperatively or intraoperatively), as the view under the operating microscope limits the three-dimensional examination of the cornea. The laceration is explored to remove any foreign materials, and cultures are performed of the wound and any foreign bodies.

The goal of corneal suturing is to make the wound watertight with minimal scarring and reconstruction of the native nonastigmatic corneal contour. Monofilament 10-0 nylon suture material on a fine spatula-designed microsurgical needle is used for corneal suturing. A bicurved needle with a small radius of curvature will aid in passing short, deep bites. A needle with a larger radius of curvature (160 degrees) will result in larger bites or longer passes, which are needed in the corneal periphery. Corneal sutures should be at 90% of stromal depth and of equal depth on both sides of the wound. Shallow sutures may cause internal wound gape, and asymmetric sutures result in wound override. Full-thickness sutures may allow the suture material to act as a conduit for microbial invasion and subsequent endophthalmitis formation. If at all possible, suture bites through the visual axis should be avoided. If necessary, one can minimize scarring in the visual axis by using short, small suture bites.

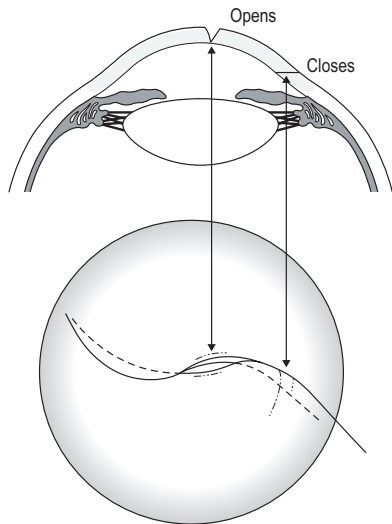
When passing corneal sutures, the tip of the needle is placed perpendicular to the corneal surface, and the needle is rotated through the wound along its curve, exiting perpendicular to the cut surface. If the wound is perpendicular, the pass through the opposite side of the wound should mirror the initial needle pass in depth and length. All knots are trimmed short and superficially buried in the stroma, on the side away from the visual axis. The ends of the buried knot are directed away from the surface to facilitate subsequent removal. The suture is tied using the smallest possible knot to facilitate burying of the surgical knot in the tissue. A granny-style slipknot allows for controlled closure of the wound and is small enough to be buried easily (Fig. 147.7).<sup>41,42</sup> The surgical knot is not be buried in the wound, to prevent posterior wound gape.

In closing any corneal wound, one must avoid tissue removal as this will result in the need for tight sutures that have a significant torque effect on the remaining tissue as the cornea is not elastic.<sup>43</sup> In a linear laceration, the surgeon inspects the corneal laceration for perpendicular versus shelved portions and closes the perpendicular areas first (Fig. 147.8). The shelved portions of the wound will then appose properly, requiring minimal suture tension. The perpendicular areas of the incision are closed first with interrupted sutures to reform the anterior chamber. This technique allows the shelved area of the incision to close spontaneously, requiring fewer sutures.<sup>44</sup> It is often difficult to judge the correct tension for initial sutures, so slipknots may be placed and then loosened or tightened after all sutures are in place. Peripheral compression sutures in the cornea periphery steepen the central cornea.

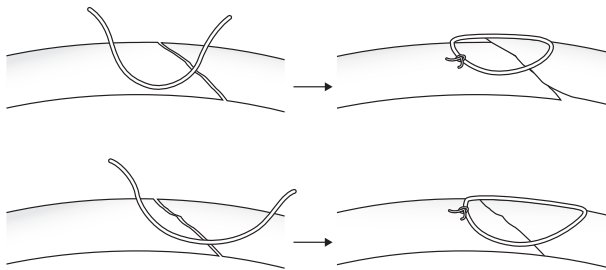
Different techniques are needed when suturing a corneal laceration as opposed to a corneal incision. The surgeon must avoid override of the tissue. In perpendicular incisions, tissue override is produced if the entry and exit sites are of unequal depth, or if the suture bites on either side of the incision are of different lengths. Therefore, deep passes of equal depth are necessary for good tissue apposition in a perpendicular wound and the length of each suture pass is equal as measured from the anterior surface of the cornea. In an oblique or shelved incision, this technique will result in tissue override (Fig. 147.9). To avoid override, the deepest passage of the suture in an oblique or shelved laceration should be of equal lengths from the posterior or internal aspect of the wound, not the anterior aspect. The distance from the needle entry to the posterior edge of the oblique incision is gauged and the needle is passed to exit the stroma



**Fig. 147.7** Slipknot for controlled suture tension. After the initial throw, a slipknot may be formed. One end is pulled vertically while the other is pulled horizontally to tighten the suture to the desired tension.



**Fig. 147.8** Perpendicular versus shelved areas of a corneal laceration. Closure of the perpendicular areas of the laceration will allow the shelved areas of the laceration to self-seal, requiring minimal suture tension.



**Fig. 147.9** Suture placement for corneal lacerations. If the suture enters and emerges equidistant to the anterior wound, the stitch will be asymmetric and encompass only part of the overriding wound margin. If the entry and exit sites are equidistant to the posterior aspect of the wound, the wound will appear asymmetric from the anterior surface. The sutures should not be overly tightened because this will cause shifting of the wound margins and overriding of the tissue.

beyond the anterior surface entry site of the wound. Using this technique the suture may appear asymmetric from the anterior or epithelial surface. However, from the posterior or internal perspective of the wound, the suture is symmetric.<sup>42</sup> If the perpendicular area of the laceration is closed first, the oblique or shelved area apposes spontaneously and minimal suture tension is required. Therefore, these sutures are tied with enough tension to appose the cut surfaces, but should not be tight enough to compress the surrounding tissue.

Management of corneal astigmatism in repair of a corneal laceration is essential. Peripheral compression sutures are placed to compress and flatten the corneal periphery and, subsequently, steepen the central cornea.<sup>44,45</sup> The central cornea wound is closed with small, short appositional sutures with minimal suture tension (Fig. 147.10). A separate paracentesis track is made through which the anterior chamber

is formed and the wound is checked for leaks. Fluorescein (2%) may be applied to the surface to verify complete wound closure. High magnification is used to monitor the surface of the wound for leakage while pressure is applied to the globe.

### Suturing the zig-zag incision

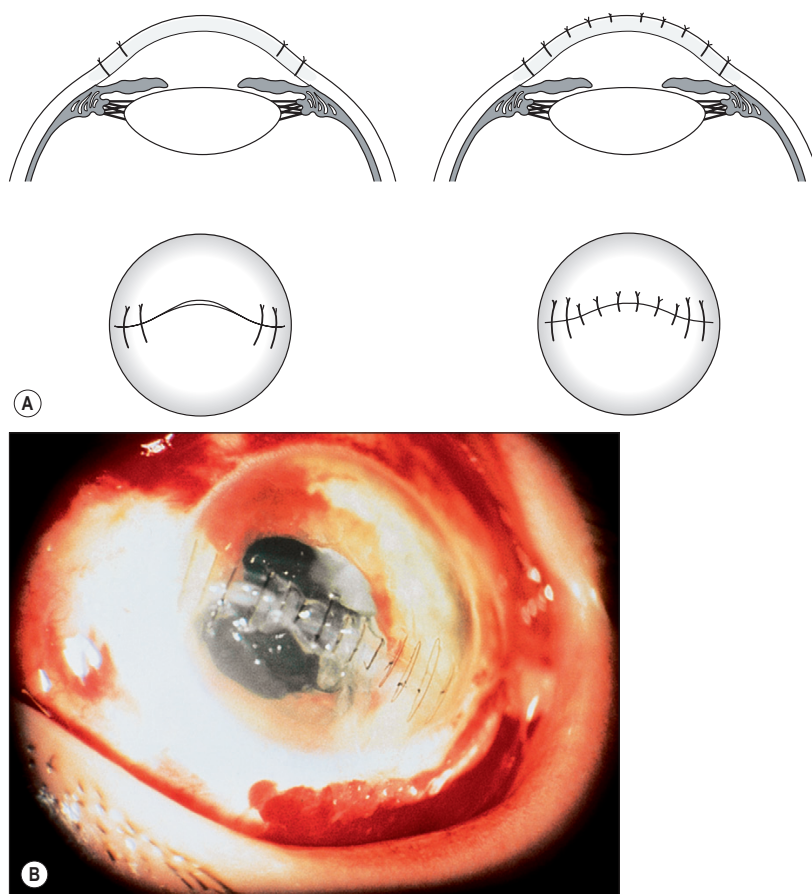
In closing a jagged incision, each linear aspect of the incision is closed individually. It is important to avoid closing the apices first. Closing the linear aspects of the laceration first may allow the apices to self-seal, avoiding additional trauma to that tissue. The use of a slipknot is invaluable in the repair of these lacerations. When it is necessary to close the apex of a jagged laceration, a mattress suture is useful (Fig. 147.11).<sup>46</sup> A partial-thickness incision is made with a guarded blade set at 0.30 mm distal to the flap. The suture is passed from the base of the partial-thickness incision through the flap and back through the partial-thickness incision, where it is tied. This suture is left in place and allowed to degrade over time.

### Stellate lacerations

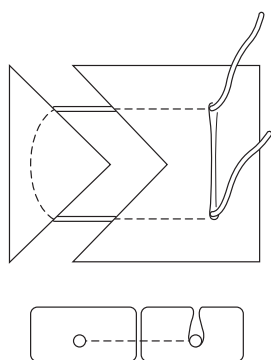
A variation of the mattress suture technique has been suggested by Eisner to close a stellate laceration (Fig. 147.12). A purse-string suture is placed to avoid trauma to the apices of the laceration.<sup>42,47</sup> In this technique a diamond knife is used to incise the normal corneal stroma to half stromal thickness depth. A guarded diamond knife may be set at 0.3 mm to make these incisions. A 10-0 nylon suture is then serially passed from the depth of these diamond knife incisions through the adjacent stroma and laceration, and out through the neighboring diamond knife incision. Tightening of suture will appose the central stroma and the apices of the laceration. A slipknot may be used to control the tightness of this suture and the knot remains buried at the predetermined depth of the diamond knife incisions. If the suture is too tight, the edges of the wound will be overly compressed, causing forward displacement of the apices with subsequent wound leakage. This purse-string suture is left in place once it is tied, as it is entirely within the corneal stroma.

### Management of tissue loss

In the face of tissue loss that cannot be sealed with tissue glue, a lamellar corneal autograft may be used (Fig. 147.13).<sup>48-52</sup> This technique is useful for wounds that are less than 5 mm in diameter with non-necrotic stroma. A circular trephine is used to trephine half corneal depth, 1 mm larger than the area of tissue loss. A corneal bed is created by lamellar dissection of the stroma around the area of tissue loss. The same size trephine is then moved to the peripheral cornea in an area that was not involved in the injury and a partial-thickness trephination is performed. A lamellar dissection is used to free the corneal autograft, which is placed over the area of tissue loss and secured into position with four small interrupted 10-0 nylon sutures, the knots of which are buried. If an autologous graft is not possible, donor cornea or sclera may be used. However, an autograft precludes the need for donor tissue and avoids the risk of graft rejection or disease transmission.



**Fig. 147.10** Peripheral compression sutures. **(A)** Peripheral compression sutures placed to flatten the peripheral cornea. Note: longer bites are used in the peripheral cornea, and small, short appositional sutures with minimal tension are used in the central cornea. **(B)** A corneal laceration 1 day postoperatively. Short appositional sutures have been placed centrally in the perpendicular aspect areas of the wound. The peripheral shelved areas have been closed with longer peripheral compression sutures to flatten the peripheral cornea.

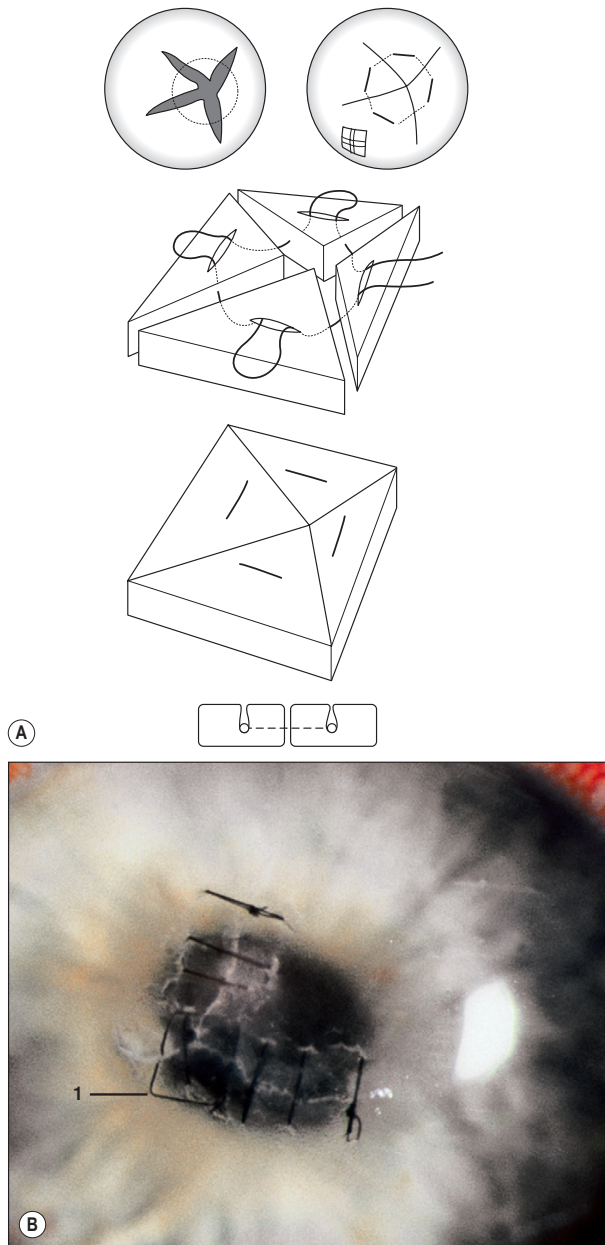


**Fig. 147.11** A purely intralamellar suture may be placed in the apex of a laceration using a mattress suture. A partial-thickness incision is made with a guarded diamond blade distal to the flap. The suture is then passed from the base of this incision through the flap and back to the groove, where it is tied.

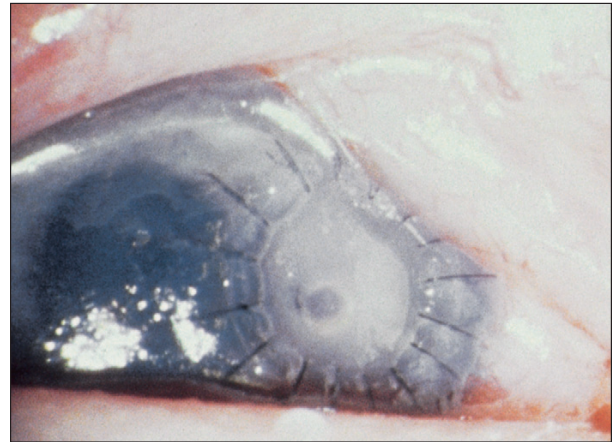
### Corneoscleral lacerations

Lacerations extending beyond the limbus and into the sclera are carefully explored to delineate their full extent. Care is taken at every stage to prevent iatrogenic damage or further

extrusion of intraocular contents. If possible, the limbus is first reapproximated to restore normal anatomic relationships using 8-0 or 9-0 nylon sutures. Prolapsed iris is repositioned and the corneal wound closed. Injection of a viscoelastic agent facilitates repositioning of the iris. A localized conjunctival peritomy is carefully made and the wound boundaries are explored, checking for foreign bodies, vitreous, or uveal prolapse. Tissue exposed by careful conjunctival dissection is not routinely sent for culture as the conjunctiva has covered it during the traumatic incident. To progressively stabilize the globe and prevent uveal prolapse, scleral sutures are placed as soon as a new area of laceration is exposed before exploring distal to this area (using a hand-over-hand technique). For scleral suturing, a 7-0 or 8-0 polyglactin (Vicryl, Ethicon) absorbable suture is used.<sup>53,54</sup> When the wound is gaping, the needle is completely passed through one side of the wound and regripped before making the second pass to avoid distortion of the globe. A laceration that extends behind the extraocular muscles may be closed while an assistant retracts the muscle with a muscle hook. If necessary, the muscle is disinserted after being secured with a double-armed 6-0 Vicryl suture. This suture is used to retract the muscle while the full extent of the laceration is closed and to reattach the muscle at its insertion. Vitreous prolapse through the scleral wound is identified with a dry



**Fig. 147.12** Closure of a stellate wound. **(A)** Closure of a stellate wound with an intralamellar purse-string suture. A partial-thickness corneal incision is made with a guarded diamond blade set at 0.3 mm. A purse-string suture is passed through these grooves and tightened to approximate the apices of the flaps. **(B)** Clinical correlate of closure of a stellate wound with an intralamellar purse-string suture. A stellate laceration is closed with interrupted sutures. The apices are closed with an intralamellar purse-string suture (1). (Courtesy of Steven B. Koenig, MD.)



**Fig. 147.13** Use of a lamellar corneal patch graft to close an area of tissue loss. (Courtesy of Steven B. Koenig, MD.)

cellulose sponge, and cut flush with the sclera, avoiding traction on the vitreous.

Uveal tissue may prolapse through a gaping scleral incision. When possible, uveal tissue is repositioned, as excision causes severe bleeding. Any tissues removed from the eye are identified histopathologically; evidence of excised retina carries an extremely poor prognosis. The preferred method of scleral closure with prolapsed uvea involves a hand-over-hand technique in which the wound is closed from the limbal end with interrupted sutures placed successively posteriorly as the wound is exposed. The sutures are placed closely together to close the scleral tissue over the uvea. An assistant may need to use a spatula to gently depress the prolapsed tissue into the eye as the sutures are secured.

### Iris trauma

Penetrating wounds of the anterior segment commonly result in iris injury, either as a consequence of iris incarceration in the wound, blunt trauma, or direct laceration. The most common patterns of iris injury after severe blunt trauma are sphincter tears and dialysis of the iris root.<sup>55</sup> Iridoschisis and iris atrophy may occur as long-term sequelae. An incarcerated but nonprolapsing iris should not be sacrificed. The iris is repositioned with viscoelastic material injected through a separate paracentesis track to deepen the chamber and draw the iris away from the cornea. If this technique fails, a fine cyclodialysis spatula is used to sweep the corneal laceration free of iris. The iris is always released from incarceration within the corneal wound. Iris should not remain in permanent contact with the corneal laceration because over time endothelial cells slide off the cornea onto the adjacent iris, with eventual formation of corneal edema around the laceration site.

Excision of iris tissue is avoided, if possible, to prevent visual disturbances that may result from loss of iris tissue. Prolapsed or exposed iris is cultured and carefully evaluated before excision. Exposed or necrotic iris may be colonized with microorganisms, and repositing this iris will prolong inflammation and increase the risk of endophthalmitis. Iris