

Pars Planitis: A 20-Year Study of Incidence, Clinical Features, and Outcomes

MARK J. DONALDSON, JOSE S. PULIDO, DAVID C. HERMAN, NANCY DIEHL, AND DAVID HODGE

- **PURPOSE:** To measure the incidence of pars planitis in a community-based population and to report clinical features, complications, and visual prognosis.
- **DESIGN:** Population-based, retrospective, 20-year cohort study.
- **METHODS:** Multicenter study using the Rochester Epidemiology Project medical records linkage system, which allows analysis of almost all patients within Olmsted County, Minnesota, with a given medical condition. Databases were searched to identify all patients with pars planitis from January 1, 1985 through December 31, 2004. Forty-six eyes of 25 patients were evaluated.
- **RESULTS:** Mean follow-up was 14.3 years. The incidence of pars planitis was 2.077 per 100,000 persons (95% confidence interval [CI], 1.43 to 2.62). The most common complications were epiretinal membrane (ERM) in 17 eyes (36%), cataract in 14 eyes (30.4%), and cystoid macular edema (CME) in 12 eyes (26.1%). Mean visual acuity after 10 years of follow-up was 20/30, with 18 of 24 patients maintaining a visual acuity of 20/40 or better. One-third of patients maintained normal visual acuity without requiring treatment.
- **CONCLUSIONS:** The visual prognosis of pars planitis is relatively good, with 75% of patients maintaining a visual acuity of 20/40 or better after 10 years. Many patients with mild disease do not require treatment. A subset of patients, however, experience severe disease with severe vision loss despite treatment. The rate of smoking and multiple sclerosis in patients with pars planitis is much higher than that of the general population. (Am J Ophthalmol 2007;144:812–817. © 2007 by Elsevier Inc. All rights reserved.)

PARS PLANITIS IS AN IDIOPATHIC CHRONIC INTERMEDIATE uveitis characterized by inflammatory cellular infiltration over the pars plana and into the vitreous body and associated with only mild anterior segment inflammation. The Standardization of Uveitis Nomenclature working group has recommended that the term “pars planitis” be reserved for “that subset of intermediate uveitis associated with snowbank or snowball formation in the absence of an associated infection or systemic disease.”¹

Accepted for publication Aug 10, 2007.

From the Departments of Ophthalmology (M.J.D., J.S.P., D.C.H.); and Health Science Research (N.D., D.H.), Mayo Clinic College of Medicine, Rochester, Minnesota.

Inquiries to Jose S. Pulido, Department of Ophthalmology, Mayo Clinic, 200 First Street SW, Rochester, MN 55905; e-mail: pulido.jose@mayo.edu

There are limited data on the incidence of pars planitis. The Northern California Epidemiology of Uveitis Study reported a rate of 1.5 per 100,000 population years.² In tertiary referral centers, which see a more severe end of the spectrum of ocular inflammatory disease, 2.4% to 15.4% of uveitis patients have been reported as carrying the diagnosis of pars planitis.^{3,4} We conducted a population-based study using the resources of the Rochester Epidemiology Project database⁵ to evaluate more accurately the incidence, clinical features, and outcome of pars planitis in a well-defined community-based population.

METHODS

WE REVIEWED 20 YEARS OF DATA (JANUARY 1, 1985 through December 31, 2004) from the medical records of the Mayo Clinic and the Rochester Epidemiology Project. The Rochester Epidemiology Project is a unique database that combines the inpatient and outpatient medical records of the Mayo Clinic Rochester, its affiliated hospitals (St Marys Hospital and Rochester Methodist Hospital), the Olmsted Medical Group, Olmsted Community Hospital, and a number of individual practitioners. Together, these facilities encompass all major medical facilities within Olmsted County. Because Olmsted County is a well-defined community, relatively isolated from other urban centers, the data include more than 90 % of medical encounters and 96% of hospitalizations of local residents.⁵

The computerized medical record index system was searched for all patients with a diagnosis of pars planitis, intermediate uveitis, vitritis, or posterior uveitis. To ensure no cases were missed, all records of patients with a diagnosis of uveitis not otherwise specified also were reviewed. As a further check to ensure no cases were missed, the independent database of the Department of Ophthalmology photography department was searched.

Only definite pars planitis defined as an idiopathic intermediate uveitis unassociated with other systemic disorders was included for analysis. All patients were required to have vitreous cells and snowball or pars plana exudate (snowbank) formation in at least one eye. Patients were excluded if follow-up was fewer than six months, if the disease involved primarily the anterior segment, if there was a history of systemic disease other than multiple sclerosis associated with intermediate uveitis either at diagnosis or during follow-up, and if there were any laboratory abnormalities

TABLE. Incidence Rates of Pars Planitis, Olmsted County, Minnesota, 1985 through 2004

	Incidence Rate per 100,000 Persons	Standard Error (Poisson)	95% Confidence Intervals	
			Lower	Upper
Age-adjusted, females	2.64	0.50	1.67	3.62
Age-adjusted, males	1.52	0.37	0.80	2.25
Age-adjusted, total	2.08	0.31	1.47	2.68
Age- and gender-adjusted, total*	2.08	0.31	1.47	2.68

*Adjusted for 2000 United States White population.

suggestive of systemic disease known to be associated with intermediate uveitis, in particular sarcoidosis, or infection.

Clinical data collected included best-corrected Snellen visual acuity, the degree of anterior segment inflammation (graded 1 through 4), the presence or absence of anterior segment complications, cataract (graded 1 through 4), vitreous cells (graded 1 through 4), snowballs, pars plana exudates (snowbanks), epiretinal membrane (ERM), cystoid macular edema (CME), vascular sheathing, retinal neovascularization, optic disk swelling, vitreous hemorrhage, and retinal detachment. Formal diagnostic criteria were used to define the presence of systemic disease. Additionally, the diagnosis of multiple sclerosis required confirmation of the diagnosis in the medical history by a Mayo Clinic or Olmsted Medical Group neurologist.

The annual age- and gender-adjusted incidence rates were calculated by using the age-specific and gender-specific populations figures for Olmsted County, Minnesota, from the United States Census Bureau. Age-specific and gender-specific denominators for individual years were generated from linear interpolation of the census figures and by using stat demographer data projections of the Olmsted County population. The 95% confidence intervals (CIs) were calculated for the rates with assumptions based on the Poisson distribution. Long-term complication rates were estimated using the Kaplan-Meier method.

RESULTS

REVIEW OF THE COMPUTERIZED RECORD SYSTEM REVEALED 256 patients. Excluding those who were not residents of Olmsted County excluded all but 53 patients. Of these 53 patients, 28 were excluded from analysis. Reasons for exclusion were as follows: insufficient evidence in the medical record to confirm the diagnosis of pars planitis (19 patients), insufficient follow-up (four patients), patient declined research authorization (three patients), and the presence of possibly related systemic disease (two patients). Systemic disorders found to be associated with ocular features indistinguishable from pars planitis in this series were sarcoidosis in one patient and Behçet disease in one patient. In an attempt to ensure that no cases were missed,

306 charts of patients with a diagnosis of uveitis not otherwise specified were searched. This search revealed one additional patient.

After exclusions, 46 eyes in 25 patients were included for analysis in the study. There were nine males and 16 females (females, 64%; 95% CI, 43% to 82%). Mean follow-up was 14.3 years (range, 0.76 to 31.9 years). Of the 25 patients, the disease was bilateral in 21 and unilateral in four. Age of onset ranged from 8.5 to 42.9 years (mean, 22.6 years; median, 20.7 years). There was no statistically significant difference in age at onset between male and female patients ($P = .630$). Twenty-three patients were White and two were Asian. No familial cases were identified. Thirteen patients were smokers (52.0%).

The annual incidence rates per 100,000 Olmsted County residents for males, females, and combined are presented in the Table. The annual incidence rate per 100,000 adjusted to the age and gender distribution for the 2000 United States White population was 2.08 per 100,000 persons (95% CI, 1.43 to 2.62).

The most common presenting symptoms were blurred vision in 34 eyes (73.9%) and floaters in 28 eyes (60.9%). Other less common symptoms were pain (three eyes; 6.5%), photophobia (three eyes; 6.5%), and redness (two eyes; 4.3%). Three eyes were totally asymptomatic at presentation and were noted to have vitreous cells and snowbanks on examination, but no other vision-threatening complications. All three of these eyes maintained 20/20 acuity. There were 19 eyes with floaters only that had a visual acuity of 20/20 at presentation. Mean best-corrected visual acuity (BCVA) at presentation was 0.78 Snellen fraction, equivalent to a Snellen acuity of 20/25.6, with a range of 0.1 (20/200) to 1.0 (20/20).

Anterior chamber cells were present in 13 eyes (28.3%). In 11 cases, the anterior uveitis was graded 1+ from a scale of 1 through 4. In two eyes from one patient, it was graded 3+. Posterior synechiae were rare and were present to a mild degree in only five eyes.

Vitreous cells were present in 41 of 46 eyes (89.1%). Vitreous cells were graded 1+ in nine eyes, 2+ in 26 eyes, and 3+ in six eyes. In five eyes, vitreous cells were not noted. Four of these eyes, which demonstrated definite

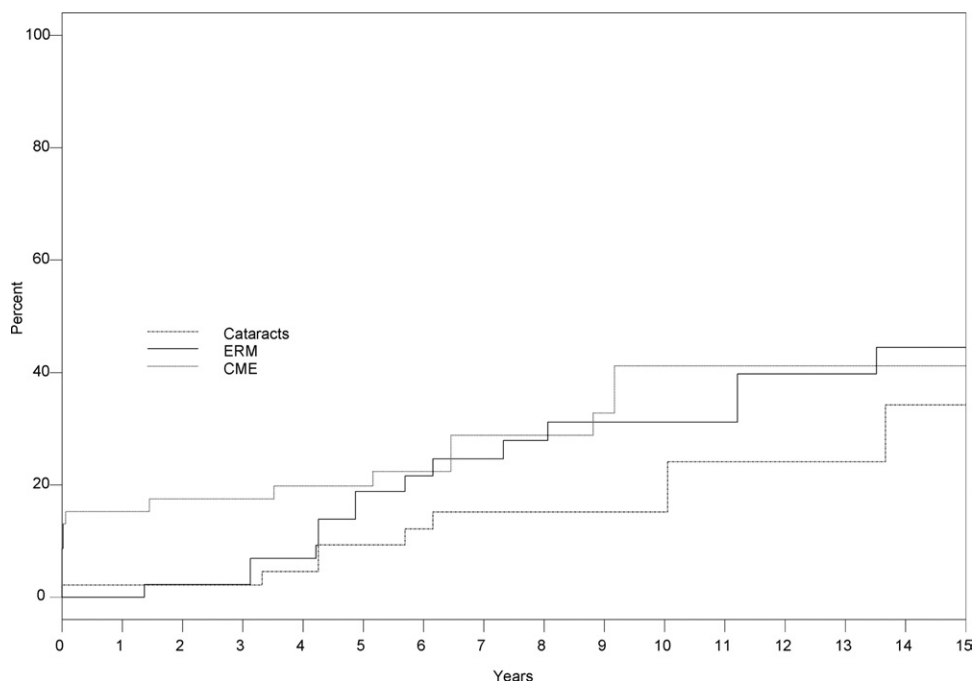


FIGURE. Kaplan-Meier plot showing development of cataract, cystoid macular edema (CME), and epiretinal membrane (ERM) in patients with pars planitis.

snowbanks, were in the more mildly affected fellow eye of patients with asymmetric disease severity.

Pars plana exudates (snowbanks) were present in 45 of 46 eyes. Snowballs (large collections of vitreous cells) were present in 31 of 46 eyes. The one eye in which a snowbank was not noted, was the much more mildly affected eye of a fellow eye with definite snowbanks. It is not possible to know if the snowbank in the more mildly affected eye was truly absent or mild and was missed on examination. Peripheral retinal vascular sheathing was noted in 15 eyes (32.6%). This was bilateral in six patients (12 eyes) and unilateral in an additional three patients. One patient with multiple sclerosis was noted to have vascular sheathing and two were not. Other findings noted included optic disk swelling in three patients, pars plana neovascularization in one patient, and optic disk pallor in one patient.

The most common ocular complication of pars planitis was ERM, which developed in 17 eyes (15-year rate, 44.4%; 95% CI, 23.0% to 60.4%). In one eye, this required vitrectomy and membrane peeling. The mean interval between onset of pars planitis and development of ERM was 8.1 years (median, 6.2 years; range, 3.1 to 17.7 years).

Cataract, as reported by the treating physician in the clinical notes, developed in 14 eyes (15-year rate, 34.2%; 95% CI, 12.6% to 51.6%). Most of these, 10 cases, were posterior subcapsular cataracts. In two eyes, mixed nuclear sclerotic and posterior subcapsular cataracts developed, and in two eyes, cataracts were nuclear sclerotic only. Cataract was noted at presentation in one eye. In most cases, they developed much later, with a mean onset after presentation of 9.8 years (median, 8.9 years; range, 0.0 to

23.2 years). Cataract surgery was performed in five eyes. In all five eyes, the inflammation was quiet before cataract surgery and patients were not receiving any treatment before cataract surgery. All five eyes underwent insertion of an intraocular lens. Two required laser posterior capsulotomy. All eyes were treated with topical steroids after surgery, and one patient was given oral steroids. In no cases was there a recurrence of intraocular inflammation after cataract surgery. Mean visual acuity six months after cataract surgery in the three patients for whom data is available was 0.93 (20/21.5).

Cystoid macular edema was a major cause of visual loss and developed in 12 eyes (15-year rate, 41.2%; 95% CI, 21.1% to 57.6%). The mean interval between onset of pars planitis and development of CME was 5.7 years (median, 5.2 years; range, zero to 18.3 years). A Kaplan-Meier plot of the development of the three major complications of cataract, ERM, and CME with time are shown in the [Figure](#).

Retinal detachment developed in one eye. Elevated intraocular pressure of more than 20 mm Hg developed in one eye. In one patient, ptosis secondary to periocular corticosteroid injections developed.

Systemic conditions noted included psychiatric disorders in four patients (depression, bipolar disorder, adjustment disorder, and anxiety), multiple sclerosis in three patients, asthma in two patients, hypertension in two patients, and non-insulin-dependent diabetes mellitus in two patients. In one patient, the diagnosis of multiple sclerosis was made one-year before the onset of pars planitis, and in the other two patients, the diagnosis of multiple sclerosis was made after intervals of four

and 30 years after the onset of pars planitis. In one patient, osteoporosis resulting from systemic corticosteroids developed.

Treatment for pars planitis was required in 30 of 46 eyes (65.2%). Sixteen eyes had mild or burnt out disease that was judged not to require treatment. The most common treatments used were topical steroids in 20 eyes (43.5%) and pericocular steroid injections in 19 eyes (41.3%). Systemic steroids were used in 11 eyes (23.9%). Systemic immunosuppressive agents were used in only one patient in whom oral methotrexate and later oral cyclosporin were used. Two patients underwent vitrectomy, one for ERMs and one for severe vitritis. Cryotherapy was used in two patients.

Visual acuity tended to decrease slowly with time, although a few patients experienced functionally significant visual impairment. Mean visual acuity in 45 eyes after one year of follow-up was 0.81 (20/25). This decreased with time, but only slightly, and after two years of follow-up in 33 eyes was 0.74 (20/27). The median visual acuity at presentation was 1.0, and at five years this had declined to 0.66 (20/30) based on data from 33 patients. This decline in visual acuity from presentation to the five-year follow-up was statistically significant by the signed-rank paired comparison test ($.02 \leq P \text{ value} \leq .05$). After 10 years of follow-up in 22 eyes, median BCVA was 0.67 (20/30). The *P* value for change in visual acuity from the five-year point to the 10-year point was not statistically significant.

Of the 24 eyes with more than 10 years of follow-up, 18 had BCVA of 20/40 or better. Only three eyes had a BCVA of 20/200 or less. Mean BCVA of all eyes at final follow-up was 0.77 (20/26; mean time to final follow-up examination, 14.33 years). Conditions associated with a decrease in visual acuity less than 20/40 at final follow-up were cataract in three eyes, optic neuritis in two eyes, ERM in two eyes, and CME in one eye. Some eyes demonstrated more than one cause for vision loss.

DISCUSSION

WE RETROSPECTIVELY REVIEWED THE MEDICAL HISTORIES of all residents of Olmsted County diagnosed at the Mayo Clinic and affiliated hospitals with pars planitis within the past 20 years. This series represents a broad community-based study encompassing the spectrum of patients from those with mild disease seen by general ophthalmologists to those with severe vision-threatening disease managed in a tertiary care setting by vitreoretinal and uveitis specialists. Many other patients with pars planitis were seen at the Mayo Clinic during the study period; however, to provide population-based data, nonresidents of Olmsted County were excluded. Including those cases would have introduced an unknown amount of referral bias, because many of those referred from outside sources would have represented the more severe end of the spectrum of disease severity.

Pars planitis usually presents in childhood or young adulthood.⁶ Our mean age at presentation of 22.6 years is slightly younger than that of Lauer and associates (25.5 years), Raja and associates (26 years), and Henderly and associates (29 years).⁷⁻⁹ The oldest patient at presentation was 42.9 years. The disease rarely presents after 40 years of age, and in fact, some authors have required an age of onset less than 35 or less than 40 years for inclusion.^{10,11}

The diagnosis of pars planitis requires the presence of pars plana exudates (snowbanks) or snowballs associated with vitreous cells in at least one eye. However, there is a wide variation in clinical severity. At one end of the spectrum are patients who are totally asymptomatic and present for other reasons and are noted to have vitreous cells or vitreous debris and old snowbanking. There were three such patients in our series, and all maintained normal visual acuity with no disease recurrence. It is interesting to speculate whether such patients may have a different cause or whether the mild course is perhaps a result of removal of an environmental stimulus or a genetic difference among patients. At the other end of the spectrum are patients with severe, progressive inflammatory disease resulting in severe vision loss because of macular edema or retinal detachment.

Fifty-two percent of patients in this study were smokers (95% CI, 31% to 72%). This is much higher than the smoking rate in Olmsted County, which at 16% is slightly less than the national rate of 23%.^{12,13} This is an interesting finding, and as far as we are aware, this is the first study to link pars planitis with an increased rate of smoking. Helm and Holland¹⁴ previously noted a decreased response to posterior sub-Tenon triamcinolone in patients with intermediate uveitis who smoked, compared with nonsmokers. It is not possible from our study to prove causation, and although it is possible to speculate that an ingredient in cigarette smoke may initiate or augment an immune response resulting in intraocular inflammation, it is also possible that the high smoking rate is a result of the stress induced by a chronic disease. Nevertheless, if only for other systemic benefits, it seems prudent to ask pars planitis patients about their smoking habits and to recommend cessation for those who smoke.

Vision loss in pars planitis may occur because of a number of causes. The most common ocular complication in our series was ERM, which developed in 17 eyes (36.9%). Previous studies also have shown a high incidence of ERM.¹⁰ The mean interval between onset of pars planitis and development of ERM was 7.9 years, similar to the 6.5 years in a previous study of ERM in pars planitis.¹⁵ However, these figures were calculated predominately in the era before optical coherence tomography, and the threshold for diagnosis of ERM is now likely to be much lower. Both patients who underwent surgery for ERM had coexisting CME, and it is not possible in our study to make meaningful comments on the success of vitrectomy for ERM peeling in pars planitis on the basis of such a small

number of cases. However, previous studies have shown that vitrectomy and ERM peeling may result in improved visual acuity in patients with pars planitis.¹⁵

Cataract is a common complication of pars planitis, and in our study, cataract was found in 14 eyes (30.4%). However, it is difficult to distinguish which cases were the result of the disease and which were the result of complications of treatment. Vitreous hemorrhage was noted in a number of patients who were referred to the Mayo Clinic but were later excluded because of nonresidency status in Olmsted County, so we can only conclude that the incidence of vitreous hemorrhage resulting from pars planitis in the community is low.

Multiple sclerosis has been noted to be associated strongly with pars planitis in many studies. In three patients in our series, multiple sclerosis developed (12%; 95% CI, 2.6% to 31.2%). This is similar to previous large studies that have reported the incidence of pars planitis to be 14.8% to 16.2%.^{8,10} This value is much higher than the incidence of multiple sclerosis in the Olmsted County population during the same period, which has been measured to be 7.5 per 100,000 persons.¹⁶

The treatment of pars planitis is a stepwise approach based on disease severity. Very mild cases with normal visual acuity and no vision-threatening complications such as CME may require no treatment. In our study, one-third of patients maintained normal visual acuity without requiring treatment. This is an important message considering the well-known side effects of treatment, including steroid-induced cataract, glaucoma, and the potentially life-threatening complications of systemic steroids.

The visual prognosis of pars planitis in most patients is good, with 18 of 24 eyes (75%) maintaining a visual acuity of 20/40 or better after 10 years of follow-up. Similarly favorable results were found by Raja and associates.⁸ In their study, approximately 90% of patients maintained a BCVA of 20/40 or better in the better eye.

Potential limitations of this study include those common to all retrospective series. In addition, the population of Olmsted County is a relatively homogeneous population, with a higher percentage of White persons than in other population centers in the United States. This may limit the generalizability of the data; however, studies of

pars planitis from centers with more diverse population bases consistently have shown that pars planitis is much more common in White persons and very rare in other races.⁸ Subclinical or mild cases insufficient to prompt referral would not have been detected, and therefore, our figures represent only those patients with symptomatic pars planitis. Similarly, patients with subclinical multiple sclerosis may not have been diagnosed. It is possible that some patients may have been missed because of inaccurate coding or because patients sought care outside of Olmsted County. Therefore, our incidence figures most likely represent a slight underestimation of the true frequency of the disorder. However, the design of this study to measure incidence probably could not be improved, unless all Olmsted County residents underwent ocular examinations. Given the chronic nature of pars planitis, requiring multiple, frequent office visits and the long distances to other population centers with subspecialty ophthalmology practices, it is uncommon for patients in Olmsted County to travel elsewhere, and most potential subjects should be included in our study. Indeed, a study of Medicare data on cataract surgery in Olmsted County showed that more than 99% of county residents underwent surgery in Rochester, confirming the tendency for patients to seek care locally (Gray D, unpublished data, 1997).¹⁷

In this large, population-based, 20-year study of pars planitis, the annual incidence of pars planitis adjusted to the age and gender distribution for the 2000 United States white population was 2.077 per 100,000 population. This is slightly higher than the figure of 1.5 per 100,000 population reported in the Northern California Epidemiology of Uveitis Study,² which may be the result of the higher proportion of White persons in Minnesota. In contrast to previous studies from tertiary referral centers, the visual prognosis of pars planitis in the community is relatively good, with 75% of eyes maintaining visual acuity of 20/40 or better. One-third of patients maintained normal visual acuity without requiring treatment. The rate of smoking and multiple sclerosis in patients with pars planitis is much higher than that of the general population. A causal link with cigarette smoking remains to be proven, however, it seems prudent to recommend smoking cessation in patients with pars planitis.

THIS STUDY WAS SUPPORTED BY RESEARCH TO PREVENT BLINDNESS, INC, NEW YORK, NEW YORK (DEPARTMENT OF Ophthalmology), and the National Institute of Arthritis and Musculoskeletal and Skin Diseases, National Institutes of Health, Bethesda, Maryland (Rochester Epidemiology Project). All of the authors were involved in design and conduct of the study; data collection; data analysis and interpretation; and preparation and review of the manuscript. The protocol was approved by the Institutional Review Boards of the Mayo Clinic and Olmsted Community Hospital. All research complied with the Health Insurance Portability and Accountability Act and was carried out according to the principles of the Declaration of Helsinki.

REFERENCES

1. Jabs DA, Nussenblatt RB, Rosenbaum JT, Standardization of Uveitis Nomenclature (SUN) Working Group. Standardization of uveitis nomenclature for reporting clinical data. Results of the First International Workshop. *Am J Ophthalmol* 2005;140:509–516.
2. Gritz DC, Wong IG. Incidence and prevalence of uveitis in Northern California: the Northern California Epidemiology of Uveitis Study. *Ophthalmology* 2004;111:491–500.

3. Henderly DE, Genstler AJ, Smith RE, Rao NA. Changing patterns of uveitis. *Am J Ophthalmol* 1987;103:131-136.
4. Wakefield D, Dunlop I, McCluskey PJ, Penny R. Uveitis: aetiology and disease associations in an Australian population. *Aust N Z J Ophthalmol* 1986;14:181-187.
5. Melton LJ III. History of the Rochester Epidemiology Project. *Mayo Clin Proc* 1996;71:266-274.
6. de Boer J, Berendschot TT, van der Does P, Rothova A. Long-term follow-up of intermediate uveitis in children. *Am J Ophthalmol* 2006;141:616-621.
7. Lauer AK, Smith JR, Robertson JE, Rosenbaum JT. Vitreous hemorrhage is a common complication of pediatric pars planitis. *Ophthalmology* 2002;109:95-98.
8. Raja SC, Jabs DA, Dunn JP, et al. Pars planitis: clinical features and class II HLA associations. *Ophthalmology* 1999;106:594-599.
9. Henderly DE, Genstler AJ, Rao NA, Smith RE. Pars planitis. *Trans Ophthalmol Soc U K* 1986;105:227-232.
10. Malinowski SM, Pulido JS, Folk JC. Long-term visual outcome and complications associated with pars planitis. *Ophthalmology* 1993;100:818-824.
11. Guest S, Funkhouser E, Lightman S. Pars planitis: a comparison of childhood onset and adult onset disease. *Clin Experiment Ophthalmol* 2001;29:81-84.
12. Kottke TE, Thomas RJ, Lopez-Jimenez F, et al. CardioVision 2020: program acceptance and progress after 4 years. *Am J Prev Med* 2006;30:137-143.
13. Centers for Disease Control and Prevention. Behavioral Risk Factor Surveillance System survey data. Atlanta, Georgia: U.S. Department of Health and Human Services, 1999-2003.
14. Helm CJ, Holland GN. The effects of posterior subtenon injection of triamcinolone acetonide in patients with intermediate uveitis. *Am J Ophthalmol* 1995;120:55-64.
15. Dev S, Mieler WF, Pulido JS, Mitra RA. Visual outcomes after pars plana vitrectomy for epiretinal membranes associated with pars planitis. *Ophthalmology* 1999;106:1086-1090.
16. Mayr WT, Pittock SJ, McClelland RL, Jorgensen NW, Noseworthy JH, Rodriguez M. Incidence and prevalence of multiple sclerosis in Olmsted County, Minnesota, 1985-2000. *Neurology* 2003;61:1373-1377.
17. Hattenhauer MG, Leavitt JA, Hodge DO, Grill R, Gray DT. Incidence of nonarteritic anterior ischemic optic neuropathy. *Am J Ophthalmol* 1997;123:103-107.



Biosketch

Mark J. Donaldson, MBBS(Hons), graduated from the University of Queensland in Brisbane, Australia and underwent ophthalmology training at the Royal Victorian Eye & Ear Hospital in Melbourne, Australia. Dr Donaldson completed a Vitreoretinal Surgery fellowship at the Mayo Clinic in Rochester, Minnesota and then an additional Vitreoretinal Surgery fellowship with Professor Stanley Chang at Columbia University Medical Center in New York, New York.



Biosketch

Jose S. Pulido, MD, MS, MPH, MBA, is a Professor of Ophthalmology at the Mayo Clinic, Rochester, Minnesota. Dr Pulido has over 200 publications including author or co-author of two books.