

# Ocular Findings in Kenny's Syndrome

James R. Boynton, MD; Thomas R. Pheasant, MD; Bruce L. Johnson, MD;  
Daniel B. Levin, MD; Barbara W. Streeten, MD

• In 1966, Kenny described two patients with an unusual congenital syndrome including dwarfism, thickened long bone cortex, transient hypocalcemia, and normal intelligence. These and other patients previously were incorrectly described as "myopic." Ocular findings in four subjects ranged from uncomplicated nanophthalmos with hyperopia to extreme pseudopapilledema, vascular tortuosity, and macular crowding. Postmortem findings from one patient showed calcium deposits demonstrable only by special histochemical stains that were distributed uniquely in the cornea. This distribution differed greatly from the pattern seen in band keratopathy. Retinal calcification was also an unusual feature. Because one patient exhibited a pseudodoubling of the optic papilla, the literature was reviewed. We conclude that no convincing case of true doubling of the optic nerve has been described. Ophthalmologists should be alert for undiagnosed electrolyte abnormalities, especially hypocalcemia, in patients with Kenny's syndrome.

(Arch Ophthalmol 97:896-900, 1979)

Accepted for publication Nov 13, 1978.

From the Department of Ophthalmology, Warsaw Medical Group, PC, Warsaw, NY (Drs Boynton and Levin); Department of Ophthalmology, University of Rochester, Rochester, NY (Dr Boynton); Division of Ophthalmology, Retina Service, Milton S. Hershey Medical Center, Hershey, Pa (Dr Pheasant); Department of Pathology, University of Pittsburgh School of Medicine (Dr Johnson); and State University of New York, Upstate Medical Center, Syracuse (Dr Streeten).

Reprint requests to Warsaw Medical Group, PC, Warsaw, NY 14569 (Dr Boynton).

In 1966, Kenny and Linarelli described an unusual congenital syndrome.<sup>1</sup> A mother and son exhibited the following characteristics: low birth weight, dwarfism, delayed closure of the anterior fontanel, uniquely thickened long bone cortex with stenotic medullary cavities,<sup>2</sup> transient hypocalcemia with hyperphosphatemia leading to tetany, and normal mentation. To our knowledge, only two additional reports of this syndrome have appeared<sup>3,4</sup> since this original description. The ophthalmic examination in all cases has been incomplete. The reported incidence of "myopia" is erroneous, and actually refers to hypermetropia. This article describes the ocular findings in four patients with Kenny's syndrome, including histologic examination results from one case.

## REPORT OF CASES\*

**CASE 1.**—The patient was born of normal parents and exhibited slow growth after an uneventful delivery. She was first admitted to the hospital at age 9 months with fever, tetany, dwarfism, and retarded bone age. A diagnosis of hypoparathyroidism was made and vitamin D therapy instituted. Multiple admissions because of fever and convulsions followed, usually accompanied by upper respiratory disease. Hypocalcemia and hyperphosphatemia were documented repeatedly. Sporadic electrolyte abnormalities such as hypernatremia

\*All four of the patients reported here were seen by Frederic M. Kenny, MD, who confirmed the diagnosis.

and marginally low potassium levels also were noted. Hearing and dentition were abnormal. Intelligence and test results of pituitary function were normal. At age 10, height and bone age were both retarded. Skull roentgenograms showed bilateral temporal lobe calcifications. X-ray films of the long bones disclosed internal cortical thickening and stenotic medullary cavities.

Physically, the patient appeared miniature with a prominent forehead, microphthalmos, and micrognathia (Fig 1). Height was 102 cm. The sternum was slightly bowed anteriorly.

At age 3 she was seen because of a large right esotropia. The left eye was patched for several months, but there was no change in fixation preference. A bimedial recession was performed with only partial cosmetic improvement, and the following year a recess-resect procedure was done on the right eye. During surgery, the choroid was exposed beneath the lateral rectus insertion when this muscle was severed from the globe. Postoperatively, the media in the right eye were cloudy and a vitreous hemorrhage was diagnosed. Two months later both fundi were visualized. The right disc was blurred and the macular area of each eye was described as gray. At age 5, vision was recorded as counting fingers at 122 cm in the right eye and 20/200 in the left eye. The retina of the right eye was elevated and gray inferotemporally.

The patient was not seen again until she was 9. Vision in the right eye was hand motion due to a dense cataract. An early band keratopathy was noted. Shortly thereafter, an acute glaucoma developed in the right eye with a flat anterior chamber. A posterior sclerotomy and lens aspiration were performed.

We first examined the patient at age 12.

Her best corrected vision was 20/800 in the right eye and 20/200 in the left eye. The refractive error in the left eye was +24.00 diopters. The fundus of the right eye was obscured by a membrane secondary to the lens extraction. Corneas measured 8 mm in diameter and exhibited band keratopathy, greater on the right. The left fundus was filled with multiple, dilated, tortuous vessels. The entire retina appeared swollen and abnormal, especially in the region about the optic nerve. The vascular pattern combined with these highlights presented the deceptive picture of an accessory optic nerve head (Fig 2).

Photographs, however, disclosed a single elevated optic nerve head with tortuous, redundant retinal circulation simulating an accessory optic disc above. The retinal pigment epithelium was prominent in the posterior pole with pigment clumping in the parafoveal region. Fluorescein angiography confirmed a single retinal circulation (Fig 3). Dye transit demonstrated

dilated tortuous arterial and venous systems. Perivascular hyperfluorescence proved to be tortuous vessels viewed end on and out of focus. As the study progressed there was no increase in perivascular fluorescence to imply leakage or loss of competence of the retinal vasculature. The retina appeared crowded, as if confined to a smaller than normal space. The fovea was surrounded by a capillary free zone smaller than expected, an estimated 250  $\mu$  rather than 500  $\mu$ . There was no late hyperfluorescence or dye leakage.

B-scan ultrasonography showed a single nerve pattern and a globe 13 mm in length (Fig 4). The nerve pattern appeared slightly enlarged relative to the size of the globe. Roentgenograms of the optic foramina were unremarkable.

**CASE 2.**—The mother and son originally described by Kenny in 1966 recently were examined. Their systemic findings are detailed in that report. The 13-year-old boy had a facial appearance similar to the first

patient (Fig 5). He was 135 cm tall. Best corrected vision was 20/30 in each eye with a +9.25 sphere in the right eye and a +9.75 sphere in the left eye. Corneas measured 9 mm in diameter. Optic discs appeared slightly elevated with blurred margins and tortuous retinal vessels (Fig 6). Findings from the remainder of the ocular examination were normal.

**CASE 3.**—The 50-year-old mother of patient 2 was also examined. She had a history of mild diabetes and was under 117 cm in height. Vision was 20/25 with a +5.75, +1.75  $\times$  130° in the right eye and 20/40 with a +6.50, +1.25  $\times$  60° in the left eye. Corneas measured 10 mm in diameter. The fundi were unremarkable.

**CASE 4.**—The patient enjoyed good health until age 5, at which time he experienced an episode of tetany that was treated successfully with orally administered calcium. Subsequently, he was begun on vitamin D therapy. At age 8, growth retardation was apparent. Extensive clinical

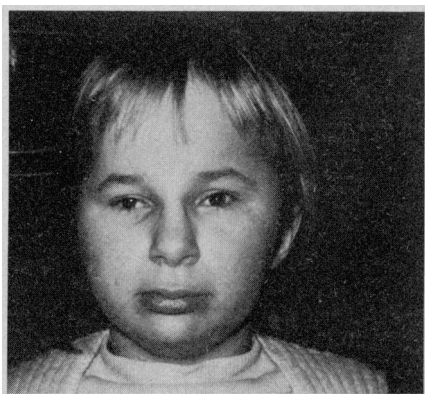


Fig 1.—Facial appearance of a 13-year-old girl, characteristic of Kenny's syndrome (case 1).

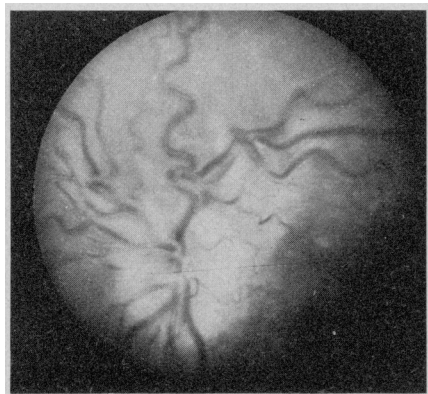


Fig 2.—Left eye: retinal vessels are tortuous and dilated; disc is blurred and elevated. Confluence of vessels combined with unusual retinal highlights simulates "accessory disc" superotemporal to nerve head. Macular area is deeply pigmented and poorly defined (case 1).

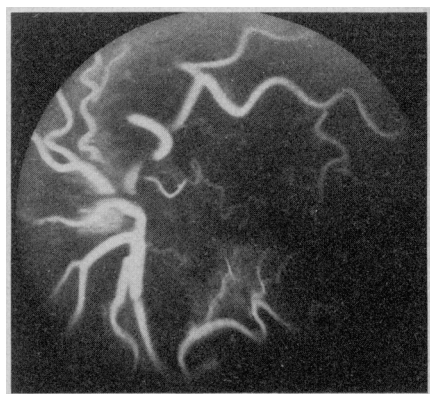


Fig 3.—Left eye: fluorescein angiogram, arterial phase. Single tortuous vascular system is present. There was no leakage of fluorescein in later photographs (case 1).

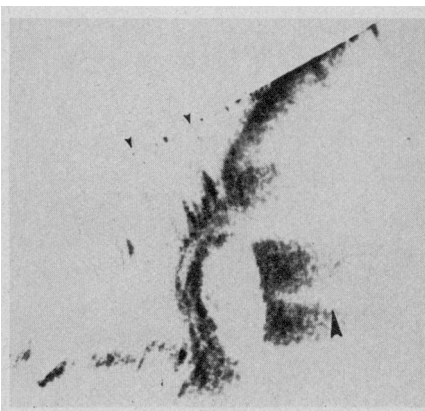


Fig 4.—Left eye: B-scan ultrasonogram demonstrates microphthalmos, globe measuring 13 mm anteroposteriorly. Optic nerve pattern (large arrow) is slightly larger than expected for eye this size. Distance between range lines (small arrows) is 10 mm (case 1).



Fig 5.—Characteristic facial appearance of a 13-year-old boy with Kenny's syndrome (case 2).

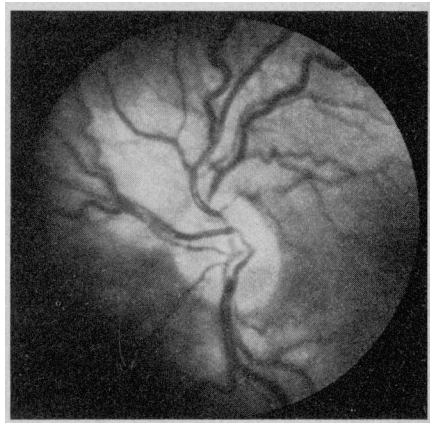

Fig 6.—Left eye: disc is slightly elevated and vasculature moderately tortuous (case 2).

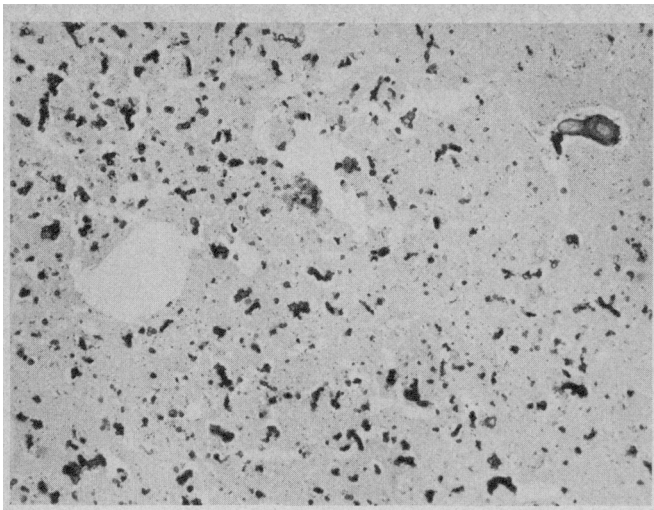


Fig 7.—Basal ganglia contains numerous irregular calcium deposits and mineralized thick-walled vessel (hematoxylin-eosin, original magnification  $\times 60$ ).




Fig 8.—Optic disc is elevated, lacks physiologic cup, but is not edematous. Scleral aperture is slightly narrow (hematoxylin-eosin, original magnification  $\times 35$ ).

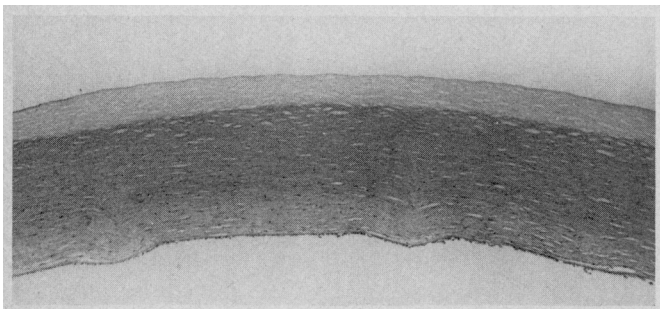


Fig 9.—Low-power view of central cornea. Superficial stroma is uninvolved while deeper stroma, which is darker staining, contains abundant calcium (Von Kossa, original magnification  $\times 35$ ).

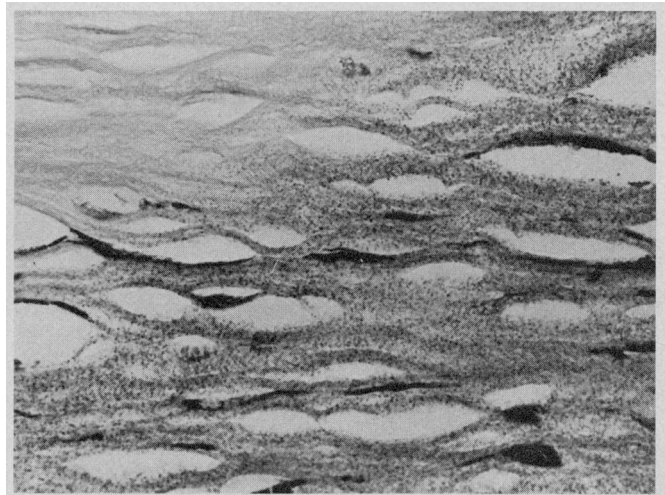


Fig 10.—Termination of corneal calcification zone. Black-staining keratocytic nuclei are heavily calcified and abundant fine granules of calcium are present in collagen lamellae. In contrast, uninvolved upper left portion of field contains pale-staining keratocytic nuclei and no calcium deposits in collagen (Von Kossa, original magnification  $\times 350$ ).

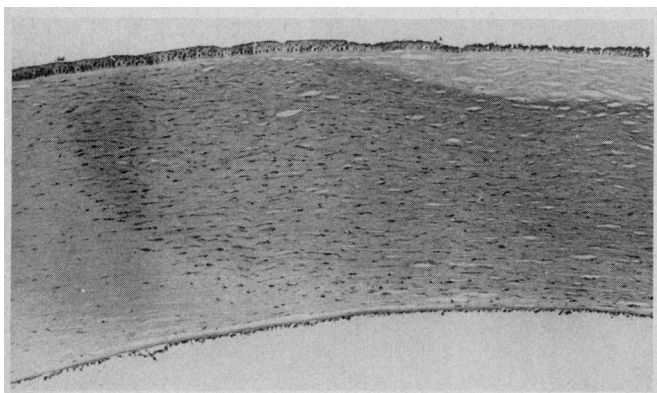
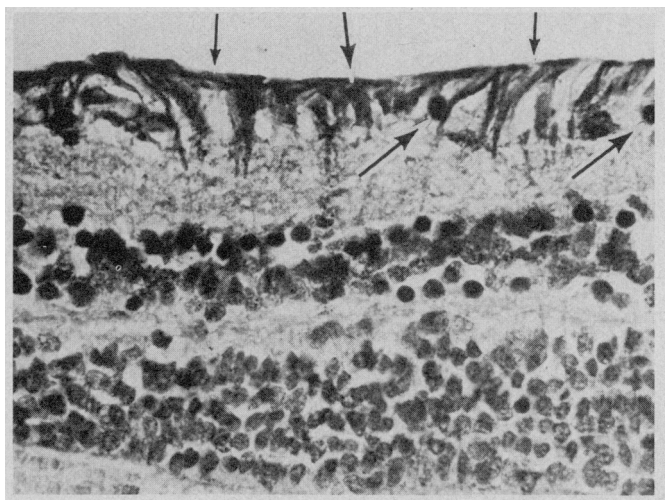


Fig 11.—Periphery of zone of corneal calcification shows abrupt, curved termination. In this area, mineralization involves superficial stroma but Bowman's layer is spared throughout its length (Von Kossa, original magnification  $\times 60$ ).

Fig 12.—Peripheral retina shows heavy calcium impregnation (black) of cytoplasm of Müller cells beneath internal limiting membrane (small arrows). Darker-staining nuclei of ganglion cells (large arrows) and many nuclei in bipolar cell layer also contain calcium (Von Kossa, original magnification  $\times 350$ ).



testing disclosed undetectable levels of parathyroid hormone in the presence of serum hypocalcemia and hyperphosphatemia. X-ray films showed internal cortical thickening of the long bones with medullary stenosis.

The only ophthalmic record available indicated a vision of 20/40 in each eye, achieved with a correction of +9.00, +2.00 × 90° in the right eye and +11.00, +1.50 × 90° in the left eye. The fundi were noted to show "pseudoneuritis" with tortuous vessels.

At age 19 he had a respiratory and cardiac arrest during an upper respiratory illness. At the time of his death, blood chemistry values were sodium, 123 mEq/L; potassium, 2.6 mEq/L; chloride, 85 mEq/L; carbon dioxide, 22 mM/L; and calcium, 6.9 mEq/L.

At autopsy, all organs were small, consistent with dwarfism. Extraocular abnormalities were limited to the bones, brain, and a total absence of any parathyroid tissue. The bones showed internal cortical thickening with medullary stenosis. The calvarium was thin and the anterior fontanel was open. Brain abnormalities included brachycephaly and a partial Arnold-Chiari malformation with congenital tonsillar herniation. There was considerable calcification of the basal ganglia. Calcospherites and psammoma-like bodies were found in this region, and many capillaries contained calcific deposits (Fig 7). Multiple hemispheric gyral abnormalities were present. The cerebellum showed bilateral calcification of the dentate nuclei, gliosis, and shrinkage of the folia.

The enucleated eyes were fixed in phosphate-buffered 10% formaldehyde solution. Both were nanophthalmic, the right measuring 17.5 × 17.5 × 16.5 mm and the left 17 × 17 × 16.5 mm. The clear corneas measured 9.5 × 8.5 mm. On cut section, both corneas were of slightly increased thickness measuring 1 mm peripherally and 0.7 mm centrally. No intraocular abnormalities were noted on gross examination. Microscopically, hematoxylin-eosin-stained sections showed elevated optic discs associated with slightly narrow scleral apertures (Fig 8). The discs appeared swollen with lateral displacement of the peripapillary retina due to a bulging of the edge of the disc tissue usually seen in papilledema. Capillaries were slightly increased in this lateral bulge. The left disc contained several small calcified drusen-like bodies within the nerve fiber bundles anterior to the fibrous portion of the lamina cribrosa.

Histochemical stains (Von Kossa and Dahl's modification of the alizarin red) for the demonstration of the calcium were performed on sections of both eyes. In contrast to the hematoxylin-eosin sections, where no calcification was detectable, the histochemical stains for calcium indicated prominent amounts within the cornea. The corneal epithelium contained abundant calcium within both the nuclei and cytoplasm. This was not present in all cells, but was heaviest in those of the basal layer. Bowman's layer was spared. The stromas

of both corneas showed a peculiar distribution pattern of calcium. The central stroma showed no detectable deposits within its superficial one quarter. The deeper stromal layers, however, disclosed prominent calcification that was most pronounced throughout the central midstroma (Fig 9). This consisted of heavy calcification within keratocytic nuclei with numerous fine deposits within the collagen lamellae of this region (Fig 10). The central zone of calcification terminated rather abruptly in a curved, arc-shaped edge, which at this point approached Bowman's layer (Fig 11). The peripheral stroma failed to show detectable calcium deposition. Alcian blue stains showed excessive amounts of mucopolysaccharides in keratocytes, which contained abundant calcific deposits. This correlated well with the calcium histochemical stains in that abundant mucopolysaccharides were present only in the zone of pronounced calcification. Descemet's membrane was spared throughout its length. Heavy deposits of calcium were present in the corneal endothelium, while less numerous granules were seen within the endothelial cells lining the trabecular meshwork beams. By these histochemical methods, only trace amounts of calcium were noted in the lens nucleus and anterior vitreous. Calcium was demonstrable in the iris and ciliary epithelium. Rather heavy deposition of calcium was present within the inner one half of the preequatorial retina. The heaviest concentrations were present in the cytoplasm of Müller cells near the internal limiting membrane and in the ganglion cell nuclei (Fig 12). Lesser amounts were seen in the nerve fiber layer and the nuclei of scattered cells in the inner portion of the bipolar cell layer. Only rare endothelial cells of a few retinal vessels contained calcium. No calcium was detected within the outer retina. Small amounts were present in occasional astrocytes on the disc surface and except for the calcified drusen-like bodies noted in the hematoxylin-eosin sections, none was seen in the disc substance or attached optic nerves.

#### COMMENT

There is a related spectrum of ocular findings in the above cases. Patient 3 had moderate nanophthalmos and hyperopia, but otherwise normal eyes. Patients 2 and 4 exhibited high hyperopia, nanophthalmos with pseudopapilledema, and retinal vascular tortuosity. Patient 1 demonstrated severe microphthalmos of 13 mm with extreme pseudopapilledema and macular crowding. Although nanophthalmic eyes may be predisposed to angle closure glaucoma,<sup>5</sup> the only such case was seen in an eye in which a mature cataract developed. The anterior chamber angles examined histologically in case 4 appeared small, but normally open. These eyes were 17 mm in diameter.

A congenitally full disc, elevated with blurred margins and tortuous vessels, was seen in three patients and histologically confirmed in one case. This type of nerve head is common in hyperopic eyes, although extreme hyperopia and microphthalmos may exist with relatively normal-appearing discs.<sup>6</sup> Optic nerve head sections in case 4 showed pseudopapilledema resulting from a crowding or compression of the glial and nervous tissue in the region of the disc. Presumably a small scleral canal must accommodate a normal number of axons and supporting elements.

It is also possible that a small scleral aperture could compromise the flow of axoplasm. Altered axoplasmic flow may be a factor in the production of optic disc drusen.<sup>7</sup> The small focal drusen present in case 4 are certainly consistent with this hypothesis. If indeed a small scleral canal causes a holdup of axoplasmic flow, which in turn results in swelling of the nerve fibers anterior to the lamina cribrosa, there may be an element of true disc swelling present. Perhaps some cases regarded in the past as pseudopapilledema are in fact a very low-grade papilledema secondary to local anatomic factors. Similar cases in children have been termed "buried drusen." It may be that early in life there is mild disc swelling that later results in drusen deposition.

The fundus picture in case 1 is an example of extreme pseudopapilledema. Convergence of tortuous vessels combined with light reflexes from the unusual retinal topography produce the deceptive picture of a doubling of the optic nerve head (Fig 1). Fluorescein angiography shows a single extremely hypervascular retinal circulation with reduplications simulating a "double papilla." There is pigment epithelial clumping in the macula and a crowded appearance of the posterior retinal circulation. Many macular abnormalities have been described in microphthalmic and nanophthalmic eyes.<sup>6,8-12</sup> It is possible that some of these macular conditions are due to crowding of the retinal elements into a small scleral shell. Folds in the retina have been seen in small eyes, presumably on this basis.<sup>4</sup>

Case 1 represents an example of pseudodoubling of the optic nerve. A number of articles report duplicated or doubled optic discs and nerves.<sup>13-18</sup> Analysis of these studies shows not one convincingly documented case. Duke-Elder's volume on congenital abnormalities<sup>19</sup> simply quotes the literature on the subject, devoting a



section to double optic nerves without questioning the entity. We believe that true duplication of the optic nerve head does not exist.

Abnormal calcium metabolism is a prominent feature of Kenny's syndrome. The exact nature of these abnormalities has not been determined, but several features have emerged. Bouts of hypocalcemia are easily triggered by minor systemic insults and respond to calcium and vitamin D therapy. At the present time, the relationship of this therapy to tissue calcium deposition is unknown.

Patient 4 is the only known patient with Kenny's syndrome to be studied at autopsy. There was a total absence of parathyroid tissue despite an extensive search of the soft tissues of the neck, including histological step sectioning. All long bones sampled disclosed considerable cortical thickening and severe medullary stenosis. Numerous CNS calcifications were present within the basal ganglia and dentate nuclei, and focal mineralization was seen in the white matter of the cerebral hemispheres and cerebellar folia.

The ocular manifestations of these calcium abnormalities are of interest. Patient 1 exhibited bilateral band keratopathy. Patient 4 showed an unusual pattern of corneal calcification that was not visualized on clinical examination or in the routine hematoxylin-eosin sections, but was detectable only with the aid of special histochemical stains for calcium. In band keratopathy occurring in patients with no abnormalities of blood cal-

cium, the deposition of calcium is confined to heavy infiltration of Bowman's layer. In sharp contrast, Bowman's layer was not involved in this case, but deposits were seen within the basal cells of the corneal epithelium, the central, mid-, and deep stroma, and the endothelial cells. These findings are similar in some respects to the unusual corneal calcification reported by Berkow et al<sup>20</sup> in a patient with secondary hyperparathyroidism. In both, the heaviest concentration of calcium is present within the nuclei of epithelial cells and keratocytes. The current case differs in the peculiar zonal distribution and the much greater amounts of calcium visible within the stromal collagen lamellae. The abundant mucopolysaccharide deposition in the areas of heavy calcium precipitation is in agreement with previous reports<sup>20,21</sup> that have noted this association in areas of metastatic calcification in various sites of the body. While the pathogenesis of mineralization is not well understood, it appears that acid mucopolysaccharides serve as a necessary matrix during the process of calcification. The retinal calcification, which was detectable only by special histochemical stains, appears to be unique and was not noted in the case reported by Berkow et al.<sup>20</sup> We have no explanation for its heavy concentration within the inner retina, particularly within the cytoplasm of Müller cells and the nuclei of ganglion cells. While calcium was present in the vascularized portion of the retina, it is of interest to note that retinal vessels were practically devoid of detectable

calcium deposition. Although vascular factors have in the past been hypothesized as playing a role in metastatic calcification, especially of the CNS,<sup>22</sup> the findings in this case do not support such a suggestion in either the retina or avascular cornea.

The tiny focal drusen deposits in the optic nerve head may relate to the disc swelling, although it is possible they are an incidental finding.<sup>23</sup> Their relationship to the other CNS calcifications is uncertain.

It is important for ophthalmologists to be aware of this syndrome since they may be called on to examine such a patient because of poor vision, small eyes, "papilledema," or other ocular abnormalities. If the diagnosis of Kenny's syndrome is not known or suspected, dangerous electrolyte abnormalities may go undetected or their effects may be treated incorrectly. In these cases the ophthalmologist may make the diagnosis and should be aware of the serious effects of the electrolyte and endocrine abnormalities.

Kenny's syndrome bears a superficial resemblance to pseudohypoparathyroidism. Classically, the latter patients tend to be mentally retarded, are stocky, disproportionate dwarfs, and lack the characteristic roentgenographic picture of the long bones seen in Kenny's syndrome. However, as this condition becomes better defined, it may well be classified as a hypoparathyroid variant, possibly even coming to represent the prototype of congenital hypoparathyroidism.

## References

1. Kenny FM, Linarelli L: Dwarfism and cortical thickening of tubular bones. *Am J Dis Child* 111:201-207, 1966.
2. Caffey J: Congenital stenosis of medullary spaces in tubular bones and calvaria in two proportionate dwarfs: Coupled with transitory hypocalcemia tetany. *AJR* 100:1-11, 1967.
3. Frech RS, McAlister WH: Medullary stenosis of the tubular bones associated with hypocalcemic convulsions and short stature. *Radiology* 91:457-461, 1968.
4. Wilson MG, Maronda RF, Mikity VG, et al: Dwarfism and congenital medullary stenosis (Kenny syndrome). *Birth Defects* 10:128-132, 1974.
5. O'Grady RB: Nanophthalmos. *Am J Ophthalmol* 71:1251-1253, 1971.
6. Boynton JR, Furnell EW: Bilateral microphthalmos without microcornea associated with unusual papillomacular retinal folds and high hyperopia. *Am J Ophthalmol* 79:820-826, 1975.
7. Spencer WH: Drusen of the optic disk and aberrant axoplasmic transport. *Am J Ophthalmol* 85:1-12, 1978.
8. Mohamed MA, Tapeto-retinal degeneration: Report of a new syndrome. *Bull Ophthalmol Soc Egypt* 63:223-227, 1970.
9. Duke-Elder S, Abrams D: Ophthalmic optics and refraction, in Duke-Elder S (ed): *System of Ophthalmology*. St Louis, CV Mosby Co, 1970, vol 5, p 298.
10. Reber M: Microphthalmic complique d'Hypermetropie excessive et d'Anomalies de la macula observee chez trois soeurs. *Ann Oculist* 119:445-446, 1898.
11. Malbran E, Priani P, Lombardi A: Macroquistes de retina, retinosquises e hipermetropia elevada. *Arch Ophthalmol Buenos Aires* 45:180-185, 1970.
12. Von Zuccoli A: Neuer Beitrag zum bild der Makrozysten bei der hohen Hypermetropie. *Ophthalmologica* 145:419-424, 1963.
13. Lamba PA, Prakash P, Dayal Y: Duplication of the optic papilla. *Orient Arch Ophthalmol* 6:87-90, 1968.
14. Aouchiche M, Boyer R, Fetchi A: A propos du diagnostic, des doubles papille. *Bull Soc Fr Ophthalmol* 84:625-635, 1971.
15. Straburzynski J: Double optic disc in patient with Marfan's syndrome. *Klin Oczna* 42:913-915, 1972.
16. Von Bajan M, Holmay O: Doppelte Sehnervenscheibe bei einem Jugendlichen. *Klin Monatsbl Augenheilkd* 151:207-210, 1967.
17. Bonamour MG: A propos des "double papille." *Bull Soc Fr Ophthalmol* 64:802-805, 1964.
18. Lamba PA: Doubling of the papilla. *Acta Ophthalmol* 47:4-9, 1969.
19. Duke-Elder S: *System of Ophthalmology*. St Louis, CV Mosby Co, 1963, vol 3, pt 2.
20. Berkow JW, Fine BS, Zimmerman LE: Unusual ocular calcification in hyperparathyroidism. *Am J Ophthalmol* 66:812-824, 1968.
21. Adachi M, Wellmann KF, Volk BW: Histochemical studies on the pathogenesis of idiopathic non-arteriosclerotic cerebral calcification. *J Neuropathol Exp Neurol* 27:483-499, 1968.
22. Norman RM, Ulrich H: The influence of a vascular factor on the distribution of symmetrical cerebral calcifications. *J Neurosurg Psychiatry* 23:142-147, 1960.
23. Friedman AH, Beckerman B, Gold DH, et al: Drusen of the optic disc. *Survey Ophthalmol* 21:375-390, 1977.