

- [32] Lane S, Modi S, Lehmann R, Holland E. Nepafenac ophthalmic suspension 0.1% for the prevention and treatment of ocular inflammation associated with cataract surgery. *J Cataract Refract Surg* 2007;33:53-58.
- [33] Flach A. Topical nonsteroidal anti-inflammatory drugs in ophthalmology. *Int Ophthalmol Clin* 2002;42:1-11.
- [34] Torron-Fernandez-Blanco C, Ruiz-Moreno O, Ferrer-Novella E, Sanchez-Cano A, Honrubia-Lopez FM. Pseudophakic cystoid macular edema. Assessment with optical coherence tomography. *Arch Soc Esp Oftalmol* 2006;81:147-153.
- [35] Miyake K, Ota I, Maekuba K et al. Latanoprost accelerates disruption of the blood-aqueous barrier and the incidence of angiographic cystoid macular edema in early postoperative pseudophakias. *Arch Ophthalmol* 1999;117:34-40.
- [36] Wand M, Gaudio AR, Shields MB. Latanoprost and cystoid macular edema in high-risk aphakic or pseudophakic eyes. *J Cataract Refract Surg* 2001;27:1397-1401.
- [37] Kruse P, Rieck P, Sherif Z, Liekfeld A. Cystoid macular edema in a pseudophakic patient after several glaucoma procedures. Is local therapy with brimatoprost the reason? *Klin Monatsbl Augenheilkd* 2006;223(6):534-537.
- [38] Arcieri ES, Santana A, Rocha FN, Guapo GL, Costa VP. Blood-aqueous barrier changes after the use of prostaglandin analogues in patients with pseudophakia and aphakia: a 6-month randomized trial. *Arch Ophthalmol* 2005;123(2):186-192.
- [39] Miyake K, Ibaraki N, Goto Y et al. ESCRS Binkhorst Lecture 2002: pseudophakic preservative maculopathy.
- [40] Ahad M, McKee H. Correspondence: stopping prostaglandin analogues in uneventful cataract surgery. *J Cataract Refract Surg* 2004;30(12):2644-2645.
- [41] Marmis N, Edelhauser H, Dawson D, Chew J, LeBoyer R, Werner L. Toxic anterior segment syndrome. *J Cataract Refract Surg* 2006;32:324-333.
- [42] Marmis N, Edelhauser H, Hellinger W, Kamae K. Toxic anterior segment syndrome (TASS) Outbreak Final Report. ASCRS Press Release 2006.
- [43] Shingleton BJ, Wadhvani RA, O'Donoghue MW, Baylus S, Hoey H. Evaluation of intraocular pressure in the immediate period after phacoemulsification. *J Cataract Refract Surg* 2001;27:524-527.
- [44] Cekic O, Batman C. Effect of intracameral carbachol on intraocular pressure following clear cornea phacoemulsification. *Eye* 1999;13(pt 2):209-211.
- [45] Solomon KD, Stewart WC, Hunt HH, Stewar JA, Cate EA. Intraoperative intracameral carbachol in phacoemulsification and posterior chamber lens implantation. *Am J Ophthalmol* 1998;125(1):36-43.
- [46] Kim JY, Sohn JH, Youn DH. Effects of intracameral carbachol and acetylcholine on early postoperative intraocular pressure after cataract extraction. *Korean J Ophthalmol* 1994;8:61-65.
- [47] Wedrich A, Menapace R. Intraocular pressure following small-incision cataract surgery and poly-HEMA posterior chamber lens implantation. A comparison between acetylcholine and carbachol. *J Cataract Refract Surg* 1992;18:500-505.
- [48] Wood. Effect of carbachol on postoperative intraocular pressure. *J Cataract Refract Surg* 1988;14:654-656.
- [49] Hollands RH, Drance SM, House PH, Shulzer M. Control of intraocular pressure after cataract extraction. *Can J Ophthalmol* 1990;25:128-132.
- [50] Ruiz RS, Rhem MN, Prager TC. Effects of carbachol and acetylcholine on intraocular pressure after cataract extraction. *Am J Ophthalmol* 1989;107:7-10.



## Incision Construction

# 13

I. Howard Fine, MD, Richard S. Hoffman, MD and Mark Packer, MD, FACS

### CONTENTS

- Evolution of Small Incisions
- Surgical Techniques for Scleral Tunnel Incisions
- Development of Clear Corneal Incisions
- Indications for Clear Corneal Incisions
- Classification of Clear Corneal Incisions
- Preoperative Evaluation
- Techniques
- Intraoperative and Postoperative Complications
- Postoperative Clinical Course and Outcomes
- Profiles of Clear Corneal Incisions
- Controversies Surrounding Clear Corneal Incisions
- Endophthalmitis: Is there an Increased Risk?
- Conclusion

### CHAPTER HIGHLIGHTS

- >> Principles of self-sealing incisions
- >> Development of clear corneal incisions
- >> Techniques and profiles of clear corneal incisions
- >> Controversies in self-sealing and sutured incision techniques

During the decade between the 1960s and the early 1970s, most cataract surgery in the United States and Europe was performed by the intracapsular cataract extraction technique using a limbal incision under a conjunctival flap. With few exceptions, there was little interest in reducing, minimizing, or altering surgically induced astigmatism.<sup>1,2</sup> The last 25 years have produced a rapid advancement in cataract surgery wound architecture. As the technology for removing cataracts has advanced, there has been a gradual trend towards smaller incisions, moving from the superior scleral to the temporal clear corneal location, in an attempt to reduce intraoperative complications and postoperative astigmatism.

### EVOLUTION OF SMALL INCISIONS

With the advent of phacoemulsification, Kelman<sup>3</sup> predicted that incisions 3 mm wide would be astigmatism neutral because of their reduced size. However, within a very short time of the introduction of phacoemulsification, intraocular lens (IOL) implants became more commonplace. This situation necessitated the enlargement of the phacoemulsification incision to 6.5-7 mm for lens implantation.

Kratz is generally credited as the first surgeon to move from the limbus posteriorly to the sclera in order to increase appositional surfaces thus enhancing wound healing and reducing surgically induced astigmatism (Figure 13-1).<sup>4,5</sup> Girard and Hoffman<sup>6</sup> were first to call the posterior incision a *scleral tunnel incision* and were, along with Kratz, the first to make a point of actually entering the anterior chamber through the cornea creating a corneal shelf. This corneal shelf was designed to prevent iris prolapse. Maloney, who was a fellow of Kratz, advocated a corneal shelf to his incisions, which he described as strong and waterproof.<sup>7</sup>

With the availability of small-incision lenses that could be introduced through incisions of 4-mm or less, the stage was set for the development of techniques that resulted in the achievement of both relative astigmatism-neutral and self-sealing incisions. In 1989, Shepherd<sup>8</sup> introduced the *single horizontal suture*, which was actually a vertical mattress suture, for the closure of 4 mm scleral tunnel incisions in phacoemulsification and foldable lens implantation (Figure 13-2). The achievement of astigmatism neutrality was impressive. Others rapidly recognized that the compressive force of the single horizontal suture was tangential to the limbus and, therefore, exerted no force on the cornea, which would alter its curvature. As a result, variations of the Shepherd single stitch were soon developed for closure of incisions 5-7 mm wide, including the Fine infinity suture (Figure 13-3),<sup>9</sup> Masket's horizontal anchor suture (Figure 13-4),<sup>10</sup> and Fishkind's horizontal overlap suture (Figure 13-5).<sup>11</sup>

In 1989, McFarland<sup>12</sup> utilized the corneal shelf incision architecture and recognized that these incisions sized for foldable IOLs allowed for the phacoemulsification and implantation of lenses without the need for suturing. This involved lengthening the scleral tunnel and, in his early attempts, creating partial-thickness grooves in the floor of the scleral tunnel parallel to the long axis of the tunnel so that the incision could be reversibly stretched to admit a foldable lens.



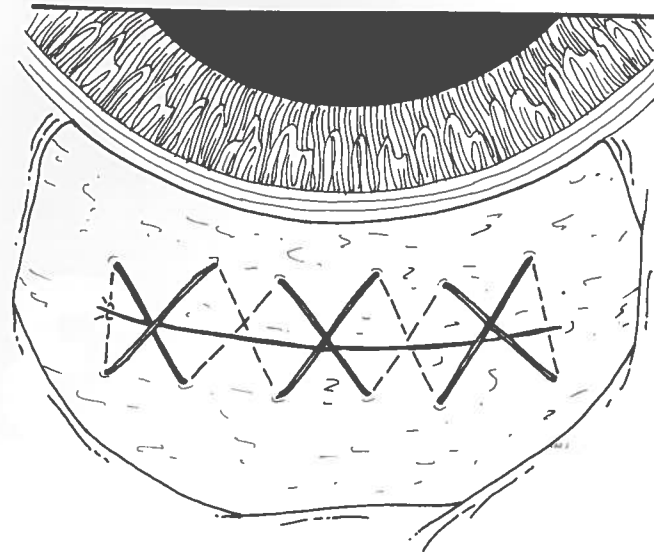


Figure 13-1 The scleral tunnel incision and running suture closure.

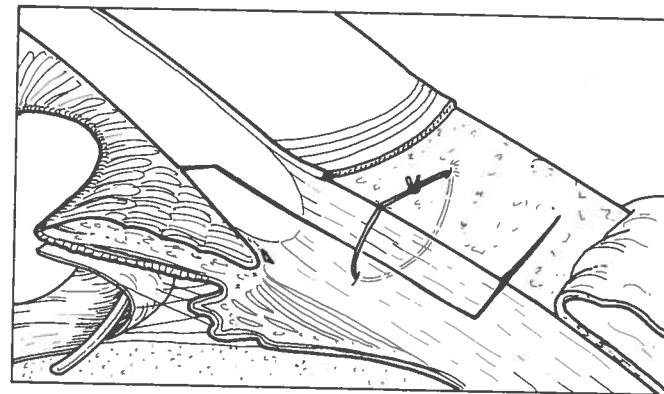


Figure 13-2 The single horizontal suture.

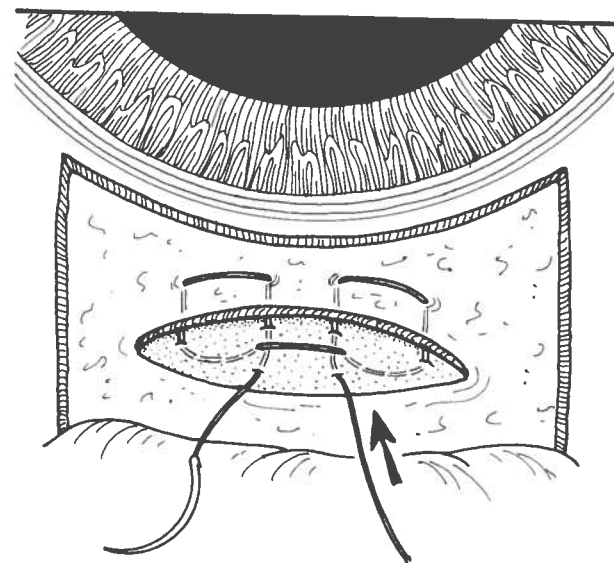


Figure 13-4 The horizontal anchor suture.

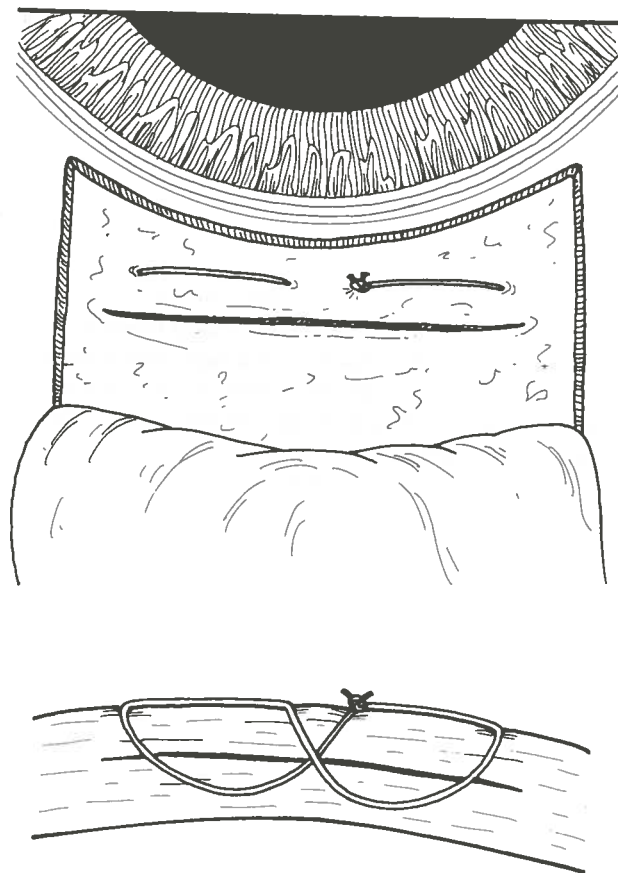


Figure 13-3 The infinity suture.

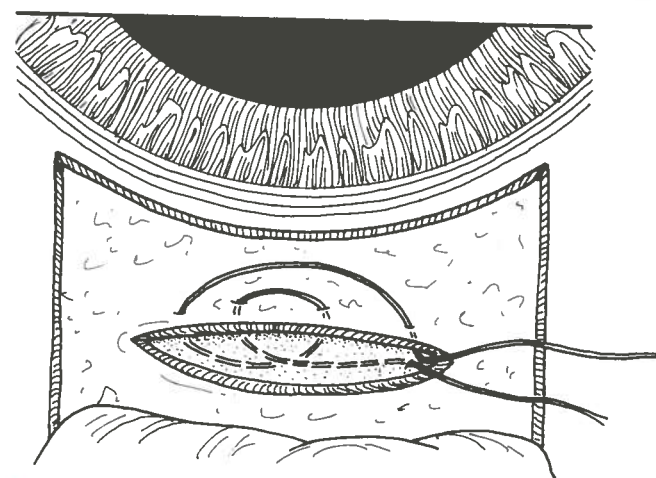


Figure 13-5 The horizontal overlap suture.

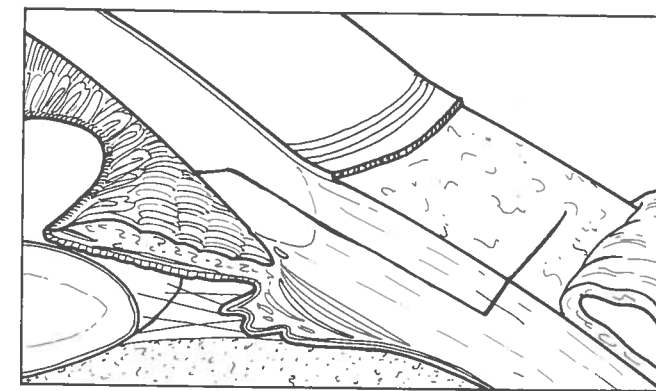


Figure 13-6 The self-sealing "corneal lip" scleral tunnel incision.

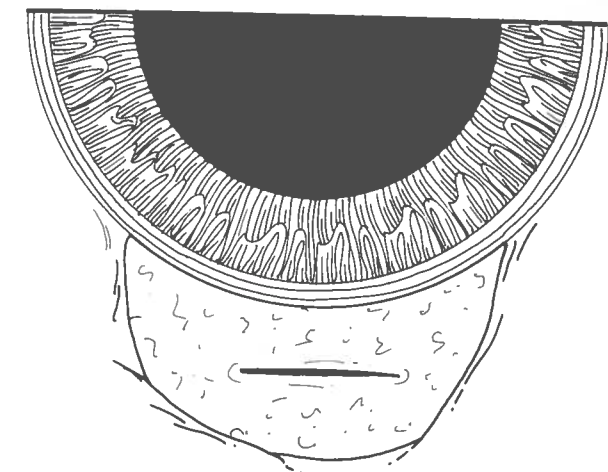


Figure 13-8 Scleral tunnel incision with straight groove.




Figure 13-7 Incisional funnel with two possible incisions illustrated: both astigmatism neutral.

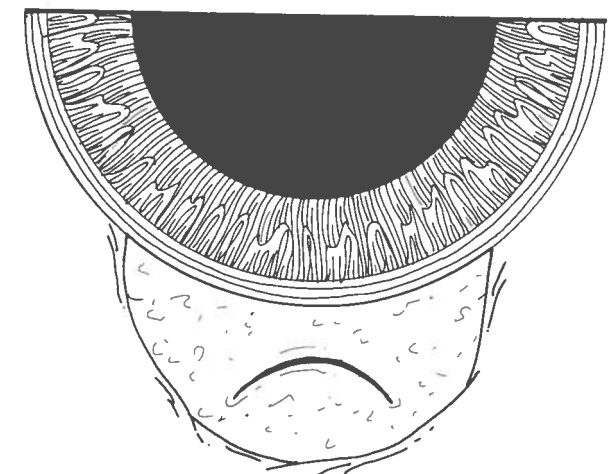


Figure 13-9 Frown incision.

Ernest<sup>13</sup> observed McFarland's surgery and recognized that McFarland's long scleral tunnel incision terminated in a decidedly corneal entrance and that the posterior lip of the incision, the so-called corneal lip, acted as a one-way valve imparting to this incision its self-sealing characteristics (Figure 13.6). Koch<sup>14</sup> described what he called the *incisional funnel* (Figure 13.7), indicating that there were certain characteristics of seal-sealing incisions with respect to length and configuration that imparted not only self-sealability, but also astigmatism neutrality to these incisions.

Self-sealing scleral tunnel incisions have varied with respect to width and the configuration of the groove (which represents the external or scleral incision as opposed to the internal or corneal portion of the incision). The groove has varied from circumlimbal to straight (Figure 13.8), frown (Figure 13.9) or chevron-shaped.<sup>15-18</sup>

### ■ SURGICAL TECHNIQUES FOR SCLERAL TUNNEL INCISIONS ■

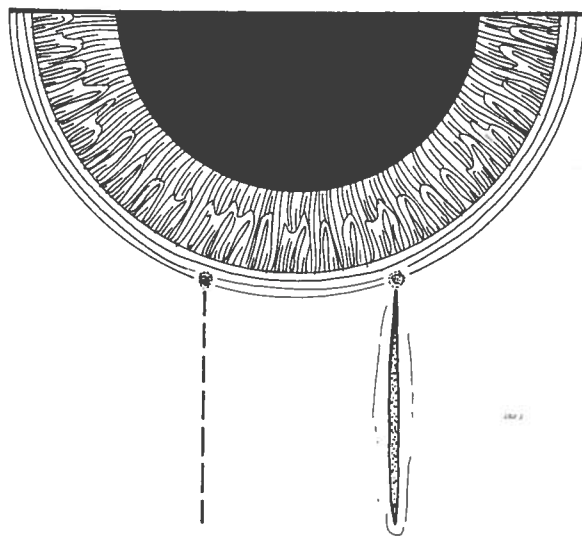
In the following passage, we describe in detail the construction of a self-sealing scleral tunnel incision using a straight external scleral

groove and a tunnel width of 4 mm, recognizing that the same tunnel can be made 7 mm wide with enlargement of the internal opening from 3 to 7 mm following completion of phacoemulsification and cortical cleanup, and just before lens implantation.

A conjunctival flap is made precisely by marking the width of the scleral tunnel at the limbus (Figure 13.10), and making vertical releasing incisions in the conjunctiva and Tenon's at exactly that width. These vertical releasing incisions extend back approximately 5 mm. The sub-tenon's space is bluntly dissected with a scissors (Figure 13.11) before a peritomy (Figure 13.12). After the peritomy, the conjunctiva-Tenon's flap is folded at its base upside down on top of the posterior conjunctiva. The peritomy leaves approximately a 0.5-1 mm lip of conjunctiva attached to the limbus. This acts as a buttress postoperatively to prevent anterior migration of the conjunctiva so that the flap never overhangs the limbus.

Mild cauterization is performed near the limbus. Posteriorly, however, heavier cauterization is used. The large vessels emanating from the rectus muscle and perforating the sclera between the muscle and the beginning of the tunnel are cauterized directly and adequately. (If these perforating vessels are cauterized before they enter the sclera, the tunnel should be dry during the entire

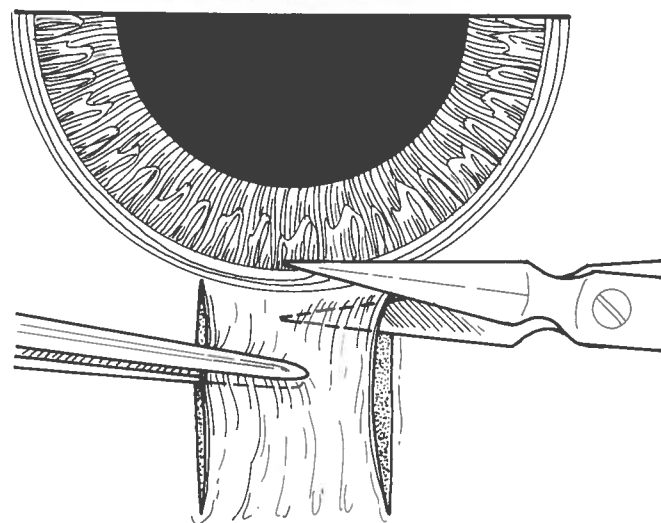




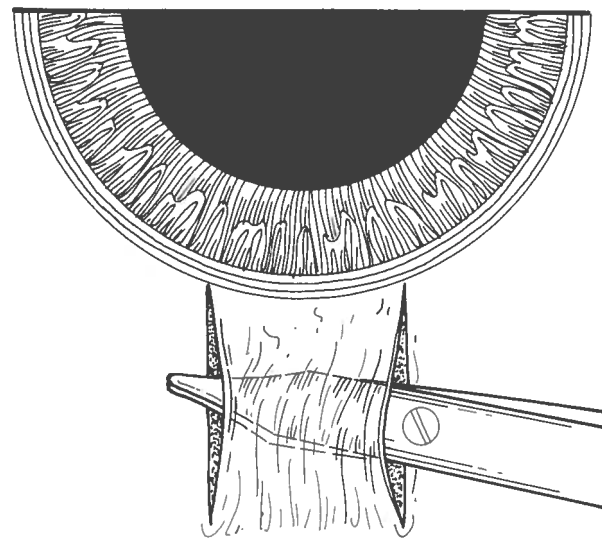
**Figure 13-10** Caliper marks on conjunctiva to indicate position of vertical releasing incisions.

procedure and there should be no bleeding either intraoperatively or postoperatively resulting in hyphema.)

Following cautery, a Fine millimeter marker (Rhein Medical No. 8-12106) is stamped in methylene blue and then pressed to the scleral bed, creating a  $5 \times 8$  mm grid of dots 1 mm apart starting 1 mm posterior to the anterior edge of the corneal vascular arcade (Figure 13-13). This allows selection of an incision length, location and shape with great precision and reproducibility.<sup>17</sup> The globe is fixated with a twist grip (Weck No. 7640) posteriorly in the area of bared sclera and the sclera is cut perpendicularly to make a groove by incising the appropriate dots (Figure 13-14). The groove is sufficiently deep that the surgeon can look down the groove and pick the depth within the sclera at which he or she will dissect the scleral tunnel. A slight anterior edge is elevated with the No. 64 Beaver blade that is used to make the groove, and from that point on an Alcon



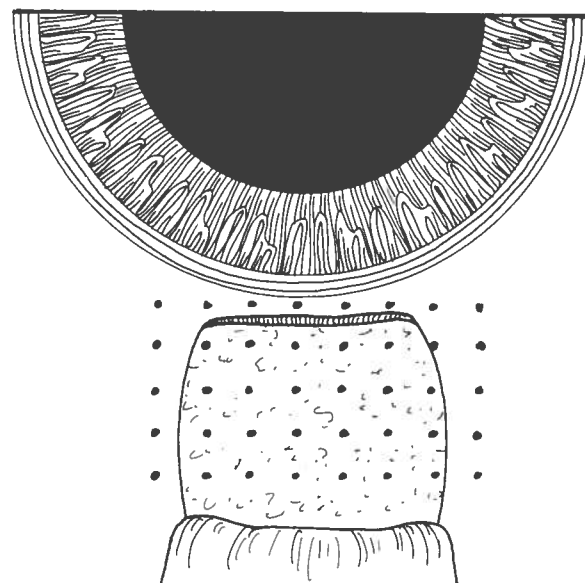
**Figure 13-12** Peritomy of the conjunctival flap.



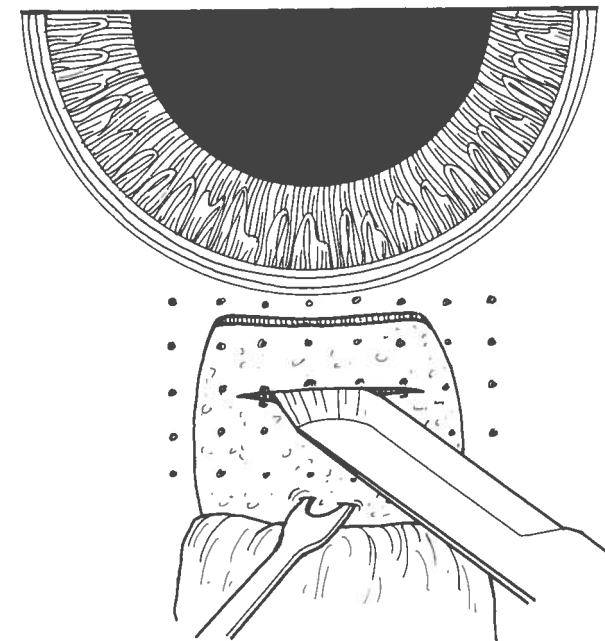
**Figure 13-11** Blunt dissection of sub-Tenon's space with closed scissors.

bevel-up crescent knife (Figure 13-15) (Alcon 8065-940002) is used to dissect the scleral tunnel. (It is important to keep the leading edge of the knife down, whether cutting anteriorly or to either side, as one moves the knife. This is a sharp knife that makes a very clean dissection in the scleral plane.) The dissection is carried forward to the Descemet's membrane at the anterior edge of the vascular arcade (Figure 13-16).

At this point, a side port is made with a trifacet freehand diamond knife (No. KOI KM218R). Viscoelastic is exchanged for aqueous humor through the side port by injecting the viscoelastic into the distal angle. As the expanding wave of viscoelastic moves towards the paracentesis, aqueous humor is expressed. This results in a very stiff and stable anterior chamber. A 3.5 mm keratome blade (Beaver No 5530) is lubricated with viscoelastic and brought into the tunnel. The blade is advanced so



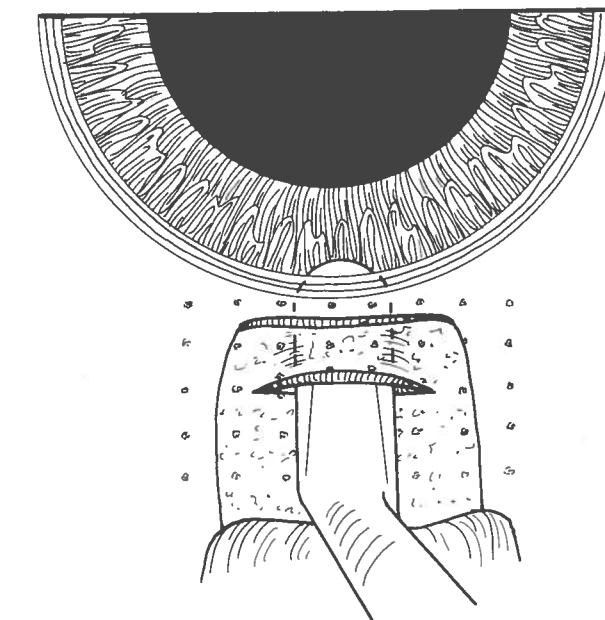
**Figure 13-13** Millimeter grid on bare scleral bed.



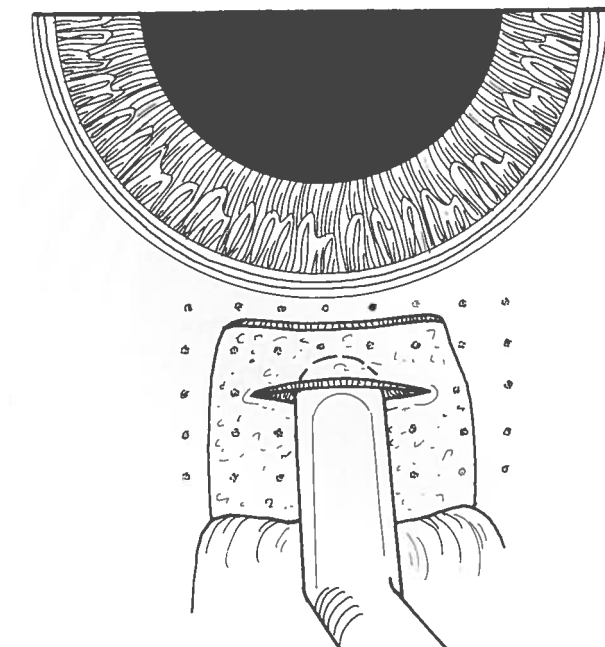
**Figure 13-14** Initiation of the groove or external incision.

that its point is just at the anterior edge of the vascular arcade. The point is tipped slightly posteriorly, resulting in a dimple on the anterior surface of the cornea, whose center is directly on the anterior edge of the arcade. The dimple is frequently outlined by a semicircular light reflex (Figure 13-17) with the tip of the keratome at the center. The keratome is then advanced horizontally, parallel to the iris, which results in a linear horizontal cut through Descemet's membrane into the anterior chamber, 0.5 mm anterior to the edge of the vascular arcade (Figure 13-18).

The surgeon must continuously guide the tip of the keratome as it is brought into the anterior chamber. If it is pointed too

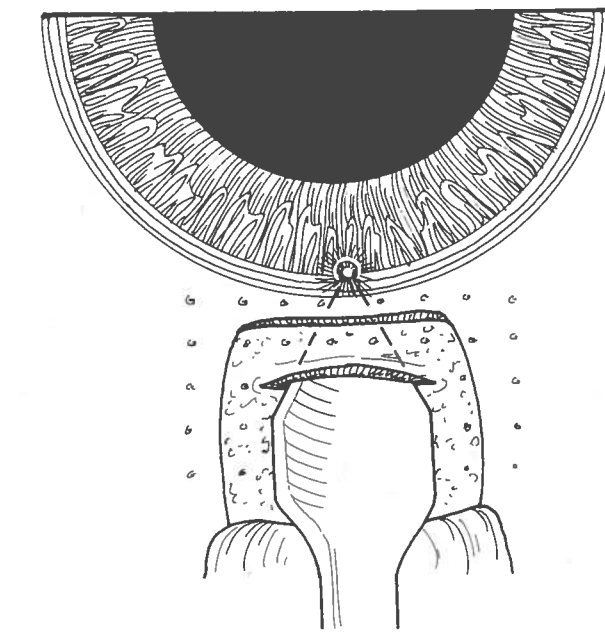


**Figure 13-16** Dissection of the scleral tunnel into clear cornea.



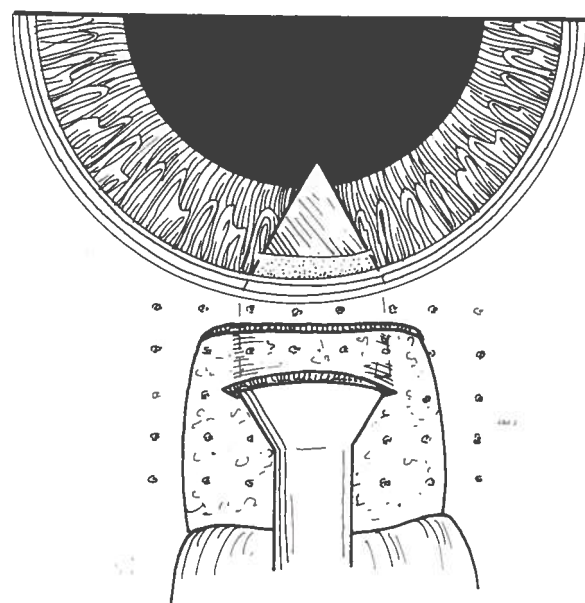
**Figure 13-15** Initiation of the tunnel with a crescent knife.

posteriorly, the cut in Descemet's membrane will start to curve posteriorly at the ends in a "frown" configuration. On the other hand, if the tip of the keratome is elevated too much, the cut in Descemet's membrane will start to curve forward in a "smile" configuration rather than proceeding straight across and parallel to the groove. If the keratome is tilted to one side or the other, an "S-shaped" configuration may result. In all instances, observation of the cut as it proceeds in Descemet's membrane by advancing the keratome can allow for correction of the orientation of the keratome. A straight cut in Descemet's membrane is necessary for the correct architecture of the incision.

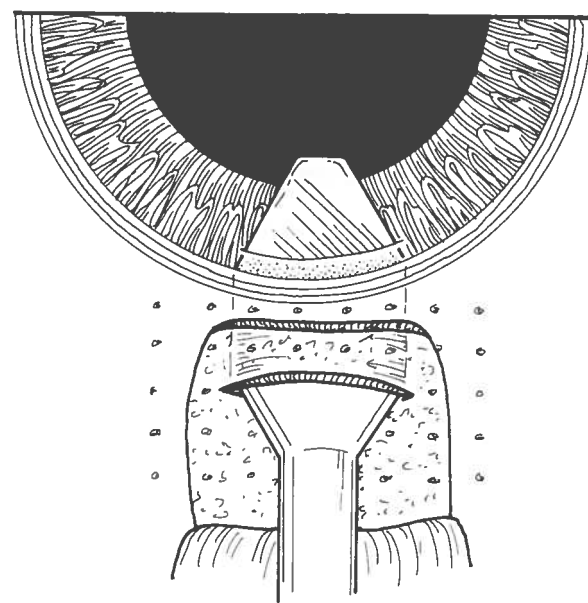


**Figure 13-17** Dimpling of the cornea by depressing the point of the keratome.





**Figure 13-18** Straight-line incision in Descemet's membrane 0.5 mm anterior to the vascular arcade.



**Figure 13-19** Enlargement of the 3.5 mm incision to 4.0 mm with a blunt-tipped keratome.

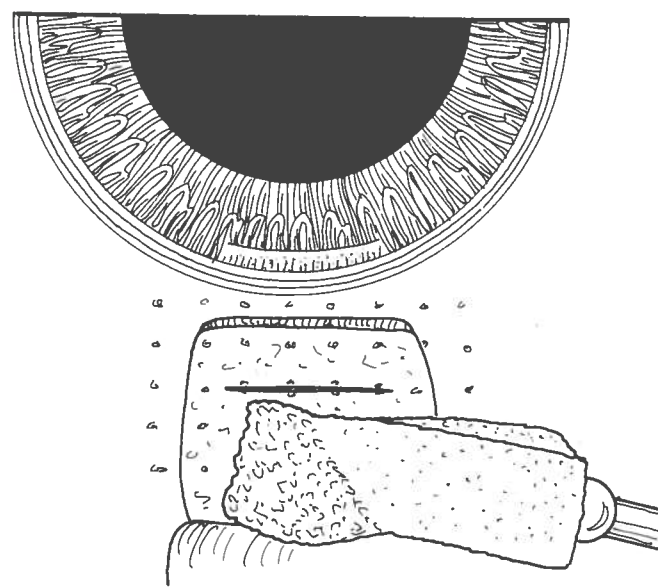
The incision is complete when the parallel shoulders of the keratome enter the anterior chamber. The incision can be characterized by the presence of a short posterior lip of clear cornea that acts as a one-way valve.<sup>19</sup> Following the completion of the case, this valve is held closed by intraocular pressure which also acts to collapse the scleral tunnel.

If one goes more anteriorly into clear cornea before incising Descemet's membrane, the visualization during phacoemulsification is markedly impaired because of the striae that occur as the phaco tip is tilted down for endolenticular phacoemulsification.

It is important to avoid putting traction on the roof of the scleral tunnel with a forceps. A bridle suture is used during incision construction and the twist grip is placed posterior to the dot grid to stabilize the globe during construction of the scleral tunnel. The forceps is used to elevate the tunnel roof in placing the keratome inside the tunnel, but countertraction is placed on the posterior lip of the groove rather than the anterior lip during the cutting of Descemet's membrane with the keratome.

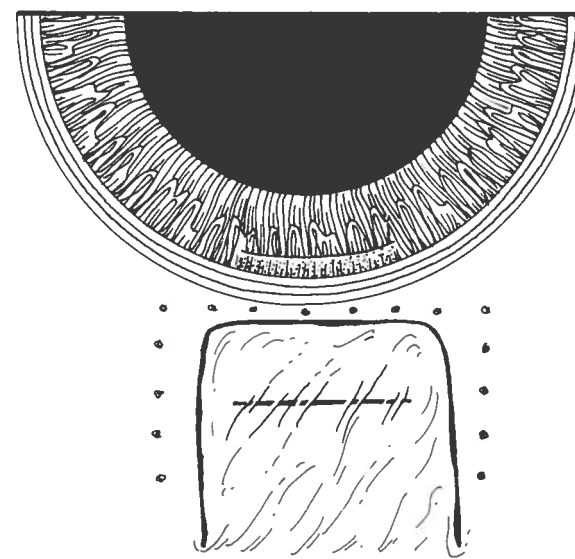
Phacoemulsification and later evacuation of viscoelastic take place with the bridle suture unattached to minimize stretching of the tunnel roof. After cortical cleanup and expansion of the bag with viscoelastic, the incision in Descemet's membrane is widened with a 4 mm blunt-tip keratome (Figure 13-19) (Beaver No. 374732) for folded silicone lenses. For 6 mm lenses, the initial keratome incision is enlarged with a super-sharp knife (15° Alcon ophthalmic knife No. 8065-921502) taking care to incise Descemet's membrane as a continuation of the straight-line cut made by the 3.5 mm keratome.

Following IOL implantation and evacuation of residual viscoelastic, the anterior chamber is fully repressurized with BSS through the side port. The lips of the wound are tested by applying pressure with a Weck cell sponge against the posterior lip of the wound (Figure 13-20) in an effort to make the incision leak.



**Figure 13-20** Testing the scleral incision for being watertight.

If it does leak, which happens less than 5% of the time, a single horizontal suture is placed (in the case of incisions 5 mm or larger, an infinity suture is placed). If no leakage is observed, the conjunctival flap is unfolded back over the incision and smoothed in place. Its corners are returned to the corners of the bed from which they were derived, up against the remaining lip of conjunctiva attached to the limbus (Figure 13-21). The flap is frequently adherent within 1 h, as observed in one-eyed patients who are not patched at the conclusion of surgery. A Maloney keratometer is used to estimate astigmatism at the conclusion of the surgery (Figure 13-22).<sup>15</sup>



**Figure 13-21** Conjunctival flap repositioned in its bed.

## DEVELOPMENT OF CLEAR CORNEAL INCISIONS

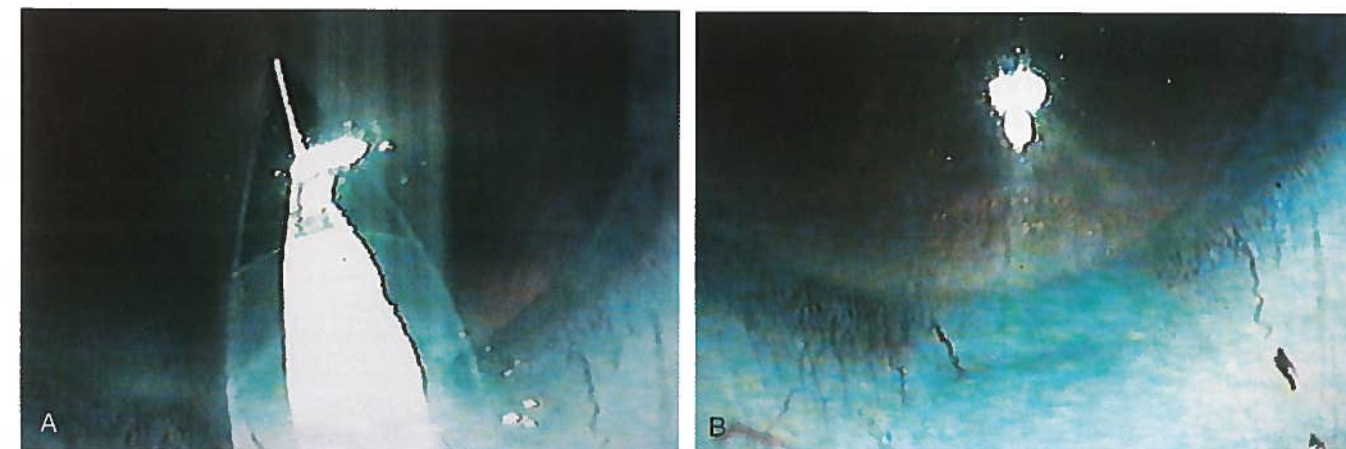
There have been many surgeons who have favored corneal incisions for cataract surgery prior to their recent popularization. In 1968, Kelman<sup>3</sup> stated that the best approach for performing cataract surgery was with phacoemulsification through a clear corneal incision utilizing a triangular-tear capsulotomy and a grooving and cracking technique in the posterior chamber. Harms and Mackenson<sup>20</sup> in Germany published an intracapsular technique using a corneal incision in 1967 in an atlas called *Ocular Surgery Under the Microscope*. Troutman was an early advocate of controlling surgically induced astigmatism at the time of cataract surgery by means of the corneal-incision approach.<sup>21</sup> Arnott<sup>22</sup> in England used clear corneal incisions and a diamond keratome for phacoemulsification, although he had to enlarge the incision for introducing an IOL. Galand<sup>23</sup> in Belgium utilized clear corneal incisions for extracapsular



**Figure 13-22** Estimation of corneal curvature using a Maloney intraoperative qualitative keratometer.

cataract extraction in his envelope technique and Stegmann of South Africa has a long history of having used the cornea as the site for incisions for extracapsular cataract extraction (Stegmann R. Personal communication, December 3, 1992). In April of 1992, Fine presented his self-sealing temporal clear corneal incision at the annual meeting of the American Society of Cataract and Refractive Surgery.<sup>24</sup> In May of 1992, at the Island Ophthalmology Seminar, Kellan demonstrated on video a technique that he referred to as the scleral-less incision. It was essentially a corneal limbal stab incision through conjunctiva and the limbus, entering the anterior chamber through clear cornea, leaving a corneal shelf or lip (Figure 13-23A and B). Finally, perhaps the leading proponent of clear corneal incisions for modern era phacoemulsification was Kimiya Shimizu of Japan.<sup>25</sup>

Fine's personal experience with corneal incisions began in 1979 when the temporal clear cornea was used as the site for secondary anterior chamber IOL implantation. The temporal



**Figure 13-23** A, Kellan's corneal limbal stab incision through conjunctiva and the limbus. B, Corneal limbal incision following removal of the steel keratome.



approach was preferred because of the unpredictable nature of the disturbed anatomy present at the superior limbus in eyes that had previous intracapsular cataract extraction. As soon as foldable lenses were available, in 1986, he used sutured clear corneal incisions for phacoemulsification and foldable IOL implantation in patients who had pre-existing filtering blebs. After these procedures, a marked reduction in surgically induced astigmatism was noted despite the fact that these incisions were corneal rather than scleral. In 1992, Fine began routinely utilizing clear corneal cataract incisions for phacoemulsification and foldable IOL implantation with incision closure using a tangential suture modeled after John Shepherd's technique.<sup>8</sup> Within a very short period, the suture was abandoned in favor of self-sealing corneal incisions.<sup>26</sup>

### INDICATIONS FOR CLEAR CORNEAL INCISIONS

Initially, the utilization of clear corneal incisions were limited to those patients with pre-existing filtering blebs, patients taking anti-coagulants or with blood dyscrasias, or patients with cicatrizing disease such as ocular cicatricial pemphigoid or Stevens-Johnson syndrome. Subsequently, because of the natural fit of clear corneal cataract incisions with topical anesthesia, the indications for clear corneal cataract surgery expanded. With the ability to avoid any injections into the orbit and utilization of intravenous medications, those patients who had cardiovascular, pulmonary, and other systemic diseases that might have contraindicated cataract surgery became surgical candidates. Subsequently, through the safety and increasing utilization of these incisions by some pioneers in the United States, including Williamson, Shepherd, Martin, and Grabow,<sup>27</sup> these incisions became increasingly popular and utilized on an international basis.

Studies by Rosen<sup>28</sup> using topographical analyses of these incisions demonstrated that clear corneal incisions sized 3 mm in width or less were topographically astigmatism-neutral. This led to an increasing interest in these incisions because of an increasing utilization of techniques including T-cuts, arcuate cuts, and limbal relaxing incisions for managing pre-existing astigmatism at the time of cataract surgery. Without astigmatism neutrality in the cataract incision, the predictability of adjunctive astigmatism-reducing procedures would be decreased, making it more difficult to achieve the desired result. In the initial studies and ultimate utilization of multifocal IOLs, the need for astigmatism neutrality was again a factor for stimulating interest in clear corneal incisions. Finally, the availability of phakic IOLs and the need for control of astigmatism at the time of implantation of these lenses has driven many surgeons to consider clear corneal incisions as the route for phakic IOL implantation.

Other advantages of the temporal clear corneal incision include:

- better preservation of pre-existing filtering blebs<sup>29</sup>
- preservation of options for future filtering surgery
- increased stability in the refractive results because of the neutralization of the forces from lid blink and gravity
- the ease of approach to the incision site
- the lack of need for bridle sutures and resultant iatrogenic ptosis
- the location of the lateral canthal angle under the incision which facilitates drainage.

### CLASSIFICATION OF CLEAR CORNEAL INCISIONS

Early on there was criticism surrounding the use of self-sealing clear corneal incisions because of the fear of a possible increase in the incidence of endophthalmitis secondary to poor wound healing and sealability. This potential controversy stimulated many studies into the strength and safety of clear corneal incisions compared to limbal and scleral tunnel incisions. Unfortunately, because of a lack of standardization in the definition of what constitutes a limbal versus clear corneal incision, considerable confusion has been generated in this area making it difficult for surgeons to communicate and compare the relative claims of their individual techniques. Based on Hogan's *Histology of the Human Eye*: "The conjunctival vessels are seen with the slit lamp as fine arcades that extend into clear cornea for about 0.5 mm beyond the limbal edge",<sup>30</sup> and topographical studies of incisions done by Menapace<sup>31</sup> in Vienna, Fine has categorized these incisions using the parameters of location and architecture.<sup>32</sup> An incision is termed *clear corneal* when the external edge is anterior to the conjunctival insertion, *limbal corneal* when the external edge is through conjunctiva and limbus, and *scleral corneal* when it is posterior to the limbus (Figure 13-24). In addition to the anatomic designation of the external incision, these incisions are also classified by their architecture as being *single plane* when there is no groove at the external edge of the incision, *shallow groove* when the initial groove is less than 400  $\mu$ , and *deeply grooved* when it is deeper than 400  $\mu$  (Figures 13-25 and 13-26). To reduce the confusion and facilitate communication regarding these incisions, we believe they should be classified as clear corneal, limbal corneal, or scleral corneal incisions and as single planed, shallow grooved, or deep grooved.

### PREOPERATIVE EVALUATION

Certain studies that may be of value as part of a preoperative work-up include endothelial cell counts in patients with endothelial dystrophies, and perhaps computerized corneal topography when refractive surgical procedures are going to be combined with cataract surgery in the management of pre-existing astigmatism. This is especially true when refractive and keratometric measurements do not coincide. There has been a recent trend

### Classification of Corneal Tunnel Incisions

#### Location

- **Clear Corneal Incision-**  
Entry anterior to conjunctival insertion
- **Limbal Corneal Incision-**  
Entry through conjunctival & limbus
- **Scleral Corneal Incision-**  
Entry posterior to the limbus

Figure 13-24 Classification of corneal tunnel incisions by external incision location.

### Classification of Corneal Tunnel Incisions

#### Architecture

- **Single Plane** (No groove)
- **Shallow Groove** (< 400  $\mu$ )
- **Deep Groove** (> 400  $\mu$ )

Figure 13-25 Classification of corneal tunnel incisions by wound architecture.

for surgeons to use fourth-generation fluoroquinolone drops four times per day for 3 days prior to the day of surgery.

### TECHNIQUES

Single plane incisions, as first described by Fine,<sup>33</sup> utilized a 3 mm diamond knife.

A Fine-Thornton 13 mm fixation ring (Mastel Instruments, Rapid City, SD) (Figure 13-27) stabilizes the globe and allows

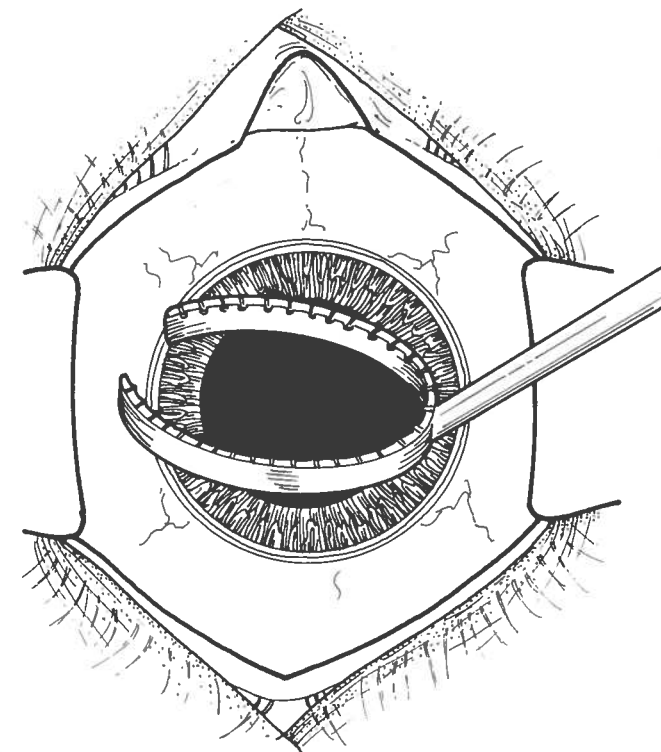


Figure 13-27 The Fine Thornton ring, shown in partial profile. Temporal limbus is seen inferiorly.

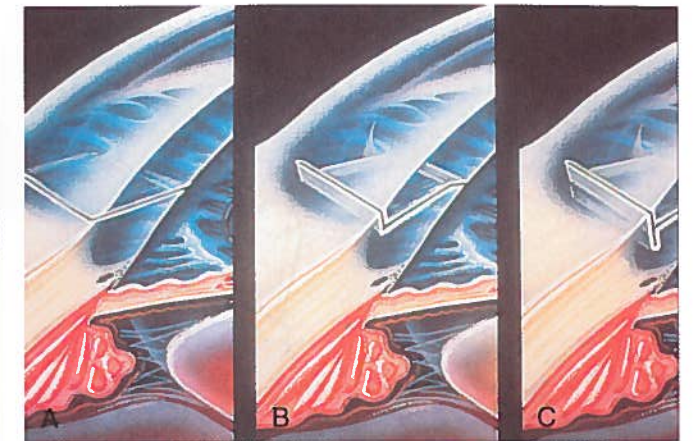


Figure 13-26 Cross-sectional view of single plane (A), shallow groove (B), and deep groove (hinged) clear corneal incisions (C).

manipulation without creating conjunctival tears, subconjunctival hemorrhages, or corneal abrasions (Figure 13-28). Aqueous humor is replaced by viscoelastic material through the side-port incision (Figure 13-29). After pressurization of the eye with viscoelastic, a 300 micron groove may be placed at the anterior edge of the vascular arcade (Figure 13-30), however, this is optional. If the groove has been placed, an incision is made by depressing the posterior edge of the groove with the diamond blade, flattening the blade against the surface of the eye. The knife is moved in

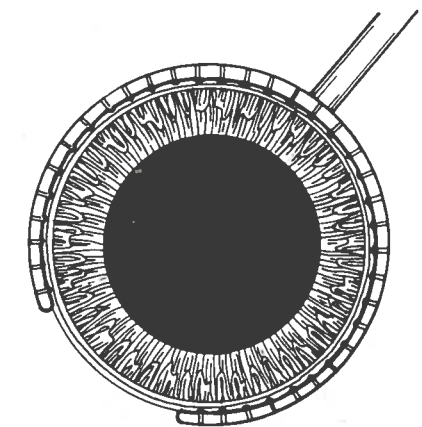


Figure 13-28 Purchase of the globe by the Fine-Thornton ring.

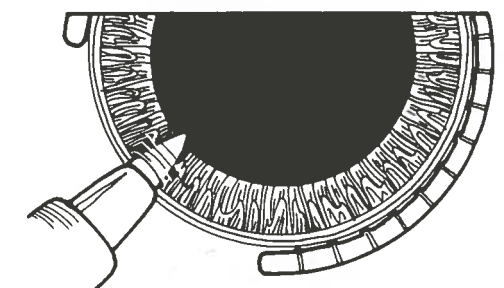


Figure 13-29 Paracentesis being made.



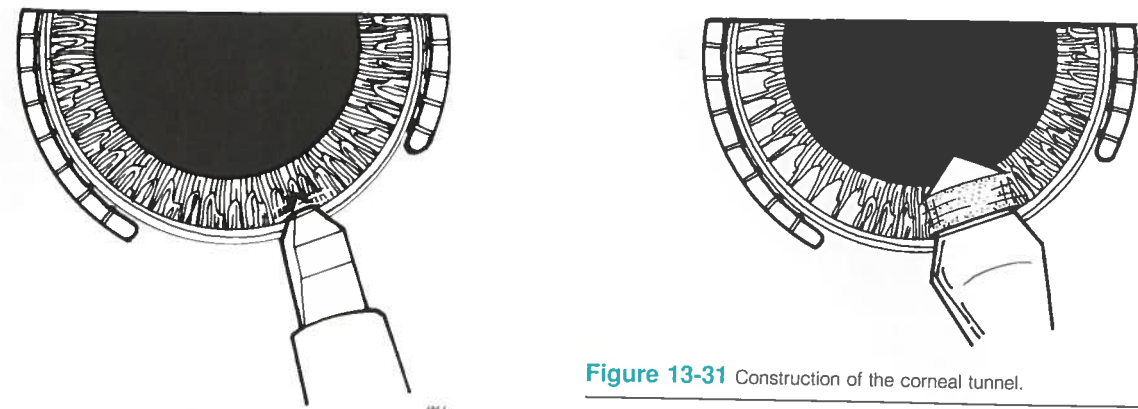


Figure 13-30 Grooving of the peripheral cornea.

the plane of the cornea until the shoulders, which are 2 mm posterior to the point of the knife, touch the external edge of the incision and then a dimple down technique is used to initiate the cut through Descemet's membrane. After the tip enters the anterior chamber, the initial plane of the knife is re-established to cut through Descemet's in a straight-line configuration (Figure 13-31). Following phacoemulsification, lens implantation, and removal of residual viscoelastic, stromal hydration of the clear corneal incision can be performed in order to help seal the incision.<sup>26</sup> This is performed by placing the tip of a 26- or 27-gauge cannula in the side walls of the incision and gently irrigating balanced salt solution into the stroma (Figure 13-32). This is performed at both edges of the incision in order to help appose the roof and floor of the incision. Once apposition takes place, the hydrostatic forces of the endothelial pump will help seal the incision. In those rare instances of questionable wound integrity, a single radial 10-0 nylon suture is placed to ensure a tight seal.

Williamson<sup>34</sup> was the first to utilize a shallow 300–400 micron grooved clear corneal incision. The rationale for the Williamson incision was that it led to a thicker external edge to the roof of the tunnel and less likelihood of tearing. Langerman<sup>35</sup> later described the single hinge incision in which requirements for the initial groove were 90% of the depth of the cornea anterior to the edge of the conjunctiva. Initially he utilized a depth of

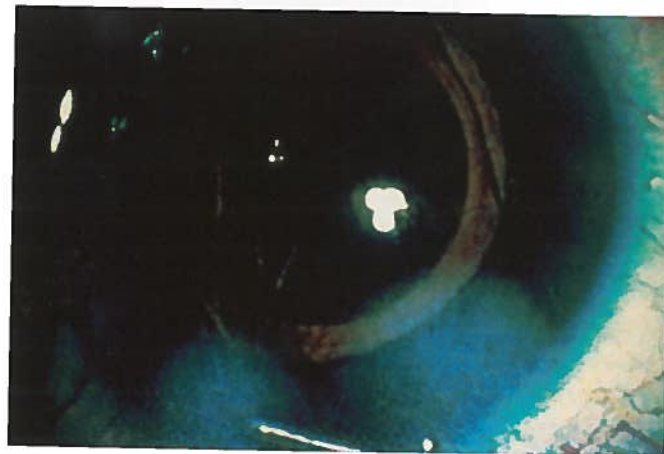


Figure 13-32 Stromal hydration of the incision.

Figure 13-31 Construction of the corneal tunnel.

600  $\mu$  and subsequently made the tunnel itself superficially in that groove, believing that this led to enhanced resistance of the incision to external deformation. Minimal differences in surgically induced astigmatism have been demonstrated between beveled and hinged clear corneal incisions.<sup>36</sup>

Adjunctive techniques were utilized to combine refractive surgery incisions with clear corneal cataract incisions. Until recently, Fine used the temporal location for the cataract incisions and added one or two T-cuts made by the Feaster Knife (Rhein Medical No. 05-8200) with a 7 mm ocular zone for the management of pre-existing astigmatism. Others, including Lindstrom and Rosen, rotated the location of the incision to the steep axis in order to achieve some increased flattening at the steepest axis to address pre-existing astigmatism. Kershner<sup>37</sup> utilized the corneal incision in the temporal half of the eye by starting with a nearly full-thickness T-cut through, which he then made his corneal tunnel incision. For large amounts of astigmatism he used a paired T-cut in the opposite side of the same meridian. Finally, the popularization of limbal relaxing incisions by Gills<sup>38</sup> and Nichamin<sup>39</sup> added an additional means of reducing pre-existing astigmatism by using the groove for the limbal relaxing incision as the site of entry for the clear corneal cataract incision. This has been found to be a simple and practical approach for reducing pre-existing astigmatism at the time of cataract surgery.<sup>40</sup> At this time, Fine places all of his incisions at the temporal periphery and addresses pre-existing astigmatism with limbal relaxing incisions at the steep axis and/or toric IOLs.

New technology blades have been developed which have helped perfect incision architecture. The Fine Triamond Knife (Mastel No. 0851913191) was developed in conjunction with Mastel Precision Instruments (Rapid City, SD) so that the incision could be made with an extremely sharp, thin and narrow knife without a necessity for dimpling down, which resulted in some tendency for there to be tearing of tissue or scrolling of Descemet's membrane. Subsequently, in conjunction with Rhein Medical (Tampa, FL), the 3-D blade (No. 05-5083) was developed, which had differential slope angles to the bevels on the anterior versus the posterior surface (Figures 13-33A, B, C) resulting in an ability to just touch the eye at the site of the external incision location and advance the blade in the plane of the cornea. The differential slopes on the anterior versus posterior aspects of the blade allowed the forces of tissue resistance to create an incision that

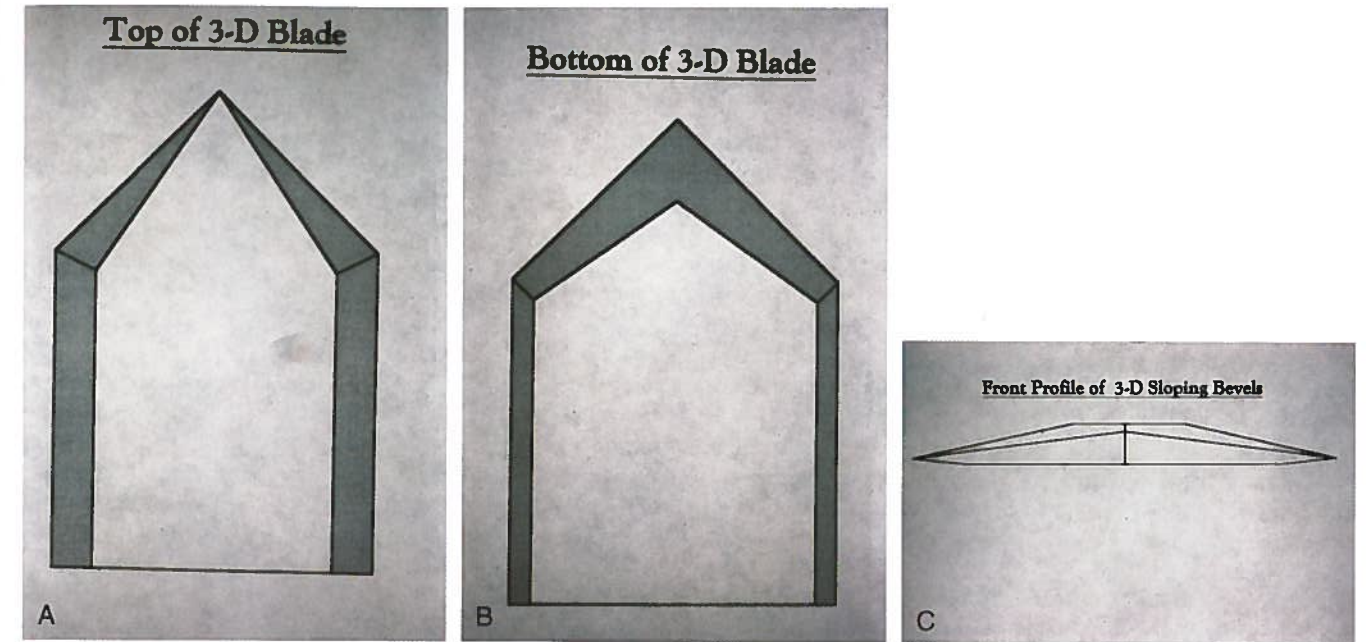


Figure 13-33 Schematic representation of top view (A) and bottom view (B) of the 3 mm Rhein 3-D diamond keratome. The front profile of the keratome (C) demonstrates the differential slopes on the anterior versus posterior aspects of the blade which allow the forces of tissue resistance to create the proper incision architecture.




Figure 13-34 The Rhein 3-D Trapezoidal Blade with 2.5–3.5 mm blade dimensions.

was characterized by a linear external incision, a 2 mm tunnel, and a linear internal incision without the need to dimple down or distort tissues to create the proper incision architecture.<sup>41</sup> The trapezoidal 3-D blade (Rhein No. 05-5086) also allows enlargement of the incision to 3.5 mm for IOL insertion without altering incision architecture (Figure 13-34). Histologic studies of clear corneal incisions performed with steel keratomes and diamond keratomes have shown more disruption of corneal stromal tissue with steel keratomes and more likelihood of severe stromal damage after insertion of foldable IOLs, suggesting that diamond keratomes may have a beneficial effect on incision healing.<sup>42,43</sup>

Many companies, in addition to Rhein Medical, are designing diamond knives for clear corneal incisions. Mastel Precision Surgical Instruments have designed a sleek trapezoidal blade that

they have named the Superstealth (Figure 13-35). The Stealth blade is an ultra-thin diamond with asymmetric facets that result in a self-directing bevel similar to the Rhein 3-D blade. ASICO (American Surgical Instruments Company, Westmont, Illinois) has designed two new diamond knives for clear corneal incisions: the Pathfinder (Figure 13-36) and the Clearpath (Figure 13-37). Both blades contain a shelf on the surface of the blade that creates an inner corneal valve of consistent length by forcing the leading



Figure 13-35 Mastel Trapezoidal Diamond Stealth Blade.





Figure 13-36 ASICO Pathfinder Blade.



Figure 13-37 ASICO Clearpath Blade.

edge of the blade into the anterior chamber when the shelf reaches the external incision. Stromal hydration of the wound is claimed to be unnecessary with the Clearpath blade due to the facet design.

A recent study by Mamalis<sup>44</sup> has revealed small predictable enlargements of clear corneal incisions after insertion of foldable IOLs with both forceps and injectors. The degree of wound enlargement increased with higher IOL powers when lenses were inserted with forceps but did not increase with increasing IOL powers when injectors were used. In general, injectors were associated with a smaller percentage increase in wound stretching than forceps, making them a preferable choice for foldable lens insertion through clear corneal incisions.

### INTRAOPERATIVE AND POSTOPERATIVE COMPLICATIONS

Although clear corneal and scleral incision cataract surgery share many of the same intraoperative and postoperative complications, clear corneal incisions, by nature of their architecture and location, have some unique complications associated with them. If one accidentally incises the conjunctiva at the time of the clear corneal incision, ballooning of the conjunctiva can develop, which may compromise visualization of anterior structures. When this develops, the use of a suction catheter is usually required by the assistant to aid in visualization. Early entry into the cornea might result in an incision of insufficient length to be self sealing, and thus a single suture may be required in order to ensure a secure wound at the conclusion of the procedure. A late entry may result in a corneal tunnel incision sufficiently long that the phacoemulsification tip would create striae in the cornea and compromise

visualization of the anterior chamber. In addition, incisions that are too short or improperly constructed can result in an increased tendency for iris prolapse.

Manipulation of the phacoemulsification handpiece intraoperatively may result in tearing of the roof of the tunnel, especially at the edges, potentially compromising the ability for the incision to self seal. Tearing of the internal lip can also occur, resulting in compromised self-sealability or, in rare instances, small detachments or scrolling of Descemet's membrane in the anterior edge of the incision. Of greater concern has been the potential for incisional burns.<sup>45,46</sup> When incisional burns develop in clear corneal incisions, there may be a loss of self-sealability, corneal edema, and severe induced astigmatism.<sup>47</sup> In addition, manipulation of the incision can result in an epithelial abrasion which can compromise self-sealability because of the lack of a fluid barrier by an intact epithelium. Without an intact epithelial layer, the corneal endothelium does not have the ability to help appose the roof and floor of the incision through hydrostatic forces.

Postoperatively, hypotony might result in some compromised ability for these incisions to seal. Wound leaks and iris prolapse have been very infrequent postoperative complications<sup>48</sup> and are usually present in incisions greater than 3.5 mm in width. In a large survey performed for the American Society of Cataract and Refractive Surgery by Masket and Tennen,<sup>49</sup> there was a slightly increased incidence of endophthalmitis in clear corneal cataract surgery compared to scleral tunnel surgery. However, the survey failed to note the incision sizes in those cases where endophthalmitis in clear corneal incisions had occurred, and thus it is possible that any increase in the incidence of endophthalmitis is associated with unsutured clear corneal incisions greater than 4 mm in width.

### POSTOPERATIVE CLINICAL COURSE AND OUTCOMES

The usual postoperative regime involves examination on the first postoperative day and a second examination at 10 to 14 days at which time spectacle correction is prescribed. Use of drops postoperatively includes instillation two to three times a day of a fluoroquinolone, prednisolone acetate and a topical non-steroidal anti-inflammatory drug (NSAID). The antibiotic and steroid are discontinued at 10 to 14 days and the NSAID is continued for an additional 10 days.<sup>50</sup>

Numerous studies have been performed documenting the safety and low magnitudes of astigmatism induced by these incisions depending on their size. Masket and Tennen<sup>51</sup> have documented by vector analysis 0.50 diopter (D) of induced cylinder and less than 0.25 D of cylinder change in the surgical meridian using 3.0 × 2.5 mm self-sealing temporal clear corneal incisions. They were also able to demonstrate the refractive stability of these incisions 2 weeks following surgery. Kohnen, Dick, and Jacobi<sup>52</sup> compared the surgically induced astigmatism of 3.5, 4, and 5 mm grooved temporal clear corneal incisions and found a mean induced astigmatism of 0.37 D, 0.56 D, and 0.70 D respectively after 6 months. A similar study by Pflieger et al.<sup>53</sup> revealed even smaller amounts of induced astigmatism from 3.2, 4, and 5.2 mm temporal clear corneal incisions with the 3.2 mm incision demonstrating astigmatic neutrality with only 0.09 D of induced cylinder.

In addition to comparing the effects of different-sized temporal clear corneal incisions on induced astigmatism, numerous studies have evaluated the relative astigmatic effects of incision location in regard to clear corneal incisions versus corneoscleral incisions, and of the temporal versus superior meridian. Nielsen<sup>54</sup> evaluated surgically induced astigmatism from 3.5 mm and 5.2 mm temporal and superior clear corneal incisions, and compared them with 3.5 mm and 5.2 mm corneoscleral incisions at the superior location. The 3.5 mm clear corneal incisions induced roughly 0.5 D of with-the-rule or against-the-rule drift, depending on temporal or superior location. Larger amounts of astigmatism were induced with the larger clear corneal incisions. He found that the refractive effect of clear corneal incisions was stable between postoperative day 1 and postoperative week 6, making their astigmatic keratotomy effect more useful and predictable if one wished to consider preoperative cylinder when selecting incision type or location.

Cillino et al.<sup>55</sup> compared the astigmatic effects of unsutured 5.2 mm temporal clear corneal incisions with 5.2 mm superior corneoscleral incisions and found comparable amounts of induced astigmatism. Rainer et al.,<sup>56</sup> however, has found a small but significant amount of surgically induced astigmatism continuing up to 5 years postoperatively with 5 mm superior scleral incisions. Although the use of unsutured 5.2 mm clear corneal incisions is considered unsafe because of a possible increase in rates of wound complications and endophthalmitis, Holweger and Marefat<sup>57</sup> have demonstrated that absorbable sutured 5-clear corneal incisions were topographically comparable to 3.5 mm sutureless clear corneal incisions, 6–8 months postoperatively, making this incision and closure technique a viable option for surgeons.

When temporal clear corneal incisions of 3.2 mm or less have been compared with superiorly placed scleral tunnel incisions of the same size, similarly low numbers of induced astigmatism have been documented for the two incision locations.<sup>58,59</sup> In contrast,

similarly sized incisions when compared in regard to temporal versus superior clear corneal location have demonstrated more meridional flattening in the superior axis than the temporal axis.<sup>60–62</sup> This has also been demonstrated in the oblique superolateral clear corneal incision compared with a temporal incision, confirming the bias for the temporal location for clear cornea incisions when astigmatic neutrality is desired.<sup>63</sup>

Although small clear corneal incisions appear to have similar astigmatic effects as superior corneoscleral incisions, recent concern has surrounded the possibility of increased endothelial cell loss with these incisions. Grabow<sup>64</sup> reported an increased incidence of endothelial cell loss for superior clear corneal incisions, which increased linearly with increasing ultrasound times. Amon et al.<sup>65</sup> discovered a significant increase in endothelial cell loss in 3.5 mm temporal clear corneal incisions when compared to 3.5 mm superior scleral tunnel incisions. However, a recent study by Dick et al.<sup>66</sup> found that the total endothelial cell loss at 1 year with clear corneal incisions compared favorably with endothelial cell loss rates of other cataract extraction techniques. As ultrasound times decrease in the future with advancing technologies and techniques, such as lens chopping and the use of power modulations,<sup>67</sup> endothelial cell loss rates should become insignificant.

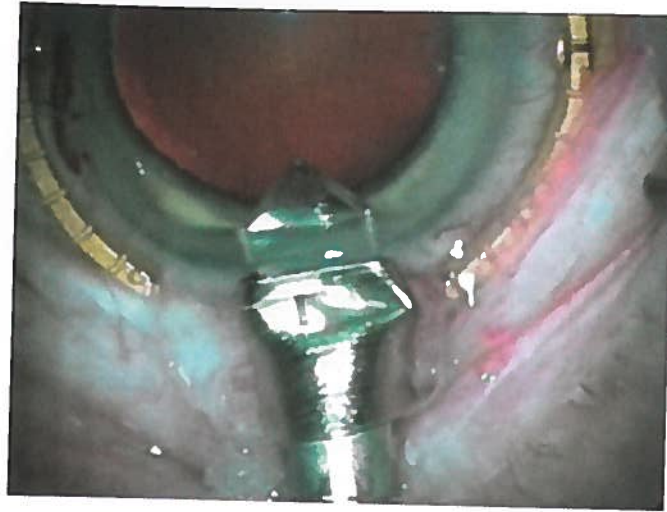
Dick et al.<sup>68</sup> have also recently demonstrated that cataract extraction through a clear corneal incision results in less inflammation in the immediate postoperative period when compared to surgery through a sclerocorneal incision. This may ultimately have a beneficial effect in reducing posterior capsule opacification, cystoid macular edema, and keratopathy.

### PROFILES OF CLEAR CORNEAL INCISIONS

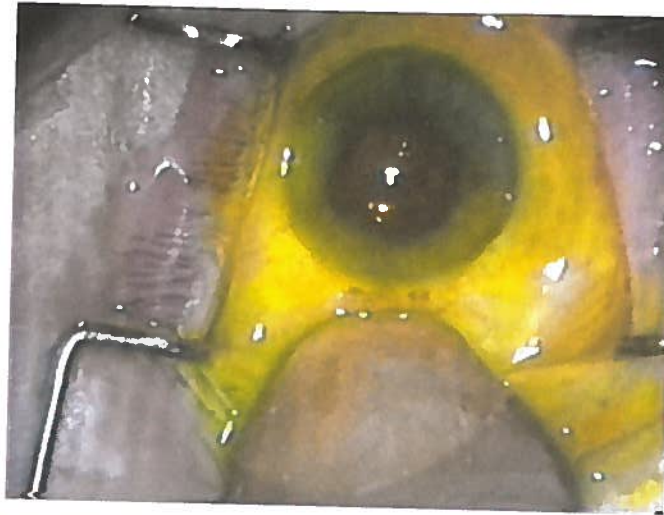
Clear corneal incisions involving an incision in the plane of the cornea with a length equal to 2 mm are still being constructed in the same manner today. In 1992, the incisions were as wide as 4 mm, but have more recently been reduced to a maximum width of 3.5 mm, if not sutured. Figure 13-26 shows an artist's view of what the profile of clear corneal incisions were thought to look like. Part A shows the single plane incision and its apparent inherent lack of stability as one surface can easily slide over another. Charles Williamson, MD, from Baton Rouge, innovated an alteration of that incision which involves a shallow, perpendicular groove prior to incising the cornea into the anterior chamber (Part B). David Langerman, MD, deepened the perpendicular groove with the belief that it led to greater stability (Part C). These grooved incisions have been abandoned by the authors in favor of a paracentesis-style incision due to the difficulties associated with a persistent foreign body sensation in the grooved incisions and the pooling of mucus and debris in the gaping groove. More importantly, the grooved incisions represent a disruption in the fluid barrier that intact epithelium create, which allows for a vacuum seal as a result of endothelial pumping.

Initial incision construction technique began with a blade applanated to the surface of the eyeball with the point at the edge of the clear cornea, which advanced for 2 mm into the plane of the cornea before incising Descemet's membrane (Figure 13-38). These early incisions were made with knives with straight sides; however, these knives were subsequently replaced by trapezoidal-





**Figure 13-38** Clear corneal incision construction with the blade completely inserted.



**Figure 13-39** Testing the seal of the incision with a Seidel test using fluorescein and tactile pressure.

shaped knives in order to allow the enlargement of the incision without violating the architecture by cutting sideways. From the onset of the use of clear corneal incisions, stromal hydration of the incisions, which thickens the cornea, forcing the roof of the incision onto the floor of the incision and facilitating endothelial pumping to the upper reaches of the cornea, was strongly advocated. Testing the seal of the incision with a Seidel test using fluorescein (Figure 13-39) was also strongly advocated. These practices have not changed since 1992, except that we now infrequently depress the posterior lip of the incision.

To obtain a better understanding of the architecture of clear corneal incisions, the authors conducted a study of the profiles of clear corneal incisions using the Zeiss Visante Optical Coherence Tomography (OCT) Anterior Segment Imaging System (Figure 13-40). This technology has allowed the first view of the clear corneal incision in the living eye in the early postoperative period. All previous views were in autopsy eyes sectioned



**Figure 13-40** The Zeiss Visante Optical Coherence Tomography Anterior Segment Imaging System.

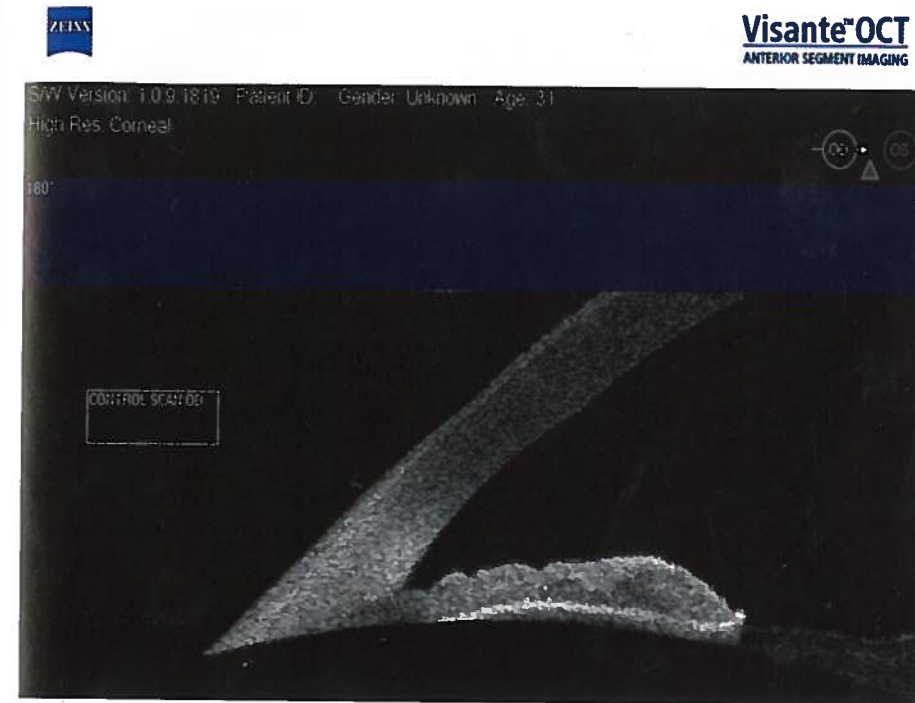
through the incision, which introduces artifacts. Figure 13-41 shows an example of the corneal periphery in a control eye which includes the anterior chamber angle. The regularity of the corneal epithelium blending in the conjunctiva and the clear corneal stroma blending into sclera can be clearly seen.

A variety of knives were used to create the clear corneal incisions during cataract surgery. All clear corneal incisions were made by one surgeon (IHF). OCT images of each operative eye were taken on the first postoperative day, within 24 h of cataract surgery and are representative of multiple images from multiple patients.

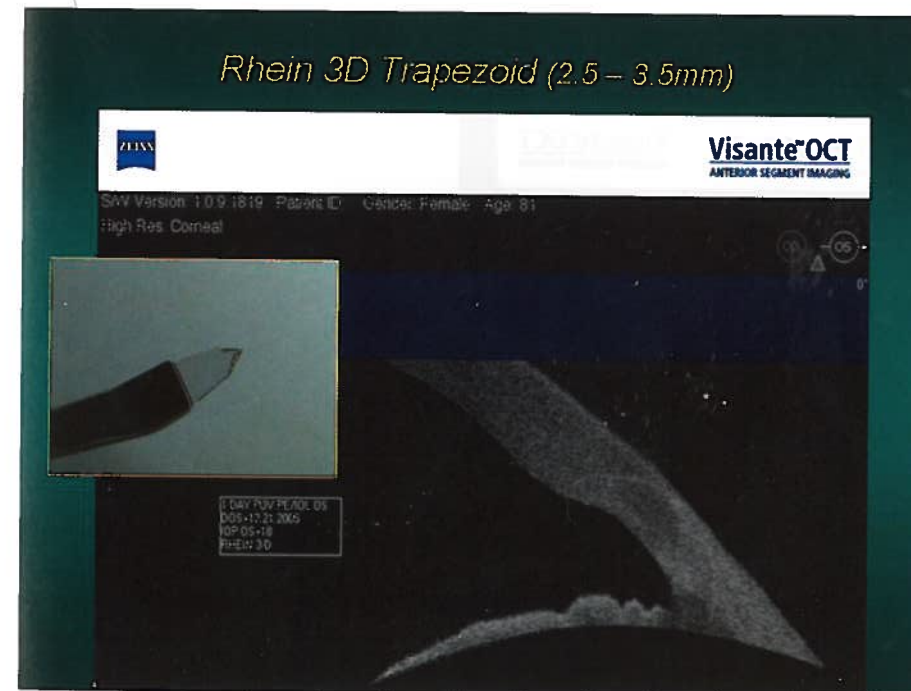
As seen in Figure 13-42, which was taken on the first day postoperatively, the clear corneal incision is actually curvilinear, not a straight line, as seen in the artist's depiction of clear corneal incisions (Figure 13-26). It is an arcuate incision which is considerably longer than the chord length originally estimated for the length of the incision. It is very important to note that the architecture of the incision allows for a fit not unlike tongue and groove paneling, which adds a measure of stability to these incisions and makes sliding of one surface over the other considerably less likely. Figure 13-43 shows an incision that was made with a 300 micron groove at the external edge of the incision prior to incision construction. The incision itself still has a similar curved or arcuate configuration, but the gaping of the external groove, which is noted on the first day postoperatively, is accompanied by a similar offset of the internal lips of the incision, which appears to be somewhat less stable than a paracentesis-style incision.

These images also demonstrate the persistence of stromal swelling from stromal hydration on the first postoperative day, which many critics of clear corneal incisions believed disappeared within 1 or 2 h.

Figure 13-44 shows a clear corneal incision made with the Rhein Medical (Tampa, FL), the Rhein 3D Trapezoidal blade, 2–2.5 mm (#05-5088), for incision construction using single-piece acrylic lenses with a Royale injector (ASICO, LLC, Westmont, IL, #AE-9045). Once again, the very advantageous architecture of the incision is observed. It is interesting to note that the arc length is considerably longer than the chord length and is probably a hyper-square incision in that it is only 2 mm wide. As Figures 13-45–48



**Figure 13-41** OCT image of a control eye showing the corneal periphery including the anterior chamber angle.



**Figure 13-42** OCT image of a clear corneal incision made with the Rhein 3D Trapezoidal 2.5–3.5 mm Blade. Image of the blade is inset.

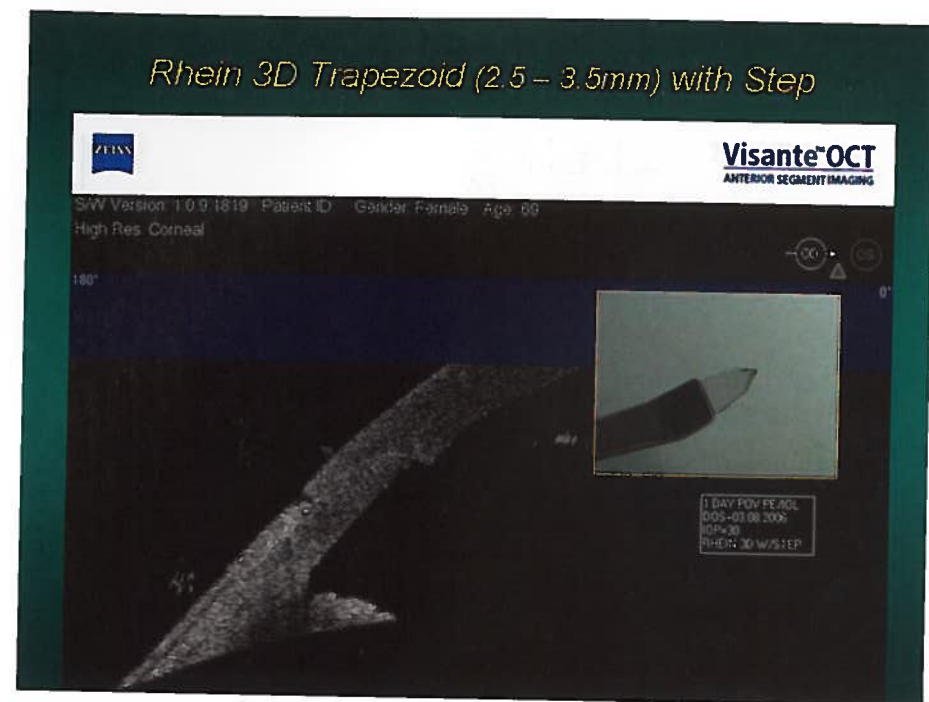
demonstrate, all clear corneal incisions made with a variety of blades demonstrated a similar, arcuate architecture.

The BD Kojo Slit (BD Medical-Ophthalmic Systems, Franklin Lakes, NJ, #372032) is a blade that is curved in the direction of the width of the incision. This creates an arcuate incision paralleling the curvature of the peripheral cornea with a chord length whose width is considerably smaller than the incision itself, which may add a greater degree of stability. The first few times that this blade is used, its unusual configuration makes it somewhat more difficult to create an incision in the plane of the cornea and the

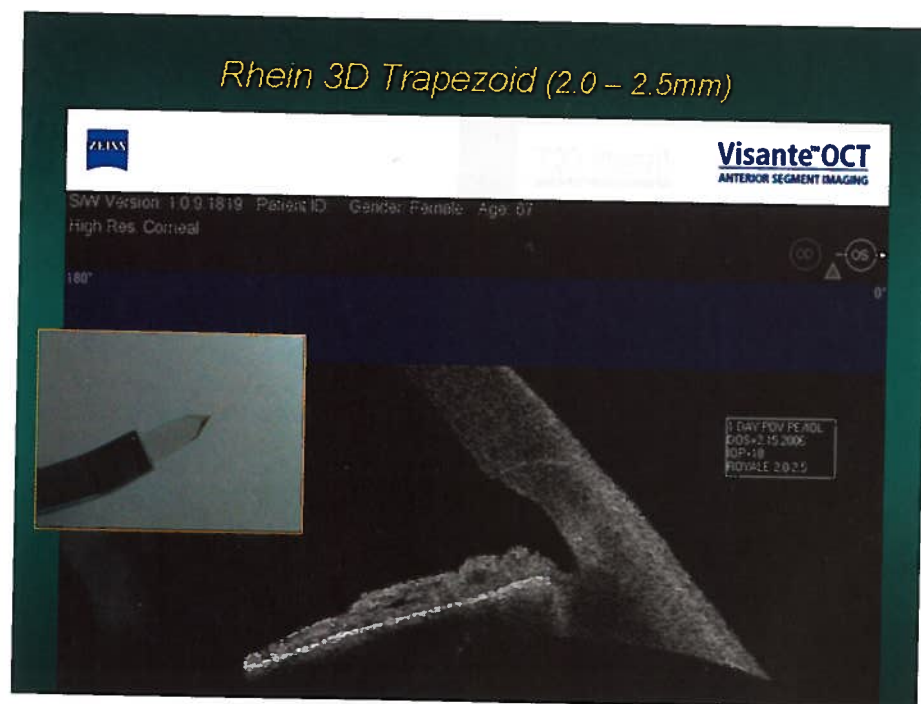
incision can end up considerably shorter than anticipated (see Figures 13-49 and 13-50). However, as one learns how to use this blade, the desired architecture is much easier to achieve (Figure 13-51).

One of the surprising findings was that proper incision construction resulted in a longer incision than the chord length that was measured and in greater stability (like tongue in groove paneling) of the incision. Another surprising finding was that stromal swelling does, indeed, last for at least 24 h. These findings demonstrate those characteristics that have contributed to





**Figure 13-43** OCT image of a clear corneal incision with a 300 micron groove at the external edge of the incision. Image of the Rhein 3D blade is inset.



**Figure 13-44** OCT image of a clear corneal incision made with the Rhein 3D Trapezoidal 2–2.5 mm Blade. Image of the blade is inset.

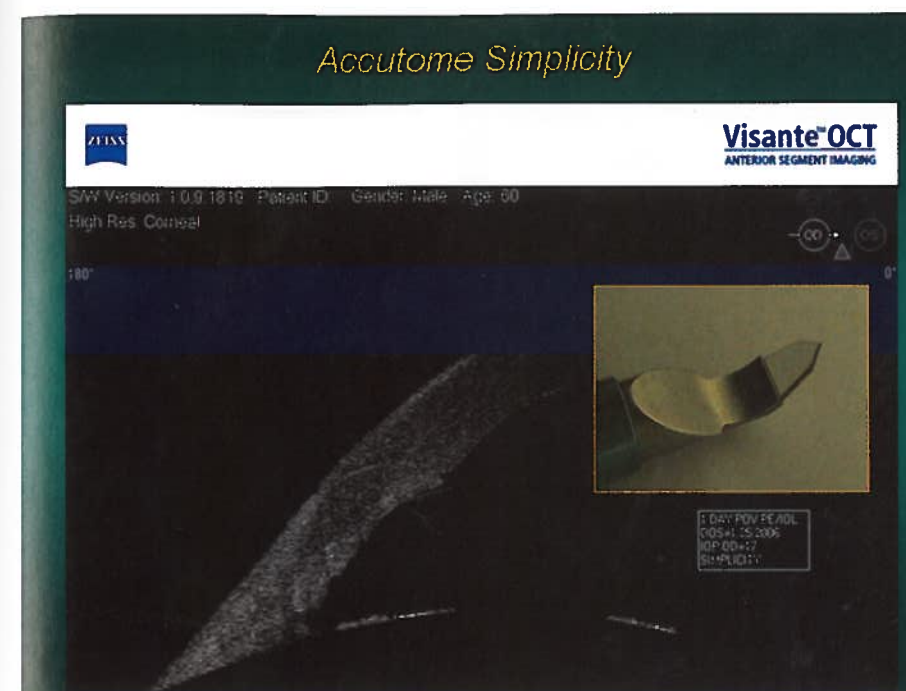
an added measure of safety in clear corneal incisions that can result in the absence of endophthalmitis.

## ■ CONTROVERSIES SURROUNDING CLEAR CORNEAL INCISIONS ■

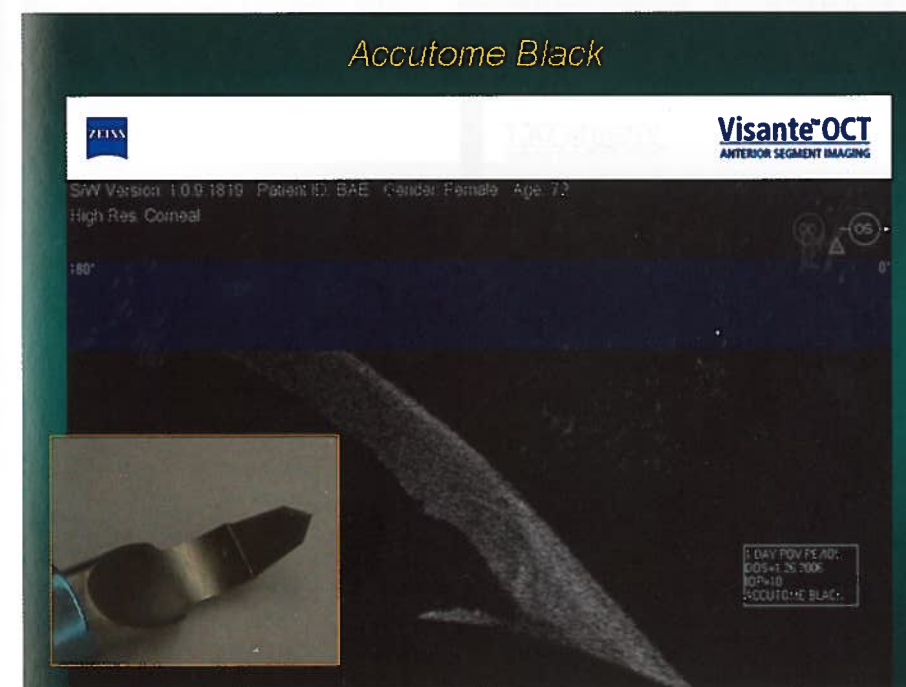
One of the most controversial criticisms of clear corneal incisions has been their relative strength compared to limbal or scleral incisions. Ernest et al.<sup>69,70</sup> demonstrated that rectangular clear corneal incisions in cadaver eye models were less resistant to external

deformation utilizing pinpoint pressure than were square limbal or scleral tunnel incisions. Subsequently, Mackool and Russell<sup>71</sup> demonstrated that once the incision width was  $\leq 3.5$  mm and the length  $\geq 2$  mm, there was an equal resistance to external deformation in clear cornea incisions as compared to scleral tunnel incisions. In Ernest's work as well, as incision sizes became increasingly small, the force required to cause failure of these incisions became very similar for limbal and clear corneal incisions, and thus this could be used to further document the safety of incisions sized 3 mm or less.

A major criticism of these cadaver studies is that there is a lack of functioning endothelium contributing to wound sealing. Others



**Figure 13-45** OCT image of a clear corneal incision made with the Accutome Simplicity Blade. Image of the blade is inset.



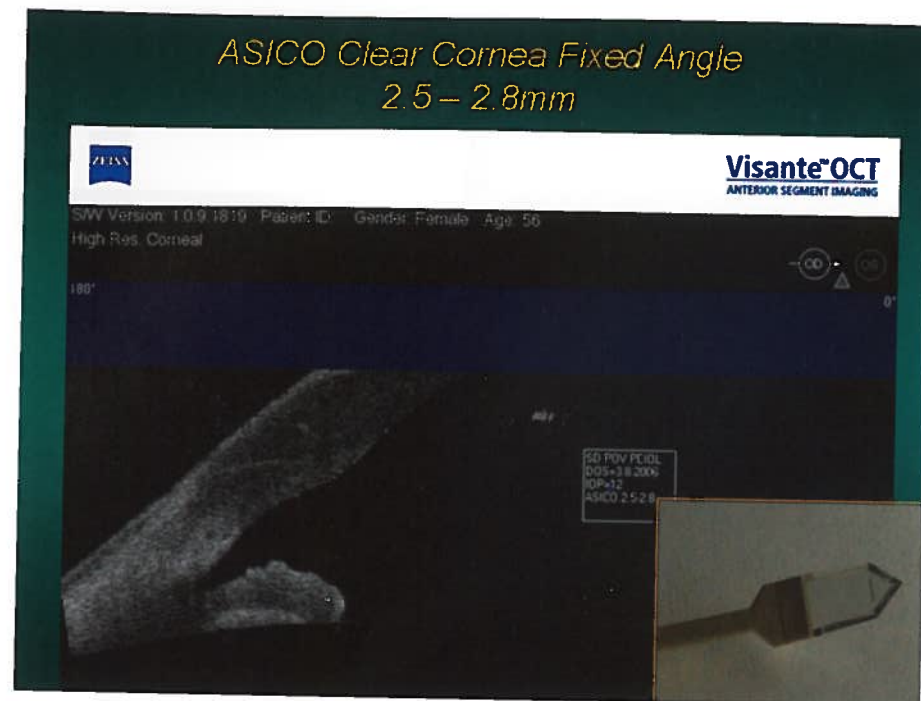
**Figure 13-46** OCT image of a clear corneal incision made with the Accutome Black Blade. Image of the blade is inset.

have also indicated that cadaver eye incision strength cannot be compared to incisions in vivo.<sup>28</sup> Ernest and Neuhann<sup>72</sup> have compared in vivo posterior limbal incisions with clear corneal incisions and found that deep-grooved incisions performed better than shallow-grooved or single-plane incisions, in addition to finding that posterior limbal incisions performed better than clear corneal incisions when challenged by pinpoint pressure.

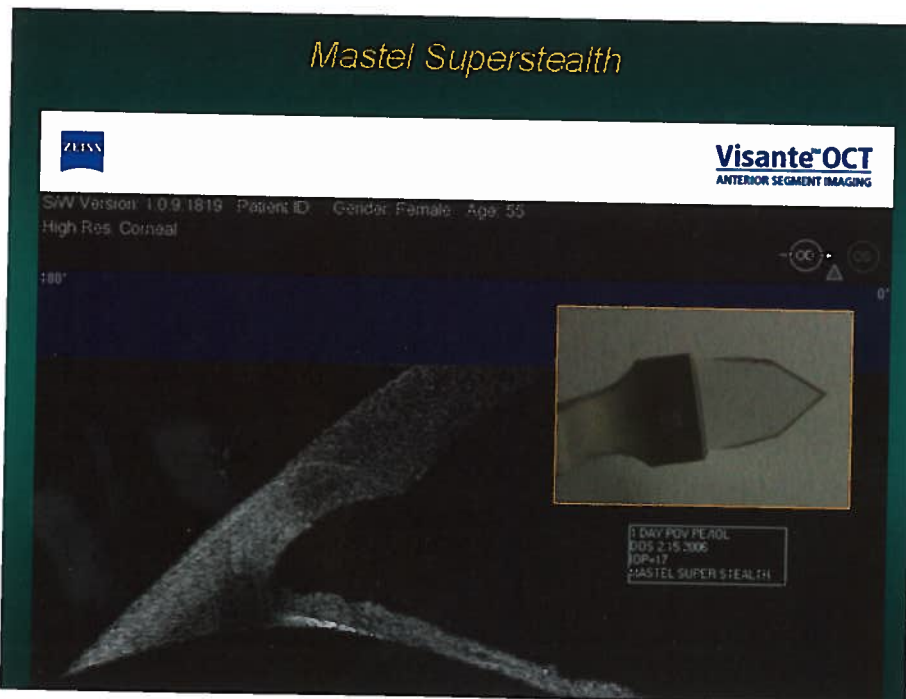
Many surgeons have called into question the validity of pinpoint pressure as a clinically relevant test for cataract wound strength because the probability that anyone would challenge their own incision by

pressing on it with something as fine as the instruments utilized to apply pinpoint pressure in these studies is highly unlikely. Regardless of whether more posteriorly placed incisions demonstrate increased strength compared to clear corneal incisions, the real question is whether that added strength is clinically significant or relevant. Fine<sup>73</sup> and others have demonstrated the stability of clear corneal incisions when a knuckle or a finger tip, the most likely way patients would challenge these incisions, was used. In addition, it is a well-known fact that a 1 mm "hypersquare" paracentesis will leak the day after surgery if pinpoint pressure is applied to its posterior lip; however, the likelihood





**Figure 13-47** OCT image of a clear corneal incision made with the ASICO Clear Cornea Fixed Angle 2.8–2.8 mm Blade. Image of the blade is inset.



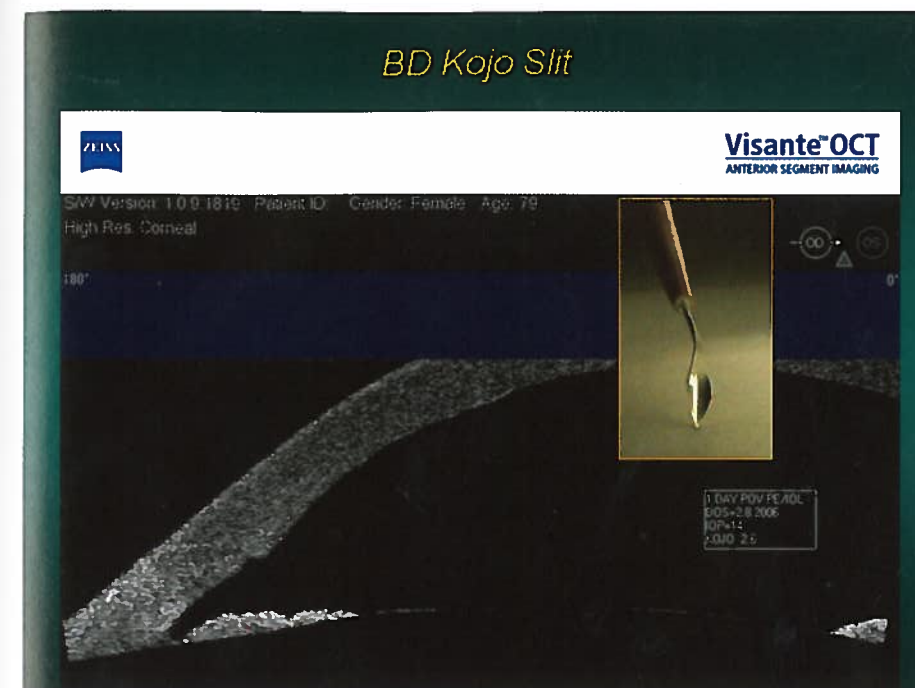
**Figure 13-48** OCT image of a clear corneal incision made with the Mastel Superstealth Blade. Image of the blade is inset.

of any paracentesis incision leaking spontaneously or with blunt pressure the day following surgery is extremely low.

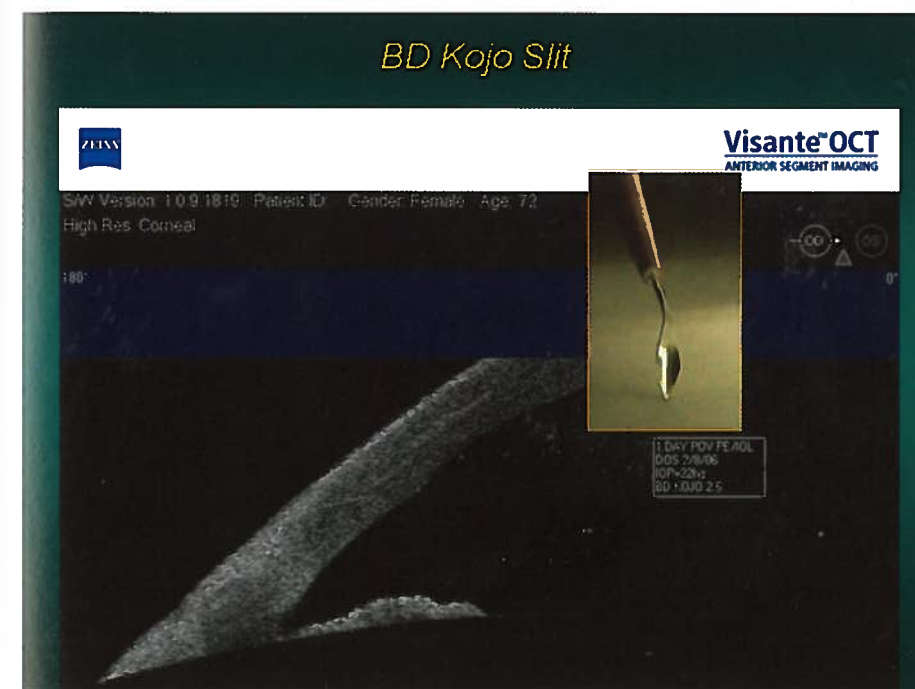
Another point of controversy is in regard to the studies in cat eyes performed by Ernest et al.<sup>74</sup> These studies revealed a fibrovascular response in incisions placed in the limbus with extensive wound healing in 7 days compared to a lack of fibrovascular healing in clear corneal incisions. This study has been used to propose an increased safety for limbal incisions as compared to clear corneal incisions. Unfortunately, the real issue for these various incisions is not healing but sealing. We believe that as long as an incision is sealed at the conclusion of surgery, and it remains sealed thereafter,

the time before complete healing of the incision is accomplished is almost irrelevant, especially since there is still a 7-day period in which limbal incisions are not truly "healed." An analogy can be drawn to the sealing which takes place during laser-assisted in-situ keratomileusis (LASIK) in which there is no fibrovascular healing of the clear corneal interface, which has little effect on the strength, effectiveness or safety of the wound and, in fact, is an advantage by limiting scarring and an inflammatory healing response.

One of the clear disadvantages of limbal corneal incisions is the greater likelihood of ballooning of conjunctiva, which can make visualization of anterior chamber structures during the surgical



**Figure 13-49** OCT image of a clear corneal incision made with the BD Kojo Slit Blade during the learning curve. Image of the blade is inset.



**Figure 13-50** OCT image of a clear corneal incision made with the BD Kojo Slit Blade during the learning curve. Image of the blade is inset.

procedure more difficult. In addition, studies by Park et al.<sup>29</sup> demonstrated that violation of the conjunctiva threatens the integrity not only of pre-existing filtering blebs but of the conjunctiva which would participate in filtering surgery at some future date. Finally, the presence of subconjunctival hemorrhage, although not important with respect to the ultimate function of the eye, may be of importance from a cosmetic perspective to the patient as well as to the survival of filtering blebs.

Contraindications for clear corneal incisions include the presence of radial keratotomy incisions that extend to the limbus that might be challenged by clear corneal incisions,<sup>75</sup> marginal

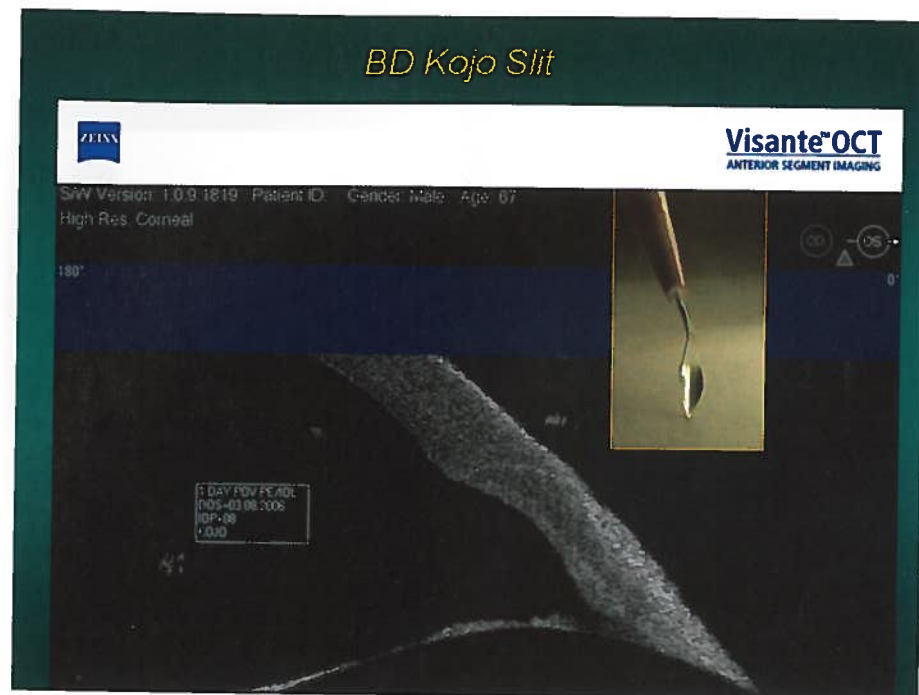
degenerations associated with thinning of the peripheral cornea and, perhaps, advanced corneal endothelial dystrophy.

## ■ ENDOPTHALMITIS: IS THERE AN INCREASED RISK? ■

Endophthalmitis prophylaxis involves a large number of factors including:

- a proper preoperative antibiotic regime
- preparation of the surgical field, including Betadine and draping



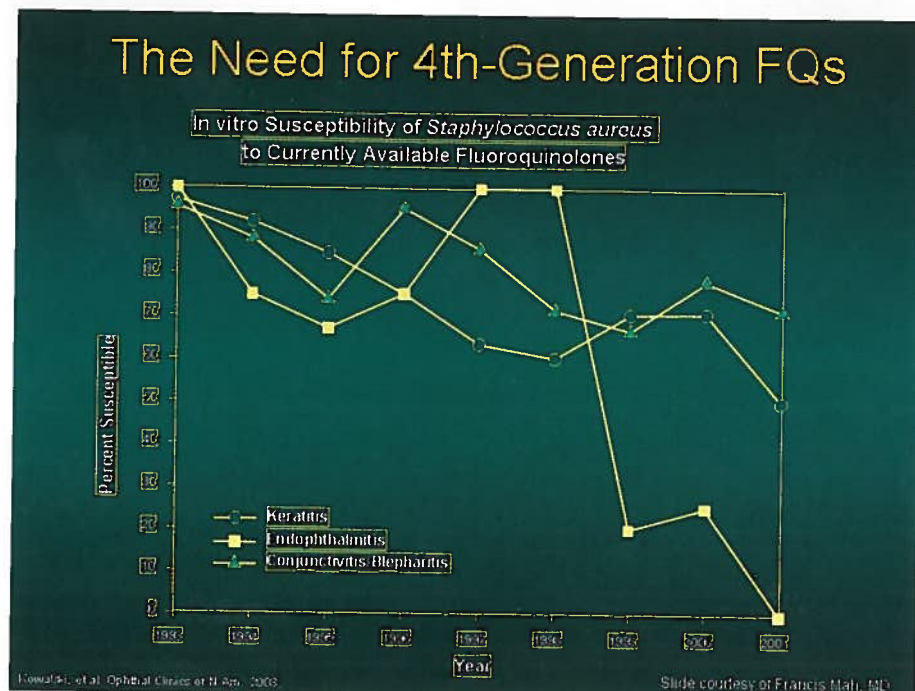


**Figure 13-51** OCT image of a clear corneal incision made with the BD Kojo Slit Blade after using the blade for 1 month. Image of the blade is inset.

- incision construction
- surgical technique, including atraumatic surgery
- power modulations to avoid heating the incision
- avoiding grasp of the roof of the incision with a toothed forceps, which would abrade the epithelium and disrupt the fluid barrier for endothelial pumping
- incision closure
- testing for leakage
- postoperative antibiotics.

The authors have practiced for longer than 10 years, on over 9000 cases without a single case of infectious endophthalmitis.

The role of unsutured clear corneal incisions for cataract surgery and the apparent increased incidence of postoperative endophthalmitis in many reports are under rather intense scrutiny.<sup>76-86</sup> The role of changing antibiotic sensitivity has been an issue (Figure 13-52). In Sweden, there has been a decreased incidence of endophthalmitis associated with an increased use of clear corneal incisions.<sup>87,88</sup> The recent ESCRS study of endophthalmitis showed an 80% reduction with the use of intracameral



**Figure 13-52** Graph illustrating the role of changing antibiotic sensitivity to infectious agents in the incidence of postoperative endophthalmitis.

cefuroxime.<sup>89</sup> There are other reports of no increased incidence of endophthalmitis with the use of clear corneal incisions.<sup>76,90-92</sup>

Attention to all of the details for endophthalmitis prophylaxis is of primary importance. Incision construction leading to proper architecture is of primary importance among all of the variables that are part of endophthalmitis prophylaxis, and certainly not all clear corneal incisions are the same. An incision in the plane of the cornea with a chord length of at least 2 mm appears to give uniquely advantageous architecture for adequate self-sealability.

## CONCLUSION

Clear corneal cataract incisions are becoming a more popular option for cataract extraction and IOL implantation throughout the world. Through the use of clear corneal incisions and topical and intracameral anesthesia, we have achieved surgery that is the least invasive of any time in the history of cataract surgery, with visual rehabilitation that is almost immediate. Just 25 years ago, inpatient intracapsular cataract surgery, often performed under general anesthesia, followed by aphakic spectacles, was the standard of care. It is striking to realize how far we have come in such a short time.

## References

- Paton D, Troutman R, Ryan S. Present trends in incision and closure of the cataract wound. *Highlights Ophthalmol* 1973;14(3):176.
- Jaffe NS, Clayman HM. The pathophysiology of corneal astigmatism after cataract extraction. *Trans Am Acad Ophthalmol Otolaryngol* 1975;79:OP615-630.
- Kelman CD. Phacoemulsification and aspiration: a new technique of cataract removal: a preliminary report. *Am J Ophthalmol* 1967;64:23.
- Culvard DM, Kratz RP, Mazzocco TR, Davidson B. Clinical evaluation of the Terry surgical keratometer. *Am Intraocular Implant Soc J* 1980;6:249-251.
- Masket S. Origin of scleral tunnel methods. *J Cataract Refract Surg* 1993;19:812-813. [letter to the editor].
- Girard LJ, Hoffman RF. Scleral tunnel to prevent induced astigmatism. *Am J Ophthalmol* 1984;97:450-456.
- Maloney WF, Grindle L. *Textbook of phacoemulsification*. Fallbrook, CA: Lasenda Publishers; 1988.
- Shepherd JR. Induced astigmatism in small incision cataract surgery. *J Cataract Refract Surg* 1989;15:85-88.
- Fine IH. Infinity suture: modified horizontal suture for 6.5 mm incisions. In: Gills JP, Sanders DR, editors. *Small-incision cataract surgery: foldable lenses, one-stitch surgery, sutureless surgery, astigmatic keratotomy*. Thorofare, NJ: Slack, Inc; 1990. p. 191-196.
- Masket S. Horizontal anchor suture closure method for small incision cataract surgery. *J Cataract Refract Surg* 1991;17(Suppl.):689-695.
- Fishkind WJ. Horizontal overlap suture: a new astigmatism-free closure, focus on phaco. *Ocular Surgery News* 1990;8.
- McFarland MS. Surgeon undertakes phaco, foldable IOL series sans sutures. *Ocular Surgery News* 1990;8.
- Ernest PH. Presentation at the Department of Ophthalmology. Detroit, MI: Wayne State University School of Medicine; Feb 28, 1990.
- Koch PS. Structural analysis of cataract incision construction. *J Cataract Refract Surg* 1991;17(Suppl.):661-667.
- Kershner RM. Sutureless one-handed intercapsular phacoemulsification: the keyhole technique. *J Cataract Refract Surg* 1991;17(Suppl.):719-725.
- Fine IH. Architecture and construction of a self-sealing incision for cataract surgery. *J Cataract Refract Surg* 1991;17:672-676.
- Singer JA. Frown incision for minimizing induced astigmatism after small incision cataract surgery with rigid optic intraocular lens implantation. *J Cataract Refract Surg* 1991;17(Suppl.):677-688.
- Pallin SL. Chevron sutureless closure: a preliminary report. *J Cataract Refract Surg* 1991;17(Suppl.):706-709.
- Ernest PH. Introduction to sutureless surgery. In: Gills JP, Sanders DR, editors. *Small incision cataract surgery: foldable lenses, one-stitch surgery, sutureless surgery, astigmatic keratotomy*. Thorofare, NJ: Slack, Inc; 1990. p. 103-105.
- Harms H, Mackensen G. Intracapsular extraction with a corneal incision using the Graefe knife. In: *Ocular surgery under the microscope*. Stuttgart, Germany: Georg Thieme Verlag; 1967. p. 144-153.
- Paton D, Troutman R, Ryan S. Present trends in incision and closure of the cataract wound. *Highlights of Ophthalmology*; 1973;14(3):176.
- Arnott EJ. Intraocular implants. *Trans Ophthalmol Soc UK* 1981;101:58-60.
- Galand A. *La technique de l'enveloppe*. Liege, Belgium: Pierre Mardaga publisher; 1988.
- Brown DC, Fine IH, Gills JP et al. The future of foldables. Panel discussion held at the 1992 annual meeting of the American Society of Cataract and Refractive Surgery. *Ocular Surgery News* 1992;(Suppl.).
- Shimizu K. Pure corneal incision. *Phaco & Foldables* 1992;5:5-8.
- Fine IH. Corneal tunnel incision with a temporal approach. In: Fine IH, Fichman RA, Grabow HB, editors. *Clear-corneal cataract surgery & topical anesthesia*. Thorofare, NJ: Slack, Inc; 1993. p. 5-26.
- Fine IH, Fichman RA, Grabow HB. Clear-corneal cataract surgery & topical anesthesia. Thorofare, NJ: Slack, Inc; 1993.
- Rosen ES. Clear corneal incisions: a good option for cataract patients. A roundtable discussion. *Ocular Surgery News* 1998.
- Park HJ, Kwon YH, Weitzman M, Caprioli J. Temporal corneal phacoemulsification in patients with filtered glaucoma. *Arch Ophthalmol* 1997;115:1375-1380.
- Hogan MJ, Alvarado JA, Weddell JE, editors. *Histology of the human eye: an atlas and textbook*. Philadelphia: W.B. Saunders Company; 1971.
- Menapace RM. Preferred incisions for current foldable lenses and their impact on corneal topography. Abstract. Luxor-Aswan, Egypt: Cataract Workshop on the Nile; November 20, 1996.
- Fine IH. Descriptions can improve communication. *Ophthalmology Times* 1996;21:30.
- Fine IH. Self-sealing corneal tunnel incision for small-incision cataract surgery. *Ocular Surgery News* 1992.
- Williamson CH. Cataract keratotomy surgery. In: Fine IH, Fichman RA, Grabow HB, editors. *Clear-corneal cataract surgery & topical anesthesia*. Thorofare, NJ: Slack, Inc; 1993. p. 87-93.
- Langerman DW. Architectural design of a self-sealing corneal tunnel, single-hinge incision. *J Cataract Refract Surg* 1994;20:84-88.
- Vass C, Menapace R, Rainer G et al. Comparative study of corneal topographic changes after 3.0 mm beveled and hinged clear corneal incisions. *J Cataract Refract Surg* 1998;24:1498-1504.
- Kershner RM. Clear corneal cataract surgery and the correction of myopia, hyperopia, and astigmatism. *Ophthalmology* 1997;104:381-389.
- Gills JP, Gayton JL. Reducing pre-existing astigmatism. In: Gills JP, editor. *Cataract surgery: the state of the art*. Thorofare, NJ: Slack, Inc; 1998. p. 53-66.
- Nichamin L. Refining astigmatic keratotomy during cataract surgery. *Ocular Surgery News* 1993.
- Budak K, Friedman NJ, Koch DD. Limbal relaxing incisions with cataract surgery. *J Cataract Refract Surg* 1998;24:503-508.
- Fine IH. Techniques spotlight: new blade enhances cataract surgery. *Ophthalmology Times* 1996.
- Jacobi FK, Dick B, Bohle R. Histological and ultrastructural study of corneal tunnel incisions using diamond and steel keratomes. *J Cataract Refract Surg* 1998;24:498-502.
- Radner W, Menapace R, Zehetmayer M, Mallinger R. Ultrastructure of clear corneal incisions. Part I: Effect of keratomes and incision width on corneal trauma after lens implantation. *J Cataract Refract Surg* 1998;24:487-492.
- Mamalis N. Incision width after phacoemulsification with foldable intraocular lens implantation. *J Cataract Refract Surg* 2000;26:237-241.
- Fine IH. Special Report to ASCRS Members: Phacoemulsification Incision Burns. Letter to American Society of Cataract and Refractive Surgery members, 1997.
- Majid MA, Sharma MK, Harding SP. Corneoscleral burn during phacoemulsification surgery. *J Cataract Refract Surg* 1998;24:1413-1415.
- Sugar A, Schertzer RM. Clinical course of phacoemulsification wound burns. *J Cataract Refract Surg* 1999;25:688-692.
- Menapace R. Delayed iris prolapse with unsutured 5.1 mm clear corneal incisions. *J Cataract Refract Surg* 1995;21:353-357.
- Endophthalmitis: State of the prophylactic art. *Eyeworld News* 1997;42-43.
- Nishi O, Nishi K, Fujiwara T, Shirasawa E. Effects of diclofenac sodium and indomethacin on proliferation and collagen synthesis of lens epithelial cells in vitro. *J Cataract Refract Surg* 1995;21:461-465.
- Masket S, Tennen DG. Astigmatic stabilization of 3.0 mm temporal clear corneal cataract incisions. *J Cataract Refract Surg* 1996;22:1451-1455.
- Kohnen T, Dick B, Jacobi KW. Comparison of the induced astigmatism after temporal clear corneal tunnel incisions of different sizes. *J Cataract Refract Surg* 1995;21:417-424.
- Pfleger T, Skorpik C, Menapace R, Scholz U, Weghaupt H, Zehetmayer M. Long-term course of induced astigmatism after clear corneal incision cataract surgery. *J Cataract Refract Surg* 1996;22:72-77.
- Nielsen PJ. Prospective evaluation of surgically induced astigmatism and astigmatic keratotomy effects of various self-sealing small incisions. *J Cataract Refract Surg* 1995;21:43-48.
- Cillino S, Morreale D, Maureri A et al. Temporal versus superior approach phacoemulsification: short-term postoperative astigmatism. *J Cataract Refract Surg* 1997;23:267-271.
- Rainer G, Vass C, Menapace R et al. Long-term course of surgically induced astigmatism after 5.0 mm sclerocorneal valve incision. *J Cataract Refract Surg* 1998;24:1642-1646.
- Holweger R, Marefat B. Corneal changes after cataract surgery with 5.0 mm sutured and 3.5 mm sutureless clear corneal incisions. *J Cataract Refract Surg* 1997;23:342-346.
- Oshima Y, Tsujikawa K, Oh A, Harino S. Comparative study of intraocular lens implantation through 3.0 mm temporal clear corneal and superior scleral tunnel self-sealing incisions. *J Cataract Refract Surg* 1997;23:347-353.
- Poort-van Nohuijs HM, Hendrickx KHM, van Marle WF et al. Corneal astigmatism after clear corneal and corneoscleral incisions for cataract surgery. *J Cataract Refract Surg* 1997;23:758-760.
- Long DA, Monica ML. A prospective evaluation of corneal curvature changes with 3.0 to 3.5 mm corneal tunnel phacoemulsification. *Ophthalmology* 1996;103:226-232.
- Simsek S, Yasar T, Demirok A et al. Effect of superior and temporal clear corneal incisions on astigmatism after sutureless phacoemulsification. *J Cataract Refract Surg* 1998;24:515-518.
- Roman SJ, Auclin F, Chong-Sit DA, Ullern M. Surgically induced astigmatism with superior and temporal incisions in cases of with-the-rule preoperative astigmatism. *J Cataract Refract Surg* 1998;24:1636-1641.
- Rainer G, Menapace R, Vass C et al. Corneal shape changes after temporal and superolateral 3.0 mm clear corneal incisions. *J Cataract Refract Surg* 1999;25:1121-1126.
- Grabow HB. The clear-corneal incision. In: Fine IH, Fichman RA, Grabow HB, editors. *Clear-corneal cataract surgery & topical anesthesia*. Thorofare, NJ: Slack Inc; 1993. p. 29-62.
- Amon M, Menapace R, Vass C, Radax U. Endothelial cell loss after 3.5 mm temporal clear corneal incision and 3.5 mm superior scleral tunnel incision. *J Implant Refract Surg* 1995;7:229-232.
- Dick HB, Kohnen T, Jacobi FK, Jacobi KW. Long-term endothelial cell loss following phacoemulsification through a temporal clear corneal incision. *J Cataract Refract Surg* 1996;22:63-71.
- Fine IH. Ongoing research in uses of power modulations to achieve low-energy phacoemulsification of cataracts. Presentation at the ASCRS Innovators' Session; Seattle, April 12, 1999.
- Dick HB, Schwenn O, Krummenauer F et al. Inflammation after sclerocorneal versus clear corneal tunnel phacoemulsification. *Ophthalmology* 2000;107:241-247.
- Ernest PH, Lavery KT, Kiessling LA. Relative strength of scleral corneal and clear corneal incisions constructed in cadaver eyes. *J Cataract Refract Surg* 1994;20:626-629.
- Ernest PH, Fenzl R, Lavery KT, Sensoli A. Relative stability of clear corneal incisions in a cadaver eye model. *J Cataract Refract Surg* 1995;21:39-42.
- Mackool RJ, Russell RS. Strength of clear corneal incisions in cadaver eyes. *J Cataract Refract Surg* 1996;22:721-725.
- Ernest PH, Neuhann T. Posterior limbal incision. *J Cataract Refract Surg* 1996;22:78-84.



- [73] Fine IH. New thoughts on self-sealing clear corneal cataract incisions. Presented at Hawaii '96, Maui, Hawaii, January 22, 1996.
- [74] Ernest P, Tipperman R, Eagle R et al. Is there a difference in incision healing based on location? *J Cataract Refract Surg* 1998;24:482-486.
- [75] Budak K, Friedman NJ, Koch DD. Dehiscence of a radial keratotomy incision during clear corneal cataract surgery. *J Cataract Refract Surg* 1998;24:278-280.
- [76] Eifrig CW, Flynn HW, Scott IU, Newton J. Acute-onset postoperative endophthalmitis: review of incidence and visual outcomes (1995-2001). *Ophthalmic Surg Lasers* 2002;33:373-378.
- [77] Miller JJ, Scott IU, Flynn HW, Smiddy WE, Newton J, Miller D. Acute-onset endophthalmitis after cataract surgery (2000-2004): incidence, clinical settings, and visual acuity outcomes after treatment. *Am J Ophthalmol* 2005;139:983-987.
- [78] Cooper BA, Holeskamp NM, Bohigian G, Thompson PA. Case-control study of endophthalmitis after cataract surgery comparing scleral tunnel and clear corneal wounds. *Am J Ophthalmol* 2003;136:300-305.
- [79] Colleaux KM, Hamilton WK. Effect of prophylactic antibiotics and incision type on the incidence of endophthalmitis after cataract surgery. *Can J Ophthalmol* 2000;35:373-378.
- [80] Nagaki Y, Hayasaka S, Kadoi C et al. Bacterial endophthalmitis after small-incision cataract surgery: effect of incision placement and intraocular lens type. *J Cataract Refract Surg* 2003;29:20-26.
- [81] Taban M, Behrens A, Newcomb RL, Nobe MY, Saedi G, Sweet PM, et al. Acute endophthalmitis following cataract surgery. *Arch Ophthalmol* 2005;123:613-620.
- [82] West ES, Behrens A, McDonnell PJ, Tielsch JM, Schein OD. The incidence of endophthalmitis after cataract surgery among U.S. Medicare population increased between 1994 and 2001. *Ophthalmology* 2005;112:1338-1394.
- [83] McDonnell PJ, Taban M, Sarayba MA et al. Dynamic morphology of clear corneal cataract incisions. *Ophthalmology* 2003;110:2342-2348.
- [84] Taban M, Rao B, Reznik J et al. Dynamic morphology of sutureless cataract wounds - effects of incision angle and location. *Surv Ophthalmol* 2004;46:S62-S72.
- [85] Sarayba MA, Taban M, Almeda TI et al. Inflow of ocular surface fluid through clear corneal cataract incisions: a laboratory model. *Am J Ophthalmol* 2004;138:206-210.
- [86] Wallin T, Parker J, Jin Y, Kefalopoulos G, Olson RJ. Cohort study of 27 cases of endophthalmitis at a single institution. *J Cataract Refract Surg* 2005;31:735-741.
- [87] Montan PG, Wejde G, Seterquist H et al. Prophylactic intracameral cefuroxime; evaluation of safety and kinetics in cataract surgery. *J Cataract Refract Surg* 2002;28:982-987.
- [88] Montan PG, Wejde G, Koranyi G, Rylander M. Prophylactic intracameral cefuroxime: efficacy in preventing endophthalmitis after cataract surgery. *J Cataract Refract Surg* 2002;28:977-981.
- [89] Barry P, Seal DV, Gettinby DP, Lees F, Peterson M, Crawford WR. ESCRS study of prophylaxis of postoperative endophthalmitis after cataract surgery: preliminary report of principle results from a European multicenter study. *J Cataract Refract Surg* 2006;32:407-410.
- [90] Monica ML, Long DA. Nine-year safety with self-sealing corneal tunnel incision in clear cornea cataract surgery. *Ophthalmology* 2005;112(6):985-986.
- [91] Masket S. Is there a relationship between clear corneal cataract incisions and endophthalmitis? *J Cataract Refract Surg* 2005;31(4):735-741.
- [92] Oshika T. Update on cataract surgery in Japan: annual survey of the Japanese Society of Cataract and Refractive Surgery. *Presentation at the annual meeting of the Japanese Society of Cataract and Refractive Surgery, Joint Symposium with the American Society of Cataract and Refractive Surgery, June 16, 2006.*



DVD

## Capsulorrhexis

# 14

Thomas F. Neuhann, MD and Roger F. Steinert, MD

### CONTENTS

- History
- Development of Capsulorrhexis
- Terminology
- Principles and Advantages of Capsulorrhexis
- Current Standard Techniques of Capsulorrhexis
- Difficult Situations
- Special Surgical Techniques
- Complications and Pitfalls

### CHAPTER HIGHLIGHTS

- >> Technical tips
- >> Several techniques illustrated
- >> Management of complicated capsulotomy

### HISTORY

The rebirth of extracapsular cataract extraction in its modern, refined, microsurgical version has brought with it the need for an adequate technique for anterior capsulectomy. Vogt's technique, using toothed forceps to grasp and rip out a part of the anterior capsule, was definitely thought to be too traumatic to both the endothelium and the zonular apparatus, as well as too uncontrollable. Kelman's "Christmas tree" technique was a considerable improvement in terms of both better control and less trauma. Soon, however, interconnected perforations of the anterior capsule with a cystotome in a circular pattern, the "can-opener" technique, became the most popular and almost universally used approach worldwide. It allowed relatively precise control of the diameter and shape of the excised anterior capsular flap and, by using a cannula infusion cystotome, allowed the anterior chamber to be maintained throughout the procedure. Later, in an attempt to use the anterior capsule for additional endothelial protection during the surgical procedure, the "letterbox" technique was developed and gained considerable popularity, especially among surgeons preferring planned extracapsular cataract extraction. This two-stage technique also offered

considerable advantages for controlled lens implantation into the capsular bag because the anterior capsular window was not completed until after implantation of the intraocular lens (IOL).

Although these techniques and their modifications adequately fulfilled the aim of removing the central part of the anterior capsule, they proved to have one major disadvantage. The necessary manipulations during either phacoemulsification or extraction of the entire nucleus were almost invariably associated with the creation of one or more tears of the remaining peripheral anterior capsular rim, extending at least into the capsular equator. This has a number of undesirable side effects. Not infrequently, the tears extended beyond the capsular equator and into the posterior capsule, accompanied by the associated complications of vitreous loss and loss of the nucleus into the vitreous, especially when occurring early in the course of the operation. In addition, these tears divided the peripheral anterior capsule into a number of separate flaps, which could then interfere with the surgical procedure, especially the aspiration of peripheral cortical remnants. Finally, accumulating clinical evidence led an increasing number of surgeons to prefer IOL implantation into the capsular bag over sulcus implantation; however, it became evident after a while that at least 50% of the IOLs thought to be securely implanted with both loops in the capsular bag had, in reality, only one fixation loop in the bag or none at all. Anterior capsule tears were frequently the source of IOL loops escaping from the capsular bag.

### DEVELOPMENT OF CAPSULORRHEXIS

From what may later be called a general surgical "instinct" (which was later fully substantiated by the clinical experience), a number of surgeons had realized for some time that the ideal anterior capsulectomy would be one with a smooth, continuous, ideally circular, margin, but the technique to achieve this ideal remained elusive. In 1984, Howard Gimbel in Calgary, Alberta, Canada, and Thomas Neuhann in Munich independently, but simultaneously, developed a technique that essentially consisted of tearing rather than cutting out a central anterior capsular window. What was so decisively new about this technique was not the tearing itself in fact, it had been used for part of the anterior capsulotomy before. The difference was that the tear was brought around the



**KEY POINTS**

1. Conclusions about the effectiveness of intracameral anesthesia in cataract surgery have been mixed.
  2. PF lidocaine 1% 0.1 mL to 0.5 mL is the anesthetic type and volume most frequently used intracamerally in cataract surgery.
  3. There are no significant short-term or systemic toxicities from minimally concentrated, low-volume intracameral anesthesia.
  4. The success of topical and intracameral anesthesia is related to the surgical duration, which is dependent on the surgeon's experience, skill, and comfort.
  5. The posterior capsular tear incidence should be under 10% before a resident surgeon should consider converting to topical anesthesia.
3. Gills JP, Cherchio M, Raanan MG. Unpreserved lidocaine to control discomfort during cataract surgery using topical anesthesia. *J Cataract Refract Surg.* 1997;23:545-550.
  4. Carino NS, Slomovic AR, Chung F, Marcovich AL. Topical tetracaine versus topical tetracaine plus intracameral lidocaine for cataract surgery. *J Cataract Refract Surg.* 1998;24:1602-1608.
  5. Masket S, Gokmen F. Efficacy and safety of intracameral lidocaine as a supplement to topical anesthesia. *J Cataract Refract Surg.* 1998;24(7):956-960.
  6. Boulton JE, Lopatazidis A, Luck J, Baer RM. A randomized control trial of intracameral lidocaine during phacoemulsification under topical anesthesia. *Ophthalmology.* 2000;107(1):68-71.
  7. Eggeling P, Pleyer U, Hartmann C, Rieck PW. Corneal endothelial toxicity of different lidocaine concentrations. *J Cataract Refract Surg.* 2000;26:1403-1408.
  8. Judge AJ, Najafi K, Lee DA, Miller KM. Corneal endothelial toxicity of topical anesthesia. *Ophthalmology.* 1997;104:1373-1379.
  9. Rigal-Sastourne JC, Huart B, Pariselle G, et al. Diffusion of lidocaine after intracameral injection. *J Fr Ophtalmol.* 1999;22(1):21-24.
  10. Pang MP, Fujimoto DK, Wilkens LR. Pain, photophobia, and retinal and optic nerve function after phacoemulsification with intracameral lidocaine. *Ophthalmology.* 2001;108(11):2018-2025.
  11. Wibrelauer C, Iven H, Bastian C, Laqua H. Systemic levels of lidocaine after intracameral injection during cataract surgery. *J Cataract Refract Surg.* 1999;25(5):648-651.
  12. Malecaze FA, Deneuille SF, Julia BJ, et al. Pain relief with intracameral mepivacaine during phacoemulsification. *Br J Ophthalmol.* 2000;84(2):171-174.
  13. Pandey SK, Werner L, Apple DJ, Agarwal A, Agarwal A, Agarwal S. No-anesthesia clear corneal phacoemulsification versus topical and topical plus intracameral anesthesia. *J Cataract Refract Surg.* 2001;27:1643-1650.

**Wound Construction**

*Brett L. Shapiro, MD; Diamond Y. Tam, MD;  
and Ayman Naseri, MD*

Beginning surgeons should learn the essential aspects of wound construction in cataract surgery, including wound type, location, and architecture. This chapter focuses on the 2 types of wounds commonly used in cataract surgery today: the scleral tunnel and clear corneal incisions. We will also discuss the significance of wound location and wound architecture for modern phacoemulsification.

**I. WOUND TYPE**

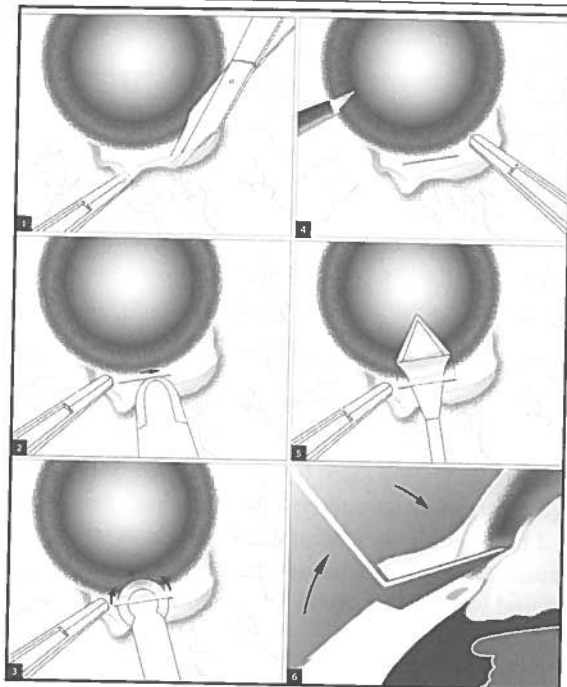
The 2 principal types of wound incisions in cataract surgery are the scleral tunnel (Figure 6-1) and the clear corneal (Figure 6-2). In the last decade, the clear cornea incision has eclipsed the scleral tunnel as the preferred wound type for most surgeons, with reported use of clear cornea incisions rising from 1.5% in 1992 to 80% in 2005.<sup>1,2</sup> Nonetheless, the scleral tunnel incision is a versatile wound that may be particularly useful during the early stages when learning phacoemulsification.

**A. Scleral Tunnel Incision****1. Technique**

Although a scleral tunnel wound can be fashioned under topical anesthesia alone,<sup>3</sup> a retrobulbar block provides akinesia and improved analgesia<sup>3-7</sup> for facilitation of conjunctival and scleral dissection. There are several steps in scleral tunnel wound construction, including conjunctival peritomy, scleral groove, tunnel creation, formation of a paracentesis port, injection of viscoelastic, and keratome entry into the anterior chamber.


- a. Step 1: Once the eye is anesthetized, the first step is the conjunctival peritomy. Although the wound can theoretically be placed anywhere, many surgeons choose the superotemporal sclera. The conjunctival incision should be slightly longer than the planned scleral tunnel length, with or without a radial conjunctival cut, to facilitate adequate exposure. The incision is followed by blunt dissection through Tenon's fascia, using electrocautery for hemostasis as necessary.





**Figure 6-1.** The scleral tunnel wound. (1) A conjunctival peritomy is performed using toothed grasping forceps and Westcott scissors. (2) A blade angled perpendicular to the scleral surface is used to create an approximately half-thickness groove. (3) A pocket or crescent blade is placed into the base of the scleral groove and advanced into the clear cornea with circular motions. (4) A paracentesis port is created with a superblade approximately 2 clock hours away from the scleral tunnel. (5) A keratome is used to “dimple down” into the cornea and enter the anterior chamber. (6) A cross-sectional view of the “dimple down” maneuver performed by the keratome.

- b. Step 2: The scleral groove incision site is marked 1 mm to 2 mm posterior to the limbus. After fixating the globe with toothed grasping forceps, a blade (commonly a #69 beaver blade) angled perpendicular to the scleral surface is used to create an approximately half-thickness scleral groove.
- c. Step 3: The scleral tunnel is then extended anteriorly with a pocket or crescent blade. First, the blade is placed into the groove with the heel of the blade off of the sclera to ensure the plane of the tunnel is at the full depth of the groove. Once adequately within the groove, the heel of the blade is lowered so that it is flush with the scleral surface, and the blade is advanced with circular motions tunneling toward the cornea, stopping once the tip has reached the limbus. As the curvature of the globe changes at the cornea, the tip of the blade



**Figure 6-2.** The clear corneal wound. (1) A Thornton ring fixates the eye, and a superblade is used to create a paracentesis port. (2) A guarded blade is angled perpendicular to the corneal surface and used to create a groove. (3) A diamond keratome is then advanced into the corneal stroma for approximately 2 mm. The heel of the blade is then elevated and advanced into the anterior chamber.

- is then angled upward slightly in order to avoid an overly thin posterior corneal lip or premature entry into the anterior chamber.
- d. Step 4: A limbal paracentesis port is then created approximately 2 to 3 clock hours from the planned location of the scleral tunnel. Viscoelastic is subsequently injected through the paracentesis to fill the anterior chamber.
- e. Step 5: While globe fixation is maintained with grasping forceps, the keratome is gently placed into the scleral tunnel. Small side-to-side movements of the keratome are used to ensure that the blade remains within the plane of the tunnel, avoiding creation of a secondary scleral plane. When the keratome tip is visible in the clear cornea at the most anterior aspect of the tunnel, the heel of the blade is then elevated off the sclera, directing the keratome toward the iris opposite the wound. This downward pressure at the tip of the keratome creates small, visible folds in the cornea, described by




the term “dimple down.” The keratome is then advanced into the anterior chamber such that the shoulders of the blade pass through the internal aspect of the wound, thus ensuring adequate internal wound width.

## 2. Advantages

- A scleral tunnel incision can be safely enlarged for purposes such as insertion of nonfoldable intraocular lenses (IOLs) or conversion to extracapsular cataract extraction.
- Once the scleral tunnel incision is closed, conjunctiva covers these wounds, which may play a role in the lower reported incidence of endophthalmitis.<sup>8,9</sup>
- Scleral tunnels begin further posteriorly than clear corneal tunnels, and thus anterior chamber entry is also relatively more posterior. The resultant vertical distance between the phacoemulsification probe tip and the corneal endothelium is greater in the scleral tunnel than that of clear corneal wounds, leading to less endothelial damage by ultrasound phacoemulsification power (Figure 6-3).<sup>10,11</sup>
- As scleral tunnel wounds are created further from the optical center, a phaco-induced wound burn at this location would have less astigmatic consequence than a burn in the clear cornea.
- The magnitude of induced postoperative astigmatism increases with both incision length and proximity to the optical center.<sup>12</sup> Larger incisions in the sclera induce less postoperative astigmatism than similar-sized clear corneal incisions because they are further from the optical center.<sup>13</sup> Both scleral tunnel and clear corneal incisions that are 3 mm or less are astigmatism neutral.<sup>14,15</sup>

## 3. Disadvantages

- The topography of the patient’s face can restrict surgical exposure, making a scleral tunnel incision difficult. For example, a prominent brow, a narrow palpebral fissure, or a sunken globe in a deep orbit may obstruct access to the superior and superotemporal sclera, if chosen as the incision location.
- When tunneling forward with the pocket blade, failure to tilt the blade downward when creating the lateral aspect of the tunnel may result in severing the edge, creating a loose scleral flap at the postero-lateral aspect of the wound.
- If the scleral groove incision is too deep, damage or disinsertion of the ciliary body may result. If the roof of the scleral tunnel is too thin, a blade entering the wound may cause an anterior buttonhole or perforation, creating an undesirable scleral defect.
- Globe perforation, premature posterior entry to the anterior chamber, iris prolapse, and poor wound apposition are other potential complications of a deep scleral groove.<sup>16</sup>



**Figure 6-3.** Cross-sectional view of scleral tunnel and clear corneal wounds. (1) An incision is made in the sclera with the tunnel extending forward into the cornea (solid line). (2) A grooved biplanar clear corneal incision is depicted (solid line). Note the more posterior corneal entry in the scleral tunnel wound. The anticipated position of the phacoemulsification probe (dotted line) also is further from the endothelium in the scleral tunnel wound as compared to the clear corneal wound (vertical arrow).

- The presence of a filtering bleb or conjunctival scarring preoperatively may complicate the creation of a conjunctival peritomy. Functionality of pre-existing blebs may be affected; conjunctival manipulation may result in scar tissue that can decrease functionality of potential future filtering blebs.<sup>17</sup>
- Dissection and manipulation of vascular tissues such as the conjunctiva and sclera can cause blood to track forward through the tunneled wound into the anterior chamber, resulting in hyphema. Also, subconjunctival hemorrhages are more common with scleral tunnel wounds and may result in an inferior cosmetic outcome to that of the clear cornea phacoemulsification.

## B. Clear Corneal Incision

### 1. Technique

The steps in the construction of clear corneal incisions include anesthesia, paracentesis creation, corneal groove incision, and keratome entry into the anterior chamber. Although various modes and combinations of anesthesia may be employed,<sup>5,18-20</sup> many surgeons use topical anesthesia for clear corneal incisions.<sup>1,4,21,22</sup>

- Step 1: The paracentesis is created in the same manner as previously described for a scleral tunnel.
- Step 2: The next step for some surgeons is the corneal groove incision, which is usually placed temporally at the limbus. A Thornton fixation ring is used to stabilize the globe, and a guarded knife is angled perpendicular to the cornea in order to achieve a consistent fixed groove depth. A groove can be at the same depth as the tunnel, or deeper, with the latter resulting in a hinge at the base of the



tunnel, which has been found to improve self-sealability of the wound upon application of external pressure.<sup>23</sup> Some surgeons skip this step completely, creating a single plane incision.

- c. Step 3: The keratome is then placed in the corneal groove with the heel flush with the ocular surface and advanced approximately 2 mm anteriorly, dissecting a plane through the corneal stroma. The heel of the blade is subsequently elevated off of the globe so that the tip of the keratome is directed toward the iris opposite the wound. Depending on the sharpness of the blade being used, this can create visual folds in the cornea as described previously for scleral tunnel incisions. When using diamond blades or ultra-sharp metallic keratomes, some surgeons simply create a single plane incision without a limbal groove or a "dimple down" maneuver. The keratome is advanced into the anterior chamber such that the shoulders of the blade penetrate the internal aspect of the wound, ensuring adequate internal wound width.

While some surgeons prefer the tactile tissue resistance during creation of the corneal tunnel afforded by metallic keratomes, diamond keratomes have been shown to cause less tissue disruption in corneal stroma.<sup>24</sup> Furthermore, diamond keratomes remain sharp and resist wear longer than their metal counterparts.

## 2. Advantages

- A retrobulbar block is avoided because clear corneal incisions may be performed with topical anesthesia alone.<sup>20,25</sup> This is an important consideration in patients with a bleeding diathesis or who are highly myopic because there is a higher risk of retrobulbar hemorrhage<sup>26</sup> or globe perforation,<sup>27</sup> respectively, from a retrobulbar block. A retrobulbar block can also cause complications inducing retinal vascular occlusion,<sup>28,29</sup> optic nerve injury,<sup>30</sup> strabismus,<sup>31</sup> and brainstem anesthesia.<sup>32,33</sup> Topical anesthesia allows for rapid visual rehabilitation following the surgical procedure while avoiding the risks of retrobulbar anesthesia.<sup>34</sup>
- A clear corneal incision is more time efficient and often has a better immediate cosmetic result.
- Since the conjunctiva is relatively untouched, it is left naïve for future filtering surgery if necessary. Similarly, a clear corneal approach leaves pre-existing filtering blebs undisturbed.<sup>35,36</sup>
- With regard to refractive outcomes, preoperative astigmatism can be corrected at the time of cataract surgery with relatively simple modifications to the clear cornea incision such as limbal relaxing incisions. Modifications in incision length, clock hour position, and proximity to the optical center can all reduce preoperative astigmatism.<sup>37,38</sup>

## 3. Disadvantages

- Pre-existing corneal problems such as Fuchs' endothelial dystrophy, peripheral corneal degeneration, previous penetrating keratoplasty,

or radial keratotomy scars<sup>39</sup> are relative contraindications to corneal wounds. Also, in patients with impaired blinking, as seen in Parkinson's disease, exposed incisions in the cornea should be avoided due to the risk of corneal melt. The incision in these patients should generally be protected by the conjunctiva.

- While conjunctiva covers the wound in scleral tunnel incisions, a clear corneal wound is exposed, and a postoperative wound leak allows for potential ingress of contaminated ocular surface fluid into the anterior chamber.<sup>40,41</sup> Several reviews in the literature have reported a 3- to 4-fold higher rate of endophthalmitis in sutureless clear corneal incisions compared to scleral tunnel incisions,<sup>8,9</sup> and yet other series have found no significant difference.<sup>42,43</sup>
- A corneal groove that is placed too posterior can cause an inadvertent incision in the conjunctiva and lead to ballooning<sup>44,45</sup> as irrigation fluid collects in the subconjunctival space.
- Instrument manipulation can cause corneal striae, which may result in the death of corneal endothelial cells.<sup>46,47</sup>
- Incisions longer than 4 mm are preferentially made in the sclera because unsutured corneal incisions of this size can gape and fail to self-seal.<sup>48</sup> Subsequent suture closure of such an incision may result in greater induced postoperative astigmatism.

## II. WOUND LOCATION

While wounds can be placed at any position theoretically, the choice of their location may be influenced by astigmatism considerations, pre-existing ocular disease, and ergonomic comfort of the surgeon.

### A. Astigmatism

Astigmatism is induced to a great degree the closer the incision is placed to the optical center of the cornea.<sup>12</sup> Given the elliptical shape of the normal cornea, temporal incisions are generally further from the center and induce a smaller magnitude of astigmatism than superior incisions of equal size. This is true for both clear corneal and scleral tunnel incisions.<sup>49-51</sup> Wound location can also be selected so as to correct pre-existing astigmatism.

### B. Ocular Disease

Ocular disease may play an important role in determining not only whether the wound is placed in the cornea or sclera, but also the clock hour or quadrant chosen. For example, a temporal pterygium may lead to a choice of placing a superior or superotemporal wound, while a superior filtering bleb or superotemporal tube shunt may preclude placement of superior wounds.

### C. Ergonomics

Ergonomic comfort of the surgeon is also important when planning the placement of the wound. For example, a right-handed surgeon has full temporal cornea access during phacoemulsification of the right eye, but incisions in the superior cornea or sclera require the surgeon to sit at the head of the



patient. In this position, a prominent brow or a globe positioned deep in the orbit may make surgical positioning and access difficult for the surgeon. Likewise, a high nose bridge can interfere with maneuverability of the second instrument. With the left eye, the surgeon has relatively improved access to the superotemporal globe, but a straight temporal incision requires the surgeon to be seated at the 4:30 position with spatial crowding from the patient's upper torso.

### III. WOUND ARCHITECTURE

#### A. Incision Width

As techniques and technology have advanced in cataract surgery, surgeons have created smaller incisions. In order to remove the lens, the incision must be of sufficient size to accommodate the sleeve diameter of the phaco probe. The development of smaller probes has led to initial incisions less than 2 mm and as small as 0.9 mm,<sup>52</sup> such as those used in bimanual phacoemulsification.

The final wound dimension is determined by the size of the optic of the IOL to be inserted or the size of the injector port when inserting foldable IOLs. Direct IOL insertion or insertion via an injector can stretch and permanently enlarge the incision, potentially resulting in loss of the designed self-sealing wound properties.<sup>53,54</sup> As lenses inserted through wounds of less than 2 mm become more widely accepted and studied, the final wound size necessary to perform cataract surgery with IOL implantation will continue to decrease.<sup>55,56</sup>

#### B. Incision Shape

The impact of incision shape on postoperative astigmatism is controversial. Some studies have revealed a significant change in postoperative astigmatism,<sup>12,57,58</sup> while others found no such difference.<sup>59,60</sup> Although the trend toward smaller, 3-mm, astigmatism-neutral incisions has made wound shape less relevant in routine phacoemulsification, incision shape is potentially important when shifts in postoperative astigmatism are desirable or when large incisions are unavoidable. Examples include the simultaneous correction of a pre-existing astigmatism,<sup>38</sup> the conversion of an operation to an extracapsular cataract extraction, or the decision to insert a nonfoldable IOL.<sup>57</sup>

The 4 shapes described for scleral tunnel incisions are arcuate, straight, frown, and chevron. The arcuate incision follows a curved, circumlimbal trajectory that approximates the curvature of the adjacent limbus. The straight incision traces a simple linear trajectory in the direction tangential to the adjacent limbus. The frown incision follows a curved trajectory and can be thought of as an inverse-arcuate incision.<sup>58</sup> Lastly, the chevron is a modification of the arcuate incision that approximates the curvature of the adjacent limbus with 2 straight lines in a V formation.<sup>61</sup>

When an incision is made in the sclera, normal tension forces separate the 2 wound edges, causing gape. The curved incision allows the greatest degree of translational and rotational tissue movement,<sup>12</sup> and therefore induces the greatest magnitude of postoperative astigmatism.<sup>57</sup> The frown incision results

in the least amount of tissue movement<sup>12</sup> and postoperative astigmatism.<sup>58</sup> In addition to the astigmatic benefit, the frown or chevron incision effectively shortens the length of the scleral tunnel, allowing less restriction to movement of surgical instrumentation without altering the chord length of the external incision.

#### C. Tunnel Length

Premature posterior or delayed anterior entry into the anterior chamber results in a tunnel that is too short or long, respectively, both of which can generate complications. A short tunnel can lead to poor control of anterior chamber depth and iris prolapse. Decreased tissue apposition and failure of the wound to self-seal may necessitate the use of sutures with potential postoperative astigmatic sequelae.<sup>62</sup>

A long tunnel can decrease surgical instrument mobility in the anterior chamber due to oarlocking and impaired pivoting ability. The excessive manipulation of surgical instruments can tear the internal or external wound edges, induce scrolling or detachment of Descemet's membrane,<sup>63,64</sup> and create corneal striae, which in turn decreases intraoperative visibility and may damage corneal endothelium.<sup>46</sup> The endothelial cells can be further damaged by phaco-induced trauma as the probe tip enters the anterior chamber in closer proximity to the corneal endothelium (see Figure 6-3).<sup>11</sup>

Both scleral tunnel and clear corneal incisions, when created properly, possess a self-sealing, valve-like tunnel design whereby maximum architectural stability is obtained in wounds 3.5 mm wide or less and of at least 2.0 mm in length.<sup>65,66</sup>

### IV. CONCLUSION

The type, location, and architecture of the constructed wound each influence the surgical procedure, patient recovery, and visual outcome of phacoemulsification. While both scleral tunnel and clear corneal wounds may be used to successfully complete removal of the cataract, attention must be given to each individual patient and pre-existing ocular disease, astigmatic profile, and facial anatomy. Wound architecture and surgical technique are also important in avoiding intraoperative complications, minimizing corneal endothelial damage, and proper wound closure. A thorough understanding of the advantages, disadvantages, and correct application of each element of wound construction is essential to the proper planning and ultimate visual outcome.

### ACKNOWLEDGMENT

The authors would like to acknowledge Serena W. Tam for designing and illustrating the figures.



## KEY POINTS

1. The 2 most common types of wounds for phacoemulsification are scleral tunnel and clear corneal incisions.
2. Advantages of the scleral tunnel incision include conjunctival coverage and a greater vertical distance from the corneal endothelium to the phacoemulsification probe.
3. Advantages of the clear corneal incision include an undisturbed conjunctiva and the potential avoidance of a retrobulbar block.
4. Choice of wound location is influenced by astigmatic considerations, pre-existing ocular disease states, and ergonomic comfort of the surgeon.
5. Incision characteristics such as width, shape, and tunnel length may all be modified, affecting astigmatic outcome, endothelial cell loss, and self-sealing properties of the wound.

## REFERENCES

1. Leaming DV. Practice styles and preferences of ASCRS members—2003 survey. *J Cataract Refract Surg.* 2004;30(4):892-900.
2. Leaming DV. Practice Styles and Preferences of U.S. ASCRS Members—2005 survey. ASCRS Symposium and Congress. San Francisco: American Society of Cataract and Refractive Surgery; 2006.
3. Virtanen P, Huha T. Pain in scleral pocket incision cataract surgery using topical and peribulbar anesthesia. *J Cataract Refract Surg.* 1998;24(12):1609-1613.
4. Patel BC, Clinch TE, Burns TA, et al. Prospective evaluation of topical versus retrobulbar anesthesia: a converting surgeon's experience. *J Cataract Refract Surg.* 1998;24(6):853-860.
5. Friedman DS, Bass EB, Lubomski LH, et al. Synthesis of the literature on the effectiveness of regional anesthesia for cataract surgery. *Ophthalmology.* 2001;108(3):519-529.
6. Boezaart A, Berry R, Nell M. Topical anesthesia versus retrobulbar block for cataract surgery: the patients' perspective. *J Clin Anesth.* 2000;12(1):58-60.
7. McGoldrick KE. Comment on topical anesthesia versus retrobulbar block for cataract surgery: the patients' perspective. *Survey of Anesthesiology.* 2001;45(1):6-8.
8. Cooper BA, Holekamp NM, Bohigian G, Thompson PA. Case-control study of endophthalmitis after cataract surgery comparing scleral tunnel and clear corneal wounds. *Am J Ophthalmol.* 2003;136(2):300-305.
9. Nagaki Y, Hayasaka S, Kadoi C, et al. Bacterial endophthalmitis after small-incision cataract surgery: effect of incision placement and intraocular lens type. *J Cataract Refract Surg.* 2003;29(1):20-26.
10. Bleckmann H, Vogt R. Experimental endothelial lesions by means of an ultrasound phacoemulsificator. *Graefes Arch Clin Exp Ophthalmol.* 1986;224(5):457-462.
11. Ogino K, Koda F, Miyata K. [Damage to cultured corneal endothelium caused by ultrasound during phacoemulsification]. *Nippon Ganka Gakkai Zasshi.* 1993;97(11):1286-1291.
12. Koch PS. Structural analysis of cataract incision construction. *J Cataract Refract Surg.* 1991;17(Suppl):661-667.

13. Olsen T, Dam-Johansen M, Bek T, Hjortdal JO. Corneal versus scleral tunnel incision in cataract surgery: a randomized study. *J Cataract Refract Surg.* 1997;23(3):337-341.
14. Oshima Y, Tsujikawa K, Oh A, Harino S. Comparative study of intraocular lens implantation through 3.0 mm temporal clear corneal and superior scleral tunnel self-sealing incisions. *J Cataract Refract Surg.* 1997;23(3):347-353.
15. Olson RJ, Crandall AS. Prospective randomized comparison of phacoemulsification cataract surgery with a 3.2-mm vs a 5.5-mm sutureless incision. *Am J Ophthalmol.* 1998;125(5):612-620.
16. Allan BD. Mechanism of iris prolapse: a qualitative analysis and implications for surgical technique. *J Cataract Refract Surg.* 1995;21(2):182-186.
17. Broadway DC, Grierson I, Hitchings RA. Local effects of previous conjunctival incisional surgery and the subsequent outcome of filtration surgery. *Am J Ophthalmol.* 1998;125(6):805-818.
18. Bellucci R. Anesthesia for cataract surgery. *Curr Opin Ophthalmol.* 1999;10(1):36-41.
19. Crandall AS. Anesthesia modalities for cataract surgery. *Curr Opin Ophthalmol.* 2001;12(1):9-11.
20. Navaleza JS, Pendse SJ, Blecher MH. Choosing anesthesia for cataract surgery. *Ophthalmol Clin North Am.* 2006;19(2):233-237.
21. Koch PS. Efficacy of lidocaine 2% jelly as a topical agent in cataract surgery. *J Cataract Refract Surg.* 1999;25(5):632-634.
22. Patel BC, Burns TA, Crandall A, et al. A comparison of topical and retrobulbar anesthesia for cataract surgery. *Ophthalmology.* 1996;103(8):1196-1203.
23. Langerman DW. Architectural design of a self-sealing corneal tunnel, single-hinge incision. *J Cataract Refract Surg.* 1994;20(1):84-88.
24. Jacobi FK, Dick HB, Bohle RM. Histological and ultrastructural study of corneal tunnel incisions using diamond and steel keratomes. *J Cataract Refract Surg.* 1998;24(4):498-502.
25. Claoue C, Lanigan C. Topical anaesthesia for cataract surgery. *Aust N Z J Ophthalmol.* 1997;25(4):265-268.
26. Konstantatos A. Anticoagulation and cataract surgery: a review of the current literature. *Anaesth Intensive Care.* 2001;29(1):11-18.
27. Modarres M, Parvaresh MM, Hashemi M, Peyman GA. Inadvertent globe perforation during retrobulbar injection in high myopes. *Int Ophthalmol.* 1997;21(4):179-185.
28. Cowley M, Campochiaro PA, Newman SA, Fogle JA. Retinal vascular occlusion without retrobulbar or optic nerve sheath hemorrhage after retrobulbar injection of lidocaine. *Ophthalmic Surg.* 1988;19(12):859-861.
29. Morgan CM, Schatz H, Vine AK, et al. Ocular complications associated with retrobulbar injections. *Ophthalmology.* 1988;95(5):660-665.
30. Hersch M, Baer G, Dieckert JP, et al. Optic nerve enlargement and central retinal-artery occlusion secondary to retrobulbar anesthesia. *Ann Ophthalmol.* 1989;21(5):195-197.
31. Johnson DA. Persistent vertical binocular diplopia after cataract surgery. *Am J Ophthalmol.* 2001;132(6):831-835.
32. Nicoll JM, Acharya PA, Ahlen K, et al. Central nervous system complications after 6000 retrobulbar blocks. *Anesth Analg.* 1987;66(12):1298-1302.
33. Gunja N, Varshney K. Brainstem anaesthesia after retrobulbar block: a rare cause of coma presenting to the emergency department. *Emerg Med Australas.* 2006;18(1):83-85.



34. Nielsen PJ. Immediate visual capability after cataract surgery: topical versus retrobulbar anesthesia. *J Cataract Refract Surg.* 1995;21(3):302-304.
35. Caprioli J, Park HJ, Kwon YH, Weitzman M. Temporal corneal phacoemulsification in filtered glaucoma patients. *Trans Am Ophthalmol Soc.* 1997;95:153-167;discussion 67-70.
36. Park HJ, Kwon YH, Weitzman M, Caprioli J. Temporal corneal phacoemulsification in patients with filtered glaucoma. *Arch Ophthalmol.* 1997;115(11):1375-1380.
37. Kershner RM. Clear corneal cataract surgery and the correction of myopia, hyperopia, and astigmatism. *Ophthalmology.* 1997;104(3):381-389.
38. Kaufmann C, Peter J, Ooi K, et al. Limbal relaxing incisions versus on-axis incisions to reduce corneal astigmatism at the time of cataract surgery. *J Cataract Refract Surg.* 2005;31(12):2261-2265.
39. Freeman M, Kumar V, Ramanathan US, O'Neill E. Dehiscence of radial keratotomy incision during phacoemulsification. *Eye.* 2004;18(1):101-103.
40. McDonnell PJ, Taban M, Sarayba M, et al. Dynamic morphology of clear corneal cataract incisions. *Ophthalmology.* 2003;110(12):2342-2348.
41. Taban M, Sarayba MA, Ignacio TS, et al. Ingress of India ink into the anterior chamber through sutureless clear corneal cataract wounds. *Arch Ophthalmol.* 2005;123(5):643-648.
42. Collea KM, Hamilton WK. Effect of prophylactic antibiotics and incision type on the incidence of endophthalmitis after cataract surgery. *Can J Ophthalmol.* 2000;35(7):373-378.
43. Lundstrom M. Endophthalmitis and incision construction. *Curr Opin Ophthalmol.* 2006;17(1):68-71.
44. Ziakas NG, Georgiadis N. Conjunctival ballooning during scleral tunnel phacoemulsification. *J Cataract Refract Surg.* 2003;29(11):2046-2047.
45. Akura J, Funakoshi T, Kadonosono K, Saito M. Differences in incision shape based on the keratome bevel. *J Cataract Refract Surg.* 2001;27(5):761-765.
46. Grutzmacher RD, Oiland D, McKillop BR, Bunt-Milam AH. Donor corneal endothelial striae. *Am J Ophthalmol.* 1986;102(4):508-515.
47. Nartey IN, Ng W, Sherrard ES, Steele AD. Posterior corneal folds and endothelial cell damage in human donor eyes. *Br J Ophthalmol.* 1989;73(2):121-125.
48. Menapace R. Delayed iris prolapse with unsutured 5.1 mm clear corneal incisions. *J Cataract Refract Surg.* 1995;21(3):353-357.
49. Long DA, Monica ML. A prospective evaluation of corneal curvature changes with 3.0- to 3.5-mm corneal tunnel phacoemulsification. *Ophthalmology.* 1996;103(2):226-232.
50. Wirbelauer C, Anders N, Pham DT, Wollensak J. Effect of incision location on pre-operative oblique astigmatism after scleral tunnel incision. *J Cataract Refract Surg.* 1997;23(3):365-371.
51. Oshika T, Tsuboi S, Yaguchi S, et al. Comparative study of intraocular lens implantation through 3.2- and 5.5-mm incisions. *Ophthalmology.* 1994;101(7):1183-1190.
52. Agarwal A, Agarwal A, Agarwal S, et al. Phakinitis: phacoemulsification through a 0.9 mm corneal incision. *J Cataract Refract Surg.* 2001;27(10):1548-1552.
53. Steinert RF, Deacon J. Enlargement of incision width during phacoemulsification and folded intraocular lens implant surgery. *Ophthalmology.* 1996;103(2):220-225.
54. Kohnen T, Koch DD. Experimental and clinical evaluation of incision size and shape following forceps and injector implantation of a three-piece high-refractive-index silicone intraocular lens. *Graefes Arch Clin Exp Ophthalmol.* 1998;36(12):922-928.

55. Mencucci R, Ponchiotti C, Nocentini L, et al. Scanning electron microscopic analysis of acrylic intraocular lenses for microincision cataract surgery. *J Cataract Refract Surg.* 2006;32(2):318-323.
56. Prakash P, Kasaby HE, Agarwal RK, Humfrey S. Microincision bimanual phacoemulsification and Thinqtx implantation through a 1.70 mm incision. *Eye.* 2007;21(2):177-182.
57. Akura J, Kaneda S, Hatta S, Matsuura K. Controlling astigmatism in cataract surgery requiring relatively large self-sealing incisions. *J Cataract Refract Surg.* 2000;26(11):1650-1659.
58. Singer JA. Frown incision for minimizing induced astigmatism after small incision cataract surgery with rigid optic intraocular lens implantation. *J Cataract Refract Surg.* 1991;17(Suppl):677-688.
59. Vass C, Menapace R, Rainer G. Corneal topographic changes after frown and straight sclerocorneal incisions. *J Cataract Refract Surg.* 1997;23(6):913-922.
60. Wollensak J, Pham DT, Seiler T. [Effect of incision form and tunnel length on induced astigmatism with the no-stitch technique]. *Ophthalmologie.* 1994;91(4):439-441.
61. Pallin SL. Chevron sutureless closure: a preliminary report. *J Cataract Refract Surg.* 1991;17(Suppl):706-709.
62. Coombes A, Gartry D, eds. *Cataract Surgery.* London: BMJ Books; 2003:218.
63. Kim IS, Shin JC, Im CY, Kim EK. Three cases of Descemet's membrane detachment after cataract surgery. *Yonsei Med J.* 2005;46(5):719-723.
64. Nouri M, Pineda R, Jr, Azar D. Descemet membrane tear after cataract surgery. *Semin Ophthalmol.* 2002;17(3-4):115-119.
65. Ernest PH, Fenzl R, Lavery KT, Sensoli A. Relative stability of clear corneal incisions in a cadaver eye model. *J Cataract Refract Surg.* 1995;21(1):39-42.
66. Mackool RJ, Russell RS. Strength of clear corneal incisions in cadaver eyes. *J Cataract Refract Surg.* 1996;22(6):721-725.