

# The Physics of Wound Closure, Including Tissue Tactics

# 1

Larry Benjamin

## Key Points

- Principles of wound closure vary, depending on whether the wound is extraocular or involves opening the pressurized globe and subsequent closure. Preparation, avoidance of infection, and maintaining wound integrity are vital in good wound management.
- When suturing, the tissue should be well controlled to stabilize the area through which the needle passes. Desired results are best achieved when this is done.
- Closure of the skin of the eyelid is comparable to skin closure elsewhere. Differences exist in the structure detail(s) included in the closure. There are a number of techniques for working with the lid, conjunctiva, and cornea and sclera.
- Because of the inflexible nature of the cornea and sclera, tissue suturing here requires precise suture placement.
- Successful ophthalmic wound closure results from proper technique modification and suture tension.

## 1.1 Introduction

The closure of wounds in surgery relies on apposing surfaces and planes of tissue so that they can heal in an appropriate fashion. Knowledge of the biology of wound healing is important, as is being able to modify the processes involved to achieve the desired wound architecture in an appropriate time. When considering wound construction or repair in the cornea, wound anatomy and healing can both have a dramatic effect on visual outcome after the surgery because of the effect of surgically induced astigmatism on the corneal surfaces. Similarly, poor wound repair on the eyelid margins can have a long-term effect on the ocular environment by affecting lid closure and tear flow. This chapter addresses the forces and vectors involved in wound closure, the tactics used to achieve the desired effects, and how these relate to clinical principles.

## 1.2 Wound Architecture

### 1.2.1 Principles of Wound Closure

The principles of wound closure vary, depending on whether the wound is extraocular or involves opening the pressurized globe and subsequent closure. Paramount in the sequence of good wound management is preparation. This means adequate cleaning of surgical surfaces, excellent aseptic technique, as well as thorough postoperative care.

Avoiding infection is the best way to ensure wound integrity and healing in a timely fashion. In the eyelids, infection after surgery is uncommon, as there is a plentiful blood supply, but in the cornea and cavities of the globe, infection will last longer, cause more devastation, and be more difficult to eradicate.

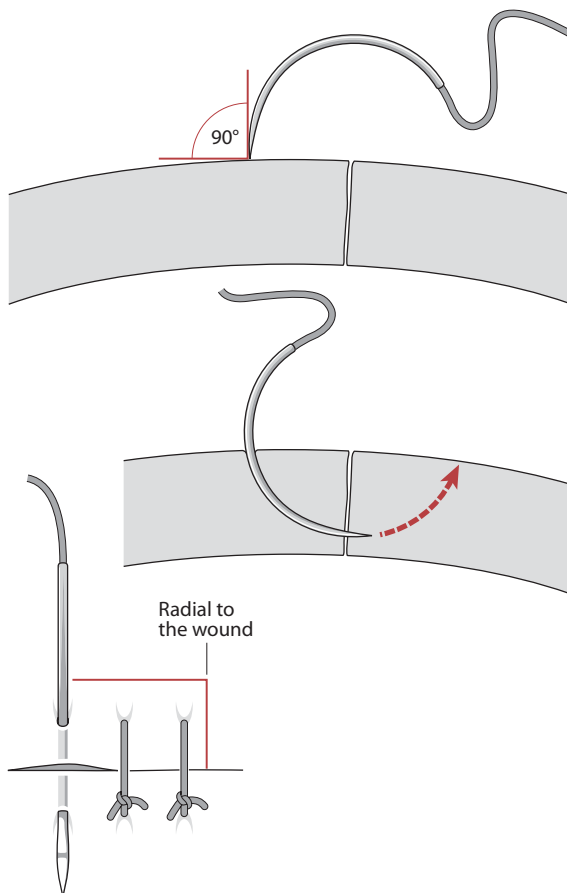
One of the overriding principles of wound closure is to keep the integrity of the body cavities intact and prevent ingress of infectious agents. In addition, when suturing the optical surfaces of the eye (any part that affects corneal curvature), care must be taken to avoid excessive astigmatic change while maintaining the integrity of the globe.

Choice of instrumentation is important, as some instrument tips may damage the delicate corneal tissues more than others. Toothed forceps will grasp tissue well but will puncture it. Notched forceps are more gentle and may be preferred, but under some circumstances where the tissue is edematous (such as after trauma), multiple attempts to grasp the tissue with notched forceps may result in further maceration and swelling, whereas a single sure grasp with toothed forceps may be preferable.

Microsurgery is distinctly different from general surgery. The operating microscope forces the surgeon to assume a particular posture that often must be maintained for several hours; the surgeon should sit in a natural position, leaning slightly forward, with a straight back and relaxed shoulders. Both feet should be flat on the floor. The visual field is restricted, as is the space for manipulation between the microscope

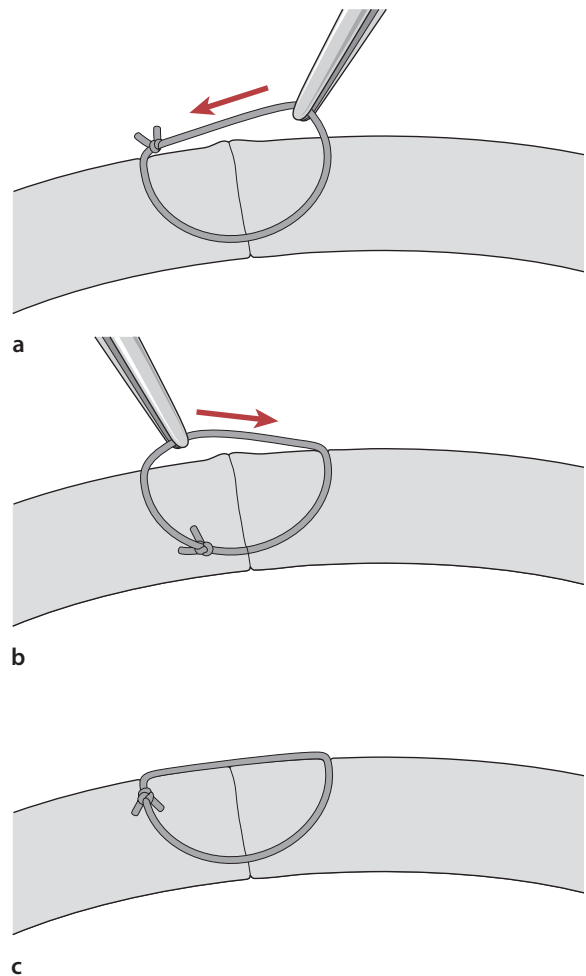
and the operative field. The operating microscope consists of the following elements: oculars, beam splitter, magnification system, and objective. Both focus and magnification should be adjustable with a remote foot control. The entire surgical field can be surveyed simply by dropping one's gaze to the operative field.

The function of sutures is to maintain apposition of wound edges artificially until scar tissue has attained sufficient strength. The ideal suture must appose the incised tissue edges in their normal anatomic position and provide adequate compression and minimal space for the scar tissue to bridge. Until formation of scar tissue is complete, the suture must maintain this apposition when external forces are applied. Simple interrupted suture presses the wound margins together and tends to assume a circular shape when tightened. When overtightened or overcompressed, the posterior aspect of the wound may gape, creating a fistula. Over-compression may cause the surgeon to place numerous unnecessary sutures to keep the wound watertight.



**Fig. 1.1** The needle is passed perpendicular to the surface of the tissue and exists equidistant from the point of entry when viewed from the anterior perspective of the laceration

Simple interrupted sutures produce inversion of the wound edges as the suture assumes a circular shape. Interrupted mattress sutures may produce inversion or eversion of the wound edges, depending on their placement and the degree of tightening. Continuous sutures flatten a convex wound and tend to straighten out curved incisions. The continuous suture will deform the surface when the suture bites are placed irregularly. Irregular sutures result from unequal suture depth placement, unequal length of suture passes and nonradial suture placement.



**Fig. 1.2** **a** After the knot is tied and the ends are cut short, the suture is grasped with smooth forceps and rotated into the tissue; care must be taken to avoid a twisting motion that may torque the tension on the suture and result in a shearing force that tears the tied suture. **b** The knot is then grabbed and rotated in the reverse direction. **c** The suture knot is now just beneath the surface of the tissue, and the ends extend away from the wound. This placement of the knot will facilitate removal as long as the knot is pulled out in a manner that does not require the knot to traverse the wound interface

### 1.3 Suture Placement

Tissue must be properly held in order to stabilize the area of tissue the needle is driven through. If this maneuver of passing the needle through the wounds edge is controlled, the desired results are achieved (Figs. 1.1 and 1.2). Using 0.12 mm forceps, the tissue should be held with the two-teeth side of the forceps on the same side of the tissue through which the needle is being driven.

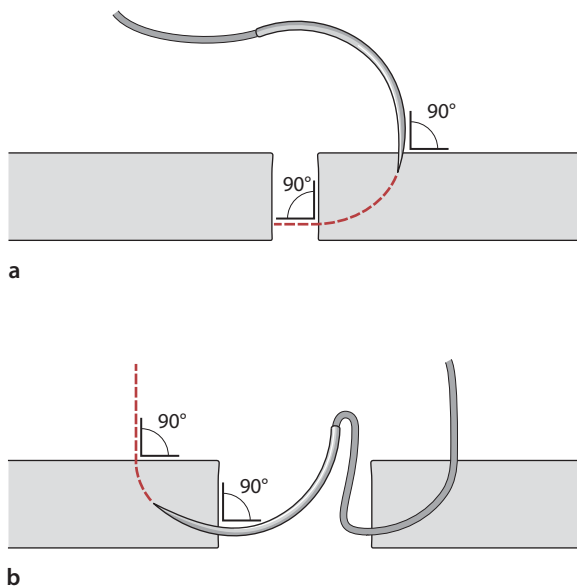
The needle should be two thirds of the way from the point of the surgical needle and held at a  $90^\circ$  angle from the needle holder. The needle must be parallel to the tissue plane (deviation will lead to tissue laceration with a side cutting spatulated needle), and slip (if not over tightend) or surgeon's knots may be used when tissue is under tension. After the wound is closed, the initial sutures may be replaced with astigmatically neutral sutures, surgeon's knots (2:1:1), at the desired tension, to avoid over compression of tissue, which can easily happen with slip knots that are tied to tightly.

#### 1.3.1 Suture Technique

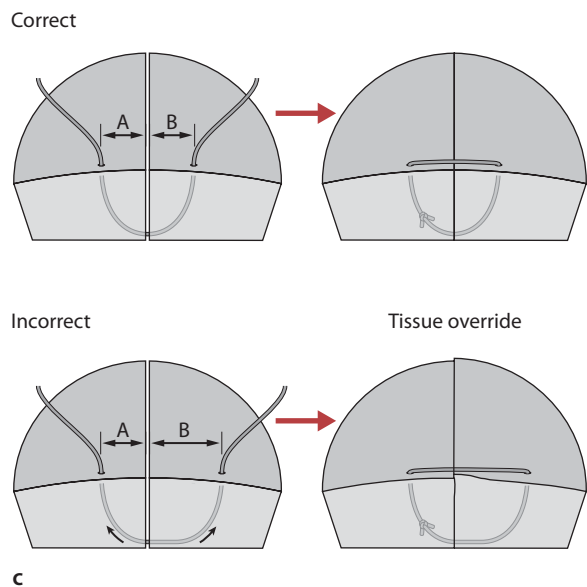
The suture passes should be of equal depth in the tissue on either side of the wound and of equal length. In this way, the wound will appose correctly without wound override or inducement of astigmatism. The greatest

accuracy is achieved when the needle is inserted perpendicular to the tissue surface and emerges perpendicular to the wound surface (Fig. 1.3). This placement causes minimal shift of the wound surface when the suture is tied. The needle can be passed in two steps. First, it is inserted perpendicular to the tissue surface, and it emerges perpendicular to the wound surface. The needle should be brought out through the wound surface, and then reinserted into the opposing wound surface perpendicular to the wound surface such that it exits perpendicular to the tissue surface. When using this technique, it is sometimes difficult for the surgeon to determine the proper insertion site in the opposing wound surface. Furthermore, it is important for the surgeon to consider that the depth at which the exiting needle exits should be the same depth as when the needle enters the opposing wound surface. If the surgeon inadvertently changes the direction of the needle when entering the opposing wound surface or exits and enters at differing depths, the resultant torque on the tissue will displace the entire wound. Easier passage of the needle tip through the tissue at 90 degrees can be accomplished by everting the distal lip of the wound so the depth of the wound can be accurately ascertained. This allows a flatter trajectory of the needle through the tissue and enables the surgeon to see the depth of both sides of the wound and accurately position the needle into the second half of the wound.

The incised tissue is fixated with fixation forceps, and the needle position must be adjusted according to the amount of tissue deformation caused by the for-



**Fig. 1.3** A needle is passed in two steps. a The needle is rotated posteriorly, and it enters the tissue surface in a perpendicular fashion ( $90^\circ$  angle) and emerges perpendicular to the wound surface. b The same angle of penetration is followed when the apposing tissue is entered perpendicularly and the



needle again emerges at a  $90^\circ$  angle to the tissue surface. This method causes minimal shift of the wound surface when the suture is tied. c This equal spacing of the suture results in correct wound apposition; unequal suture passes or bites can result in wound override and irregular astigmatism

ceps. The tissue should be fixated at the position where the suture is to be placed, not adjacent to this position. The needle shaft must be inclined posteriorly to allow the tip of the needle to pierce the tissue at a right angle. A deep semicircular stitch produces a large compression zone, which limits the number of interrupted sutures needed to close a wound. Care must be taken not to overtighten the sutures. Overtightening of sutures can shorten the suture track and deform the surrounding tissue, which interferes with wound closure. A single overcompressed suture can disrupt the closure of the full length of the wound. It is better to remove an overcompressed suture than to place numerous corrective sutures to provide countertension. These corrective sutures may make the wound watertight, but the result increases astigmatism.

### 1.3.2 Force Vectors of Sutures

All sutures produce vector forces that act in various directions as the suture is tightened. The vector forces extend in three different directions: perpendicular to the wound surface, parallel to the wound margin, and perpendicular to the tissue surface. If a suture is placed perpendicular to the wound surface, the force vectors cause compression in a line where the suture plane intersects with the wound surface. However, if the suture is placed obliquely, the compression vector force is an area on the wound surface; therefore, a lateral shift of the wound is produced. This shift is also the result of the vector force that is parallel to the wound margin. This force is not generated when the interrupted sutures are placed perpendicular to the wound. In continuous sutures, the shifting vectors of the bridging segments of the suture can serve to neutralize the shifting forces generated by each suture bite. The third vector component, perpendicular to the tissue surface, results in two forces in opposite direction in the simple interrupted suture. The first component results in eversion of the wound edge, and the second portion of the suture generates a force resulting in inversion of the wound edge. In the simple interrupted suture, these

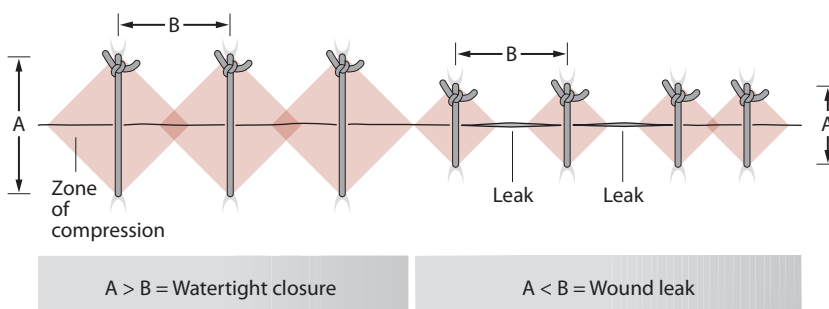
forces cancel each other out, and they are in opposite directions. Continuous sutures produce both inverting and everting forces that are cancelled out if the loops are placed very close together, otherwise, significant irregularities of the tissue surface result. An example of the continuous suture can be found in Chap. 6.

The effects of compressing vectors are maximal in the suture plane and diminish farther away from the suture. Each interrupted suture generates a zone of compression. The compressive effect is maximal in the plane between the point of suture entry and suture exit and falls off laterally. The action of the suture can be described in terms of force triangles extending laterally from the suture. The width of these compression zones depends on the length of the suture bites and the degree of suture tension after the suture is tightened. Adequate wound closure is achieved when the zones of compression of each interrupted suture overlap (Fig. 1.4).

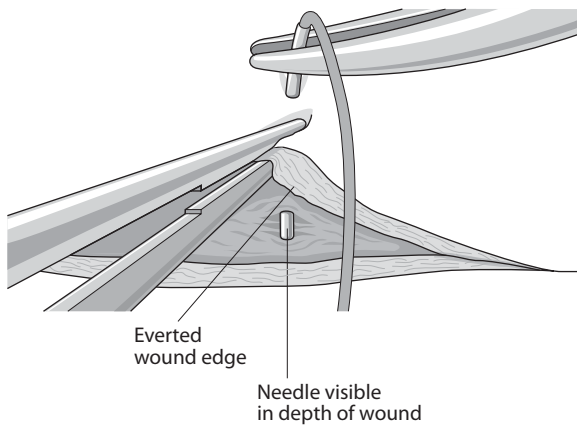
### 1.4 Lid Wound Closure

Closure of the skin of the eyelid is similar to skin closure elsewhere, although differences may exist in the detail of what structures are included in that closure. For example, incorporating the tarsal plate into the skin suture after a ptosis repair will cause a skin crease to form in the appropriate place. Essentially, lid skin closure is performed by placing a central suture, dividing the wound in half, and then dividing each half in half again. Deciding how many sutures to use depends on their length and tension. An adequate number of sutures have been used when the zone of compression of each suture overlap. Figure 1.4 shows the zone of compression for a single suture, which is the effective zone of closure that a suture exerts when tied at its particular tension. These zones should overlap slightly to ensure that the wound will not open between the sutures, and the closer the sutures are together, the more the adjacent compression zones overlap and the more secure will be the wound.

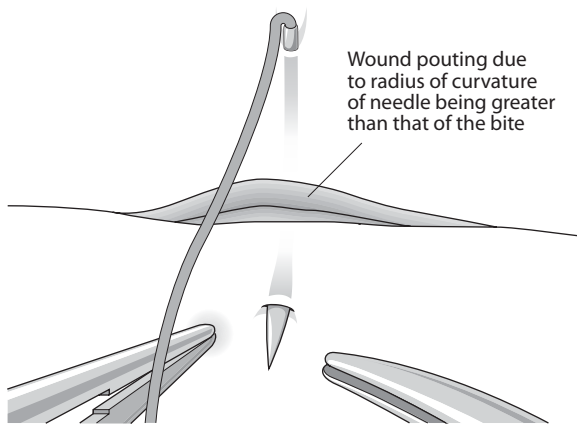
Decisions about suture placement are important in relation to their spacing, depth, tension, and length.



**Fig. 1.4** Zones of compression. Different lengths of suture bites result in different zones of compression. When the zones of compression overlap, adequate wound closure is achieved (arrows)



**Fig. 1.5** Everting the wound edge



**Fig. 1.6** Pouting of the wound

Usually, a suture should be symmetrical across a wound with equal depth and length across the wound. Suture bites are made with the needle at  $90^\circ$  to the tissue surface. Everting the wound edge is sometimes necessary to be able to see the placement of the needle tip as it enters the tissue (Fig. 1.5).

This also allows a view into the depth of the wound to ensure that the needle engages the opposite wound edge at the same depth. The suture track will sometimes be longer than the radius of curvature of the needle, which will make the wound pout when the needle is in both sides of the wound (Fig. 1.6).

The length of the suture track may be important in skin wounds, because if placed too close to the wound edge and made too tight, then avascular necrosis of the skin edge can occur. Skin sutures are usually tied slightly overtight to evert the edges together so that as healing progresses and subdermal involution of tissue occurs, the wound edges will end up flat.

## 1.5 Lid Margin Repair

There are a number of different techniques available for repairing lid margins, but the principles are the same. It is important to accurately align the three surfaces of the lid (skin, gray line, and conjunctiva) for an adequate time for healing to occur.

If a tarsal plate suture is used then additional skin sutures can be removed early (1 week), but if gray line and skin sutures are used without a cardinal tarsal suture, then they must be left in for 2 to 3 weeks to allow proper healing, especially if the wound is under tension such as when a proportion of the lid length has been removed in tumor removal or entropion repair. A cardinal tarsal suture should be placed horizontally parallel to the lid margin about 1 mm from its surface and should be within the lid substance entirely. In other words, the suture should not protrude through either skin at the front of the lid or conjunctiva at the back. A well-placed tarsal suture will provide the necessary strength and tension for the lid margin to heal with no notching, and will allow early removal of supplementary skin and lid margin sutures.

## 1.6 Conjunctiva Wound Repair

When suturing the conjunctiva, the surgeon must recognize the inherent tendency of the tissue to curl. When the conjunctival tissue curls, there is some retraction of the conjunctival epithelium. The retraction can be offset by countertraction on the subepithelial tissue. The epithelial layer can be recognized by its distinctive vascular pattern. Application of balanced salt solution to the cut margin of the conjunctival tissue makes this distinction easier because Tenon's capsule will appear white when the fibers are hydrated with the solution. Care must be taken to recognize the margin of the surgical dissection when suturing conjunctiva. When countertraction is applied, toothed forceps, such as 0.12-mm forceps, may be necessary to determine the margin of the surgical dissection and apply countertraction. If countertraction is not applied properly, inadvertent suturing of epithelial tissue in a subepithelial space can result in the postoperative formation of an epithelial inclusion cyst. Conjunctival tissue is extremely compliant, and postoperative adherence is accomplished rapidly because of the vascular substrate. Frequently, a rapidly absorbable suture, such as 8-0 collagen or 8-0, Vicryl is used to secure the conjunctival tissue in place.



## 1.7

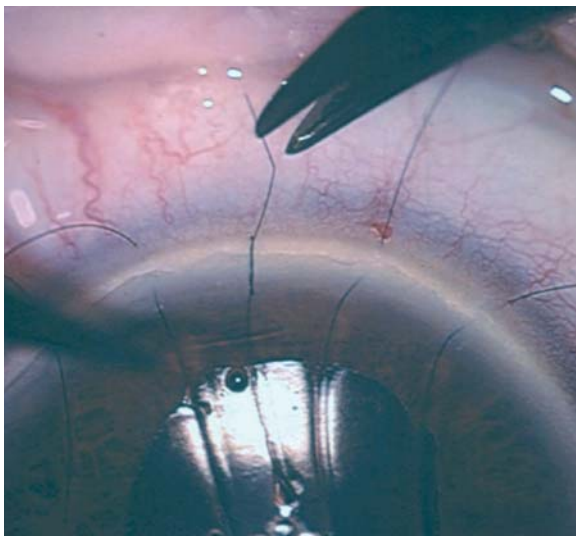
### Corneal Wounds and Repair

Because of the unyielding nature of the cornea and sclera, suturing of these tissues requires extremely precise placement of sutures. The needle track must cut through the lamellae of the tissue. Surgical wounds can be placed to facilitate closure, whereas traumatic wounds often require thinking on one's feet at the time of repair because of their unpredictable architecture. Sometimes a surgical wound becomes difficult to close predictably, for example, overenlarging a phacoemulsification tunnel to insert an implant may destabilize a supposedly self-sealing wound and necessitate suturing. Examples of wound architecture and closure techniques for cataract wounds are detailed in Chap. 4. In order for a wound to be self-sealing, it must create a valve-like effect.

#### 1.7.1

##### Closing the Large Limbal Wound

This can be done with interrupted sutures or a continuous one. The theoretical advantage of a continuous suture is the more even distribution of tension along the length of the wound and thus, hopefully less astigmatism. However, a tight continuous suture can cause just as much astigmatism as interrupted ones, and also have the disadvantage of being less flexible in terms of astigmatism control. If it breaks or loosens, the whole thing must be removed and possibly replaced, whereas selective removal of individual sutures can be useful to adjust astigmatism.



**Fig. 1.7** A 3-1-1 configuration of square knot (surgeon's knot) is used, and the first three throws can be laid down on the corneal surface at exactly the right tension to stop the wound opening

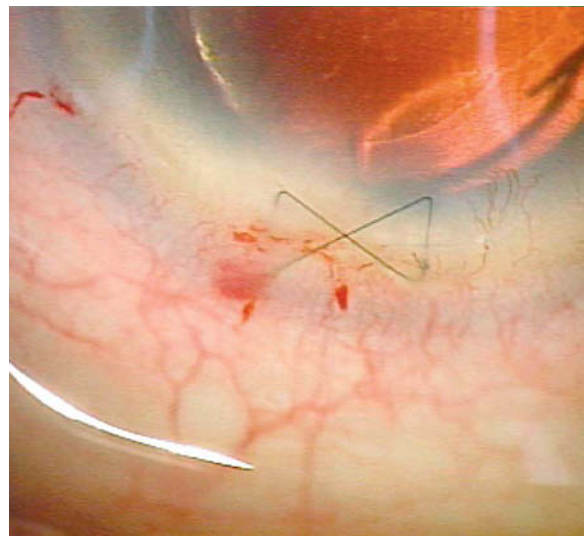
Assuming that the wound has been made 1 mm from the limbus and is beveled, then placement of the first 10-0 nylon suture is made centrally. The principle of this stitch is that it is used to stop the wound from opening, as opposed to keeping it closed. In principle, the wound will, if well constructed, keep itself closed and should heal with no astigmatism if left undisturbed. Clearly, patients cannot be asked to keep still for several weeks while the wound is healing, and so sutures are placed to keep the wound from opening. If this suture does not equally divide the wound, it will need to be replaced once sutures are placed on either side of the initial wound.

A 2-1-1 configuration of square knot (surgeon's knot) is used, and the first two throws can be laid down on the corneal surface at exactly the right tension to stop the wound opening, as shown in Fig. 1.7.

Subsequent throws are made to lock the knot at this tension, and it is imperative that proper square knots are made so that the tension in the first turns of the knot is not disturbed. Tying a square knot will ensure that it locks at the predetermined tension, whereas if a slipknot is inadvertently tied, the tension will increase as the knot slips rather than locks.

Further sutures are then placed either side of the first with equal spacing, length, depth, and tension and for wound of  $140^\circ$  in length, five sutures are usually adequate.

Overtightening a corneal suture will steepen the central curvature of the cornea and induce steepening in that meridian (causing a myopic shift in that meridian). Leaving them very loose may allow the corneal wound to "slip" (open slightly) and flatten the merid-



**Fig. 1.8** A simple butterfly or cross-stitch is all that is needed to close the wound, which will then effectively self seal as intraocular pressure is restored

ian concerned. It is therefore very important to make the wound self-sealing and tension the sutures to stop the wound from opening.

---

### 1.8 Suture Placement to Close a Phacoemulsification Wound

Occasionally a phacoemulsification wound is extended too far and becomes unstable. A simple butterfly or cross-stitch is all that is needed to close the wound, which will then effectively self-seal as intraocular pressure is restored, and the suture can be removed at a week (Fig. 1.8). A mattress suture is a good alternative to closing the wound, without inducing astigmatism.

---

### 1.9 Corneal Transplant Suturing

All transplant surgeons know that it is not possible to produce astigmatism-free wounds reliably. The principles of suturing these wounds include the need for a watertight wound, with sutures that are placed equally deep in both host and donor tissue. Full thickness sutures should be avoided (endothelial damage and a potential track for infection into the anterior chamber). A running suture should have even tension for  $360^\circ$ , and all knots should be buried. A continuous suture provides relatively even tension and is quicker to perform. Interrupted sutures should be used when infection or inflammation is present, as they can be selectively removed if necessary. The torque induced by a continuous suture can be counteracted by an opposite running suture and some surgeons will use a mixture of 10-0 nylon and 11-0 nylon to provide this torque and counter torque.

---

### 1.10 Wound Closure in Trauma

The unpredictable nature of traumatic wounds means that closure requires careful thought. Wounds may shelf in different directions from one end to the other, and reliable watertight closure requires various suturing techniques during the procedure. A typical shelved wound is shown in Fig. 1.9, and it makes sense to place the first suture in the most unstable portion of the wound. In this case, centrally, to make the wound more stable, which makes subsequent closure easier.

Chapter 7 demonstrates the approach that is needed with a shelved wound to ensure accurate wound edge apposition. The critical point is to make the depth of the suture equal in the deep part of the wound, or else

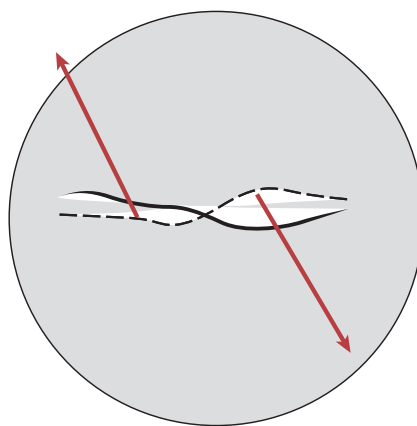


Fig. 1.9 A typical shelved wound

overriding of the wound edge may occur. An easy way to ensure that equal depth is achieved is to keep the length of the deep portion of the suture equal and the epithelial portion unequal.

---

### 1.11 Conclusion

Closure of some ophthalmic wounds is similar to other areas of surgical practice. However, specific differences exist in wounds relating to the globe and the effect that suturing can have on vision by dramatically disturbing optical surface curvature resulting in astigmatism. Modification of technique and suture tension is critical if satisfactory functional as well as anatomical results are to be obtained.