

Orbital apex disorders: a case series

**R. E. Warburton, C. C. D. Brookes,
 B. A. Golden, T. A. Turvey**
 Department of Oral and Maxillofacial Surgery,
 School of Dentistry, University of North
 Carolina at Chapel Hill, Chapel Hill, NC, USA

R. E. Warburton, C. C. D. Brookes, B. A. Golden, T. A. Turvey: Orbital apex disorders: a case series. Int. J. Oral Maxillofac. Surg. 2015; xxx: xxx–xxx. © 2015 International Association of Oral and Maxillofacial Surgeons. Published by Elsevier Ltd. All rights reserved.

Abstract. Orbital apex syndrome is an uncommon disorder characterized by ophthalmoplegia, proptosis, ptosis, hypoesthesia of the forehead, and vision loss. It may be classified as part of a group of orbital apex disorders that includes superior orbital fissure syndrome and cavernous sinus syndrome. Superior orbital fissure syndrome presents similarly to orbital apex syndrome without optic nerve impairment. Cavernous sinus syndrome includes hypoesthesia of the cheek and lower eyelid in addition to the signs seen in orbital apex syndrome. While historically described separately, these three disorders share similar causes, diagnostic course, and management strategies. The purpose of this study was to report three cases of orbital apex disorders treated recently and to review the literature related to these conditions. Inflammatory and vascular disorders, neoplasm, infection, and trauma are potential causes of orbital apex disorders. Management is directed at the causative process. The cases described represent a rare but important group of conditions seen by the maxillofacial surgeon. A review of the clinical presentation, etiology, and management of these conditions may prompt timely recognition and treatment.

Key words: orbital apex syndrome; superior orbital fissure syndrome; cavernous sinus syndrome; orbital compartment syndrome; ptosis; proptosis; ophthalmoplegia; optic neuropathy; maxillofacial surgery.

Accepted for publication 16 October 2015

Orbital apex syndrome (OAS) is an uncommon disorder characterized by impairment of cranial nerves III, IV, VI, and the ophthalmic branch of cranial nerve V, and optic neuropathy. Patients present with ophthalmoplegia, proptosis, ptosis, visual impairment, a fixed dilated pupil, and hypoesthesia of the ipsilateral forehead, upper eyelid, and cornea.¹ Superior orbital fissure syndrome (SOFS) presents similarly to OAS, without the accompanying optic nerve impairment.^{2,3} Cavernous sinus syndrome (CSS) involves palsy of cranial nerves III, IV, and VI, optic neuropathy,

oculosympathetic paresis, and impairment of the ophthalmic and maxillary branches of cranial nerve V.¹ CSS presents with ophthalmoplegia, ptosis, proptosis, decreased vision, and loss of sensation in the ipsilateral forehead, eyelids, cornea, and cheek.^{4,5} CSS can present bilaterally.¹ Cranial nerve involvement may be complete or incomplete in all three syndromes.

While frequently described separately in the literature, these three orbital apex disorders share a similar etiology, diagnostic course, and treatment.^{1,6} These syndromes can be progressive in nature, with

SOFS developing into OAS or CSS.¹ For the purpose of discussion OAS, SOFS, and CSS can be grouped together as a single condition, differentiated chiefly by the anatomical position of the causative pathology.

Three new cases of orbital apex disorders are reported to illustrate the three syndromes and highlight several key causative factors. The relevant anatomy, etiology, and available diagnostic and treatment modalities are also described.

This study was reviewed by the Institutional Review Board and deemed exempt.

Case series

Case 1

A 16-year-old Caucasian male with marked midfacial hypoplasia, retrogenia, and right-sided hemihypoplasia presented for a Le Fort III osteotomy modified to maintain nasal position, right split thickness parietal bone harvest with grafting to the bilateral supraorbital rims and mid-face, and genioplasty. Preoperative ophthalmic evaluation revealed normal vision (20/20 in the right eye (OD) and 20/25 in the left eye (OS)) with no afferent pupillary defect or anisocoria.

The patient was administered 125 mg of methylprednisolone and 1 g of cefazolin intravenously at the start of the procedure and every 4 h subsequently. The midface was mobilized and advanced without difficulty. The inner cortex remained intact during the parietal bone harvest. The orbital osteotomies were located within 1 cm of the orbital rim and carried into the inferior orbital fissure. No fracture or extension of the osteotomies to the orbital apex was observed.

Upon completion of the procedure, the right pupil was noted to be fixed and dilated with a 4-mm discrepancy when compared to the left pupil. Bilateral pupils were non-reactive, which was attributed to the depth of anesthesia. The coronal and intraoral incisions were reopened and the right orbit was explored, with no hematoma or pulsatile bleeding noted. Ophthalmology was consulted to help evaluate for an intraorbital cause of the patient's anisocoria. Intraocular pressures were found to be normal at 15 mmHg OD and 20 mmHg OS by handheld tonometry. The neurosurgery service was consulted to rule out any intracranial pathology. An emergency computed tomography (CT) of the head and face was obtained, which revealed no intracranial hemorrhage, midline shift, or brainstem compression. No fracture or hematoma involving the superior orbital fissure or orbital apex was noted (Fig. 1). The patient's surgical wounds were then closed and he was transferred to the pediatric intensive care unit for close neurological monitoring.

The patient's postoperative ophthalmic examination revealed complete right ophthalmoplegia, mild proptosis, and moderate ptosis. The right pupil was 6 mm and non-reactive to direct light, although the consensual response was intact. The patient initially reported blurred vision OD that improved through a pin-hole occluder. Color vision was intact. He had binocular diplopia as well as anticipated cranial nerve V deficits. The remain-

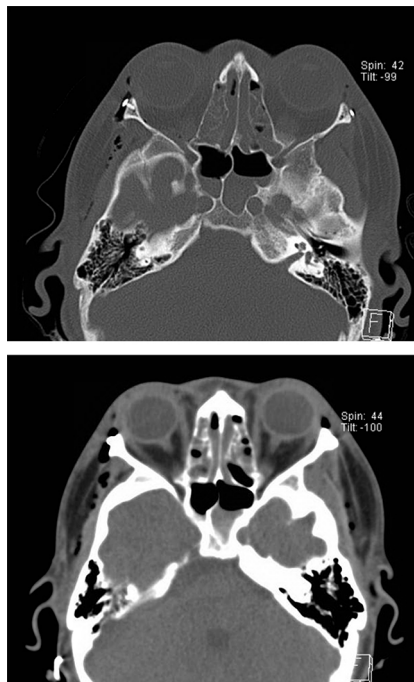


Fig. 1. Intraoperative CT scan revealing no fracture or hematoma involving the right orbital apex or optic canal.

der of his neurological examination was benign. Magnetic resonance imaging (MRI) of the brain and orbits was performed, which revealed no signs of orbital apex compression or intracranial pathology.

The patient was diagnosed with a presumed SOFS. Intravenous methylprednisolone (125 mg) was continued every 4 h throughout his hospitalization. A formal ophthalmic evaluation at less than 24 h after surgery found visual acuity to be 20/40 OD, 20/20 OS. The patient underwent serial ophthalmic examinations, which showed slight improvement in ptosis and continued ophthalmoplegia. The patient was discharged on postoperative day 2 with a 7-day prednisone taper. At the time of discharge, the patient's vision was 20/30 OD, 20/20 OS with a 2-mm discrepancy in pupillary size and minimal reactivity to light OD.

Three weeks postoperatively, the patient showed improved extraocular movements and ptosis OD. The binocular diplopia and pupillary dilation remained. Five weeks postoperatively, the ptosis and ophthalmoplegia had improved greatly. The right pupil remained dilated with some residual binocular diplopia. At the 10-week follow-up, all symptoms had resolved.

Case 2

A 15-year-old Caucasian male with asthma and chronic rhinosinusitis presented to

clinic with a 4-day history of right midfacial pain and swelling without orbital involvement. He was admitted to the hospital with a presumed facial infection of unknown cause for further work-up and intravenous antibiotics. Shortly after admission, the patient developed rapid onset of ophthalmoplegia, proptosis, ptosis, and complete vision loss OD. The right pupil was found to be fixed and dilated. Ophthalmology was consulted and the patient was found to have an intraocular pressure of 57 mmHg OD by handheld tonometry. The patient was diagnosed with an OAS secondary to an orbital compartment syndrome, and an emergency lateral canthotomy with inferior cantholysis was performed bedside. Intraocular pressure improved to 38 mmHg OD after the procedure. Vision loss and ophthalmoplegia were unchanged. Brimonidine and dorzolamide/timolol were administered topically and an emergency CT of the face was obtained. Imaging revealed a large cystic mass in the right maxillary sinus with erosion of the posterior maxillary sinus wall and right orbital cellulitis with posterior globe tenting (Fig. 2).⁷

The patient was taken as an emergency to the operating room for drainage of the right maxillary sinus via a Caldwell-Luc approach and further orbital decompression. Otolaryngology was contacted to determine the benefit of concomitant endoscopic sinus surgery, but the decision was made to defer additional sinus intervention at that time. After drainage of the maxillary sinus, the right intraocular pressure improved to 16 mmHg by handheld tonometry and no additional orbital decompression was pursued. Cultures were obtained and the maxillary sinus contents were sent for histopathological evaluation.

Postoperative visual acuity improved to 20/200 OD. The right pupil was sluggishly reactive. Ophthalmoplegia was unchanged. The patient was started on vancomycin and piperacillin/tazobactam. Maxillary sinus cultures revealed no growth. The intraoperative pathology results returned as sinonasal mucosa with features consistent with acute on chronic rhinosinusitis. Serial ophthalmic examinations revealed improved visual acuity and pupillary reactivity, although extraocular motility deficits persisted.

The patient was discharged to home on postoperative day 5 with a 7-day course of amoxicillin/clavulanic acid. Visual acuity was 20/25 + 2 OD, 20/20 OS at the time of discharge. Subsequent ophthalmology follow-up at 1 month revealed resolution of symptoms except for a persistent right inferior arcuate defect. The patient

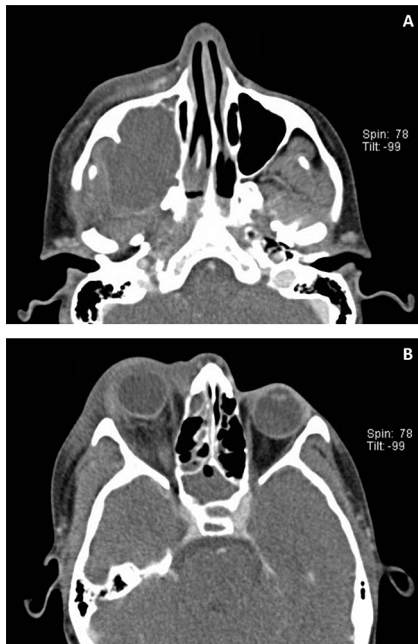


Fig. 2. (A) CT scan demonstrating a large right maxillary cystic mass with erosion of the posterior maxillary sinus wall extending into the right infratemporal fossa. (B) CT scan demonstrating right orbital cellulitis and partial opacification of the right ethmoid and sphenoid sinuses. Right posterior globe tenting is present, signifying an acute increase in intraorbital pressure with stretching of the optic nerve.

underwent right-sided functional endoscopic sinus surgery with right maxillary antrostomy and right anterior ethmoidectomy approximately 3 months after his initial presentation.

Case 3

A 44-year-old Caucasian female presented to clinic 4 days after a motor vehicle accident. She had been seen initially by an outside emergency department where her head and cervical spine had been cleared. Upon evaluation she was found to have a right mandibular body and left mandibular angle fracture. A left cheek laceration had been closed at the outside emergency department. Only axial cuts from the outside hospital CT scans were available; these demonstrated a minimally displaced left lateral maxillary sinus wall fracture in addition to the fractures described above.

The patient was taken to the operating room for open reduction and internal fixation of her bilateral mandible fractures with wire maxillomandibular fixation. The patient did well postoperatively and was discharged home with oral antibiotics following the procedure.

On postoperative day 3, the patient returned to clinic with left peri-orbital pain and swelling, which had started the day after surgery. Ophthalmology was consulted and reported left orbital proptosis, partial ophthalmoplegia, and chemosis. Visual acuity was 20/40-1 OD, 20/60-1 OS and intraocular pressure was 12 mmHg OD, 21 mmHg OS by handheld tonometry. The patient's pupils remained symmetric and reactive, with no afferent pupillary defect. No changes in color vision or hypoesthesia of the left forehead, eyelids, or cheek were noted.

The patient was sent to the emergency department for a CT of the head and face with a presumed orbital cellulitis. She was administered a dose of intravenous clindamycin and dexamethasone, as well as topical brimonidine and dorzolamide/timolol. Imaging confirmed prior fractures and additionally revealed a minimally displaced left orbital floor fracture. No hematoma, cellulitis, or entrapment was noted. Mild dilation of the left superior ophthalmic vein was observed. Detection of a temporal bruit by the maxillofacial surgery team prompted further investigation with CT angiography, which revealed a left carotid-cavernous fistula (Fig. 3).

The patient underwent transarterial coil embolization of the left carotid-cavernous fistula by interventional radiology without event. The patient was monitored overnight in the neurosurgical intensive care unit. Serial ophthalmic examinations demonstrated marked improvement in proptosis, ptosis, chemosis, and extraocular motility. The patient was transferred to the ward after 24 h and was discharged to home on hospital day 3 with dorzolamide/timolol eye drops and erythromycin ointment.

The patient was evaluated by ophthalmology 12 days after discharge. She reported mild blurred vision at a distance and diplopia with left gaze. Examination revealed a left esotropia consistent with left abducens palsy. The patient was seen 6 weeks after discharge for a follow-up arteriogram, which showed no residual arteriovenous shunting. Further ophthalmic evaluation at 11 weeks noted a resolved left esotropia and no residual defects.

Discussion

Anatomy

The orbit is pyramidal in shape, consisting of four walls, an apex, and a base.⁸ The orbit is approximately 40–50 mm deep, with the apex encompassing the posterior

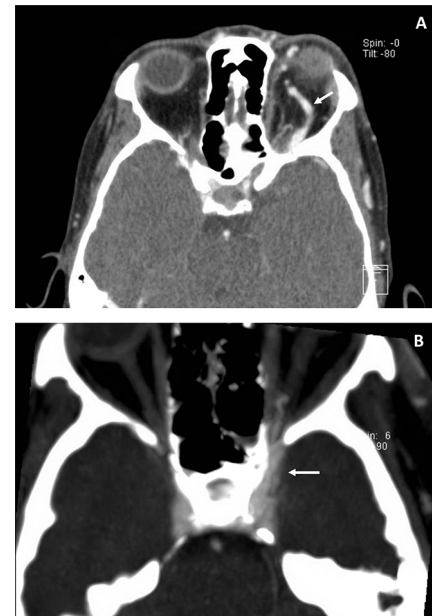


Fig. 3. (A) CT scan demonstrating left orbital proptosis and enlargement of the left orbital vasculature (arrow). (B) CT angiography revealing an enlarged left cavernous sinus (arrow), mild enlargement of the left extraocular musculature, and engorgement of the left superior ophthalmic vein indicative of a carotid-cavernous fistula.

13–17 mm of the orbit.⁹ The superior orbital fissure follows the junction of the roof and the lateral wall and is formed medially by the lesser wing of the sphenoid and laterally by the greater wing of the sphenoid. The optic canal is located in the superomedial corner of the orbital apex and is formed by the two roots of the lesser wing of the sphenoid.⁹

The annulus of Zinn, from which four of the six extraocular muscles attach, encloses the optic foramen and the medial portion of the superior orbital fissure (Fig. 4). The annulus of Zinn contains the optic nerve, ophthalmic artery, cranial nerves III and VI, and the nasociliary nerve.⁹ These structures are at greater risk of compression or shear injury as a result of their confinement within the annulus of Zinn.³ The lateral portion of the superior orbital fissure contains cranial nerve IV, the frontal nerve, the lacrimal nerve, and the superior ophthalmic vein.⁹ Cranial nerve IV is less frequently involved in SOFS and OAS secondary to its anatomical location outside the annulus of Zinn.^{3,10}

The cavernous sinuses are located lateral to the sella turcica and posterior to the superior orbital fissure. The ophthalmic and maxillary branches of cranial nerve V and cranial nerves III and IV pass through the lateral wall of the cavernous

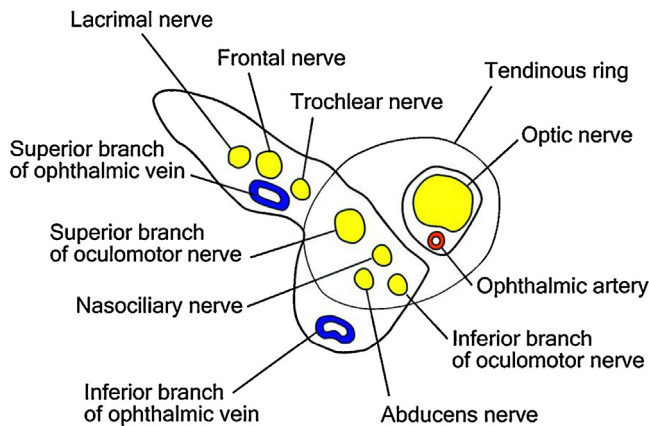


Fig. 4. Schematic of the right orbital apex contents (from Chen et al.³).

sinus. The internal carotid artery and post-ganglionic sympathetic fibers pass through the medial portion of the sinus. Cranial nerve VI travels within the sinus between the internal carotid artery and the lateral wall.¹¹

The clinical features of OAS, SOFS, and CSS are based on the anatomical position of the pathological process. Impairment of cranial nerves III, IV, and VI results in ophthalmoplegia.³ Proptosis occurs due to the loss of extraocular muscle tension on the globe, retrobulbar swelling, or venous congestion.² Ptosis can be caused by impaired cranial nerve III innervation to the levator palpebrae superioris muscle or by loss of sympathetic innervation to the superior tarsal muscle.⁸ Mydriasis occurs as a result of impaired parasympathetic innervation from cranial nerve III.² Loss of corneal reflex is caused by involvement of the nasociliary nerve.

Damage to the optic nerve can occur at the optic disc, or along the intraorbital, intracanalicular, or intracranial portions of the nerve.¹² Most traumatic injury occurs at the intracanalicular portion of the optic nerve.^{12,13} This is due to the periosteum of the optic canal being continuous with the dural covering of the optic nerve as it passes through the canal, causing the optic nerve to be more susceptible to compression, tension, or shear injury.^{3,9}

CSS can involve both the ophthalmic and maxillary branches of cranial nerve V, reflecting their position along the lateral wall of the cavernous sinus.⁵ Cranial nerve VI is more frequently involved in CSS when compared to cranial nerve III and cranial nerve IV, due to its location within the sinus.⁴ Communication via the intercavernous sinuses can result in bilateral cavernous sinus involvement.

The orbit is functionally a closed compartment, with anterior expansion limited by the orbital septum, tarsi, and medial

and lateral canthal tendons. Rapidly progressive intraorbital pressure can result in an orbital compartment syndrome, leading to ischemic damage to the retina and optic nerve, potentially resulting in permanent vision loss.¹⁴

Etiology

Inflammatory disorders

Multiple granulomatous inflammatory diseases have been implicated in orbital apex disorders. Granulomatosis with polyangiitis, Churg–Strauss syndrome, and sarcoidosis have all been described.^{1,5,15} Tolosa–Hunt syndrome is a rare disorder caused by granulomatous inflammation of the orbital apex or cavernous sinus in which patients present with unilateral orbital pain and ophthalmoplegia that typically resolves within 72 h of corticosteroid therapy.^{1,16} Optic neuropathy is rare and symptoms can be recurrent.

Extraocular myositis can be idiopathic or secondary to Graves' ophthalmopathy.¹⁵ Clinical features of Graves' ophthalmopathy include exophthalmos, eyelid retraction with lagophthalmos, chemosis, and conjunctival injection. Restrictive ophthalmoplegia and visual impairment can occur in advanced cases.¹⁷ Graves' ophthalmopathy typically consists of an active inflammatory phase and an inactive fibrotic phase.¹⁸ Symptoms are a result of autoimmune-mediated extraocular muscle enlargement and adipogenesis, which increases intraorbital pressure and impedes venous drainage.¹⁹

Neoplasms

Primary neural tumors affecting the orbital apex include neurofibroma, schwannoma, pituitary adenoma, glioma, and meningioma.^{1,19} Adenoid cystic carcinoma,²⁰ squamous cell carcinoma,²¹ or mucoepidermoid

carcinoma²² can involve the orbital apex via perineural spread, local invasion, or metastasis. Rhabdomyosarcoma is one of the most common orbital tumors of childhood, and can cause an OAS via mass effect or direct invasion.²³ Lymphoma affecting the orbital apex can arise from localized invasion from the paranasal sinuses, skull base, or from distant metastasis. Primary lymphoma of the orbital apex has also been reported.²⁴ Metastatic melanoma, breast, kidney, or lung cancer can also result in an orbital apex disorder.¹

Infection

Chandler et al.²⁵ classified orbital infections into five groups: preseptal cellulitis, orbital cellulitis, sub-periosteal abscess, orbital abscess, and cavernous sinus thrombosis.

Preseptal cellulitis can occur as a result of acute sinusitis, upper respiratory infection, peri-orbital trauma, or otitis media.²⁶ Due to the orbital septum acting as a barrier, preseptal cellulitis rarely progresses into the orbit and can be differentiated from other forms of orbital infection by the absence of visual or extraocular movement impairment.^{26,27}

Sinusitis is the most common cause of orbital cellulitis, sub-periosteal and orbital abscesses, and septic cavernous sinus thrombosis.^{27,28} Children are more commonly affected than adults.²⁷ Infection may be transmitted directly via the lamina papyracea of the ethmoid bone, which is thin with multiple dehiscences that can allow for communication between the ethmoid sinuses and the orbit.²⁷ Infection can also be spread from the maxillary or frontal sinuses through bony erosion or pre-existing dehiscence of the sinus walls. Indirect transmission of bacteria between the paranasal sinuses, orbit, and the cavernous sinus can also occur through the venous system that drains this anatomical region.²⁹ Case patient 2 presented with a maxillary sinus infection with erosion of the posterior maxillary sinus wall and involvement of the pterygopalatine fossa, potentially allowing for infection to progress into the orbit via the inferior orbital fissure.

Staphylococcus aureus, *Streptococcus pneumoniae*, and anaerobic Gram-negative bacilli such as *Prevotella*, *Porphyromonas*, and *Fusobacterium* have been noted frequently upon culture.^{1,28,30} Mucormycosis and aspergillosis have been implicated in immunocompromised hosts.^{1,31} As seen in case patient 2, an acute orbital compartment syndrome can

result from a rapidly progressive orbital infection.

Trauma

Orbital apex disorders can occur as a result of craniomaxillofacial trauma. Limited data are available regarding the incidence of OAS or CSS; however retrospective studies have found the incidence of SOFS after facial trauma to range from 0.3% to 0.8%.^{10,32} Fractures associated with the orbital apex include skull base, high Le Fort, orbital, nasoorbitoethmoidal, and zygomaticomaxillary complex fractures.^{9,10,32}

Direct and indirect mechanisms of injury can occur.³³ Direct injury can be a result of penetrating trauma or impingement of the orbital apex by displaced bony fragments. Indirect injury occurs by transmission of shear forces to the superior orbital fissure or optic canal from the surrounding facial skeleton.^{34,35} This can result in orbital axonal damage and injury to the pial vessels supplying the optic nerve, resulting in ischemic necrosis or compressive hematoma formation.^{12,34} Post-traumatic intracanalicular optic nerve swelling and vasospasm can result in further damage.^{34,36} Reperfusion of neuronal tissue can result in the formation of free radicals, leading to lipid peroxidation and cell membrane damage.¹³

Trauma is a well-known cause of orbital compartment syndrome. It is generally a result of retrobulbar hemorrhage, orbital emphysema, or retrobulbar edema. The incidence of retrobulbar hemorrhage resulting in orbital compression ranges from 0.45%³⁷ to 3.6%,³⁸ with most cases associated with fractures of the orbit or zygomaticomaxillary complex. Orbital emphysema is typically a benign condition associated with 50%³⁹ to 60%⁴⁰ of orbital fractures. In rare cases, an orbital compartment syndrome can occur when the orbital adnexa occludes a traumatic communication between orbit and paranasal sinuses, creating a one-way valve that allows air to enter the orbit but not escape.^{39,41} Sneezing, vomiting, or nose blowing can drive air into the orbit resulting in an acute increase in retrobulbar pressure.⁴¹ The use of a high-speed air-cooled dental drill during dentoalveolar surgery has also been implicated in the development of a compressive orbital emphysema.⁴²

Orbital apex disorders have also been reported during Le Fort osteotomies. This has been attributed to atypical fracture propagation or indirect transmission of forces to the skull base during pterygo-

maxillary disjunction.⁴³ In case patient 1, no fracture of the superior orbital fissure or optic canal was noted in postoperative imaging. There was an air-fluid level in the sphenoid sinus, possibly indicating a non-displaced sphenoid fracture. Indirect transmission of sheer or concussive forces, or swelling of the orbital apex in the setting of hypotensive anesthesia, resulting in ischemic neuropathy, can also not be excluded as a potential cause of the patient's SOFS.

Vascular disorders

Carotid-cavernous fistulas, cavernous sinus thrombosis, and cavernous carotid aneurysms can result in an orbital apex disorder. Carotid-cavernous fistulas are traditionally classified as direct or indirect lesions. Direct carotid-cavernous fistulas arise from a communication between the internal carotid artery and the cavernous sinus.⁴⁴ They are typically high-flow lesions that are most commonly associated with trauma.¹¹ Injury to the carotid artery can be the result of penetrating trauma or laceration secondary to bony fracture. Transmission of traumatic forces to the arterial wall, or an abrupt increase in intraluminal pressure can potentially lead to rupture.^{11,45} Carotid-cavernous fistulas give rise to venous hypertension and congestion, resulting in the characteristic triad of acute onset pulsatile exophthalmos, chemosis, and bruit.⁴⁶ Venous hypertension can lead to intracranial hemorrhage, massive epistaxis, and cerebral or retinal ischemia.^{11,47}

Indirect carotid-cavernous fistulas are caused by communication between the cavernous sinus and dural branches of the internal carotid artery, the external carotid artery, or both.⁴⁴ They are largely low-flow, spontaneous in nature, and less commonly associated with trauma.¹¹ Clinical symptoms are generally less severe.

Aseptic cavernous sinus thrombosis can potentially occur in patients predisposed to a hypercoagulable state. Trauma, malignancy, post-surgical status, inflammatory bowel disease, polycythemia vera,⁴⁸ acquired and hereditary coagulopathies, pregnancy, and oral contraceptives can result in thrombus formation.^{49,50}

Cavernous carotid aneurysms can occur as a result of trauma, infection, atherosclerosis, or congenital weakening of the arterial wall.⁵¹ Approximately 18%⁵² to 34%⁵³ of cavernous carotid aneurysms are asymptomatic and are typically discovered incidentally on imaging studies. The most commonly reported symptoms are orbital pain and diplopia.⁵² Anterior

growth of a cavernous carotid aneurysm can result in compression of the optic nerve or superior orbital fissure, leading to an OAS or SOFS. CSS can occur as a result of lateral aneurysm growth.⁵³ Cavernous carotid aneurysms in rare instances can result in intracranial hemorrhage, carotid-cavernous fistula formation, or thromboembolism causing distal cerebral infarction.⁵¹

Diagnosis

An orbital apex disorder is diagnosed clinically. A detailed history and physical examination should be performed on any patient in whom an orbital apex pathology is suspected. This must include a complete ophthalmic evaluation, followed by serial examinations, ideally by the same provider.

Imaging is important in discerning the causative etiology. MRI or fine-cut CT imaging of the head and face is helpful in characterizing neoplastic, infectious, or inflammatory disorders. The non-contrast fine-cut CT scan of the head and face is the study of choice to evaluate for orbital apex fractures in craniomaxillofacial trauma.⁹ Magnetic resonance angiography or CT angiography can help identify vascular causes.¹ Laboratory tests are ordered as indicated by the history, physical examination, and imaging findings. Biopsy can be obtained in cases of orbital apex masses.

Orbital compartment syndrome is an emergency condition differentiated clinically from other orbital apex disorders by a rapidly progressive loss of vision and tense proptosis.¹⁴ Intraorbital pressure can be estimated by digital palpation of the globe or more precisely approximated by measurement of intraocular pressure by tonometry. Cadaveric models have found a close correlation between intraorbital and intraocular pressures.^{54,55} Normal intraocular pressures range from 10 to 20 mmHg.⁵⁶ An acute change in intraocular pressure exceeding 40 mmHg can result in compromised blood flow to the optic disc, resulting in ischemia.^{57,58} Intraocular pressure above 40 mmHg via tonometry in the setting of a suspected orbital compartment syndrome is an indication for emergency surgical decompression.^{59,60} Measurement of intraocular pressure is also necessary to provide a starting point by which the efficacy of any treatment can be compared. Care should be taken when interpreting intraocular pressures in the glaucoma patient, as they may be chronically elevated.

Treatment

Inflammatory disorders

Granulomatous inflammatory disorders are managed in a multidisciplinary setting with systemic immunomodulatory agents, including corticosteroids, cyclophosphamide, methotrexate, and azathioprine.^{19,61} The treatment of Graves' ophthalmopathy is dependent on the clinical phase of the disease. In the acute phase, management consists of immunosuppression with corticosteroids or external beam radiotherapy. Surgical decompression of the orbit if indicated is recommended during the inactive phase.^{18,19}

Neoplasms

The management of neoplasms of the orbital apex is dictated by the causative pathology. Surgical resection, radiation therapy, and chemotherapy are all potential treatment modalities.

Infection

Orbital cellulitis, orbital abscesses, and sub-periosteal abscesses should be treated aggressively with broad-spectrum intravenous antibiotics that cover staphylococci and streptococci. Anaerobes are found in 24% of post-septal orbital infections and should also be considered when selecting antibiotic coverage.²⁷ Final antibiotic therapy should be dictated by culture and susceptibility test results.

There has been little investigation into the effects of corticosteroids on orbital infections. A retrospective study of 23 patients with a sub-periosteal abscess reported no adverse outcomes in patients who received corticosteroids in addition to routine treatment.⁶² A prospective, single-blind study of 21 patients treated for an orbital infection showed improvement of ptosis, proptosis, visual acuity, and extraocular movements when corticosteroids were administered starting on hospital day 4 compared to antibiotics alone.⁶³ This study, however, excluded pediatric patients under 10 years old.

In addition to broad-spectrum antibiotic coverage, surgical intervention is indicated in the presence of an orbital or sub-periosteal abscess. The management of sub-periosteal abscesses is somewhat controversial. Some authors suggest a trial of antibiotic therapy with close ophthalmic observation in patients less than 9 years old with no visual impairment and a small medially located abscess. Patients who are over 9 years old, fail to improve with antibiotic therapy, or present with visual

impairment should undergo surgical drainage.^{27,64}

There have been many different surgical approaches described in the literature. The medial orbit can be approached via a Lynch–Howarth or transcaruncular incision.²⁷ This allows for surgical access to the ethmoid sinuses via the lamina papyracea, as well as the medial aspect of the superior orbit. A transconjunctival approach allows for access to the inferior orbit.⁶⁵ A Caldwell–Luc approach, as utilized in case patient 2, can be used for infections involving the maxillary sinus.

A transnasal endoscopic approach is often preferred in the management of medial sub-periosteal abscesses.^{65,66} This approach allows for improved cosmesis, reduced postoperative edema, and shortened hospitalization times compared to traditional external approaches.⁶⁶ Superior or inferior extension of the sub-periosteal abscess can require a combined external and endoscopic approach.

Case patient 2 presented with a maxillary sinus infection that rapidly progressed into the orbit, resulting in an acute orbital compartment syndrome. Management of this emergency condition requires prompt recognition and treatment to avoid permanent vision loss. The decision to treat should be decided based on clinical presentation and not delayed to obtain imaging studies. Hayreh et al.,^{67,68} in studies involving rhesus monkeys in which a transient central retinal artery occlusion was induced, found that the retina can tolerate approximately 100 min of ischemia before irreversible damage occurs. Medical treatments such as topical dorzolamide, timolol, and brimonidine, and systemic agents such as acetazolamide, corticosteroids, and mannitol can be beneficial if not contraindicated, but are not a substitute for surgical intervention.¹⁴

A lateral canthotomy and inferior cantholysis is the treatment of choice for rapid decompression of the orbit.¹⁴ Successful decompression is accompanied by a decrease in intraocular pressure and improvement in visual function. A superior cantholysis or orbital septolysis can be completed if no improvement occurs after a brief period.⁵⁵ Insufficient inferior cantholysis should also be considered. If surgical decompression remains inadequate, emergency imaging should be obtained and further intervention under general anesthesia pursued.¹⁴ Additional orbital decompression can be achieved with careful blunt intraorbital dissection via an inferolateral anterior orbitotomy,⁶⁹ or removal of the orbital floor, medial or lateral walls.¹⁴

Trauma

There is no current consensus on the management of traumatic orbital apex disorders. Corticosteroid therapy, surgical decompression, the combination of corticosteroids and surgery, and observation have all been described as potential treatment modalities.^{3,36,70}

Corticosteroids

Corticosteroid use in the treatment of traumatic orbital apex disorders has been advocated since the early 1990s.⁷¹ The use of corticosteroids was reinforced by the results of the National Acute Spinal Cord Injury Study II (NASCIS II),⁷² a multicenter randomized double-blind study that evaluated patient response to intravenous methylprednisolone after acute spinal cord injury. Patients were administered a methylprednisolone bolus of 30 mg/kg followed by an infusion of 5.4 mg/kg/h for 23 h. Patients who received this high-dose methylprednisolone protocol within 8 h of injury showed a significant improvement in motor and sensory function at 6 months⁷² and improved motor function after 1 year⁷³ compared to those who received placebo. High-dose corticosteroid therapy has been suggested to improve microvascular circulation in injured neural tissue and inhibit lipid peroxidation, thereby reducing neural cell damage.^{36,74}

Evidence supporting corticosteroid administration in the treatment of traumatic orbital apex disorders has come from multiple small retrospective case series, often lacking uniformity in corticosteroid dose or implementation of controls.^{2,3,71,75} Acartürk et al.,⁷⁰ in a recent retrospective case series of 11 patients, evaluated the efficacy of corticosteroid treatment in SOFS and OAS. Patients were treated with a similar high-dose methylprednisolone protocol to that employed in the NASCIS II trial. Each patient showed clinical improvement within 48 h, with complete resolution of symptoms by 6 months.⁷⁰

Other evidence suggests that corticosteroid administration may have little effect on post-traumatic visual acuity. The International Optic Nerve Trauma Study (IONTS)⁷⁶ was a prospective non-randomized interventional study that evaluated the effects of observation, corticosteroids, or surgery on visual acuity in 133 patients with indirect traumatic optic neuropathy. Patients were initially examined within 3 days of injury and treatment was initiated within 7 days of injury. Eighty-five of the enrolled patients received intravenous methylprednisolone

or equivalent in dosages ranging from less than 100 mg per day to greater than 5400 mg per day. The authors found no significant improvement in visual acuity in subjects treated with corticosteroids at any dose compared to untreated patients.⁷⁶

These results were further supported in a subsequent randomized, double-blind placebo-controlled trial involving 31 patients that evaluated the benefit of corticosteroids in the treatment of traumatic optic neuropathy.⁷⁷ Patients with a traumatic injury less than 7 days old were started on 250 mg intravenous methylprednisolone every 6 h for 3 days, followed by 1 mg/kg prednisone for 14 days. No significant improvement in visual acuity was found in patients treated with corticosteroids compared to placebo at the 3-month follow-up.⁷⁷

High-dose corticosteroids have also been associated with negative outcomes.^{74,78} Patients enrolled in NASCIS II treated with high-dose corticosteroids had significantly worse motor and sensory outcomes compared to placebo when treatment was started at more than 8 h after injury.⁷⁹ The Medical Research Council Corticosteroid Randomization After Significant Head Injury (MRC CRASH) study was a prospective, randomized, double-blind, placebo-controlled trial investigating the effect of high-dose corticosteroids after head injury.⁸⁰ Subjects suffering from traumatic head injury with a Glasgow Coma Scale score of 14 or less were assigned to a 48-h methylprednisolone protocol or placebo within 8 h of the initial trauma. The methylprednisolone protocol consisted of a 2-g infusion over 1 h, followed by a 0.4-g/h maintenance infusion for 48 h. The study was stopped after enrolling 10,008 subjects due to increased mortality in subjects treated with high-dose corticosteroids.⁸⁰

Animal studies have also cast doubt on the benefits of corticosteroid treatment. Ohlsson et al.⁸¹ reported no difference in visual evoked potentials, retinal cell survival, or axonal degeneration or regeneration after optic nerve crush injury in rats treated with high-dose methylprednisolone compared to controls. Huang et al.⁸² found that neither intraocular triamcinolone nor systemic methylprednisolone provided any additional benefit compared to placebo in the preservation of retinal ganglion cells after optic nerve crush injury in a rat model. Steinsapir et al.⁸³ reported a dose-dependent increase in optic nerve axonal loss with the administration of intravenous methylprednisolone when compared to intravenous saline in rats after optic nerve crush injury.

Based on the existing evidence, high-dose corticosteroids have not been shown to provide a proven benefit in the treatment of traumatic orbital apex disorders. The decision to administer corticosteroids should be based on the circumstances of the individual patient after an appropriate discussion of the risks and benefits. Providers should exercise caution when considering high-dose corticosteroids in patients with a traumatic head injury.

Surgical decompression

Surgical decompression of the optic canal or superior orbital fissure has been proposed in cases of bony impingement, optic nerve sheath hematoma, or to relieve optic nerve swelling.^{3,10,78} Surgical techniques to access the orbital apex include a transmaxillary approach,⁸⁴ orbitozygomatic approach, transthemoidal approach,³ and transcranial pterional approach.⁸⁵ The reduction of surrounding maxillofacial fractures has also been suggested by some authors to provide additional benefit.^{2,75}

Evidence supporting surgical decompression is limited to primarily small, retrospective case series. Wohlrab et al.⁸⁶ reported improvement in visual acuity in eight of 19 patients (42%) with traumatic optic neuropathy who underwent surgical decompression of the optic canal. Fujitani et al.⁸⁷ reported visual improvement in 34 of 70 eyes (47.7%) that underwent transthemoidal surgical decompression. Chen et al.¹⁰ reported a similar level of recovery of cranial nerve III, IV, and VI function in six patients with SOFS after surgical decompression when compared to 27 patients who did not undergo decompression, despite worse initial cranial nerve function in the surgical group.

Corticosteroids and surgery

There is no strong evidence to suggest that a combined approach involving corticosteroids and surgical decompression has greater efficacy when compared to other treatment modalities. Li et al.,⁸⁸ in a non-randomized study of 237 patients with traumatic optic neuropathy, found no significant difference between those patients treated with corticosteroids and endoscopic optic nerve decompression and those treated with corticosteroids alone. Yang et al.,⁸⁹ in a retrospective case series of 96 patients who underwent endoscopic optic nerve decompression, found no additional benefit from corticosteroid administration. Similarly, Ropposch et al.,⁹⁰ in a study of 42 patients treated with endoscopic optic

nerve decompression, found that corticosteroids offer no significant improvement in visual acuity. Thirty-two of 33 patients in the IONTS who underwent surgery also received corticosteroids, with no significant benefit when compared to observation alone.⁷⁶

Observation

Complicating any evaluation of the efficacy of available medical and surgical treatments is the relatively high rate of spontaneous improvement in visual acuity and cranial nerve function seen in patients with traumatic orbital apex disorders. Chen et al.³ reviewed 19 previously described case reports of SOFS and found that eight (42%) had complete resolution of symptoms with no intervention other than reduction of concomitant facial fractures. The literature on traumatic optic neuropathy reports spontaneous improvement in 0–57% of patients.^{12,33,76} This wide distribution is in part a result of differences in the timing of the initial clinical evaluation across case series.^{33,36}

Vascular disorders

The treatment of choice for direct carotid-cavernous fistulas is endovascular embolization.¹¹ Transarterial or transvenous approaches may be employed using metal coils, detachable balloons, or liquid adhesives.^{11,91} Covered stent grafts have also been described.⁹² More than 80% of patients treated with endovascular embolization experience complete resolution of symptoms.¹¹ Surgical intervention may be considered if endovascular embolization has failed or is otherwise not feasible. Techniques described include clipping or suturing of the fistula, packing of the cavernous sinus, or ligation of the internal carotid artery with an intracranial bypass.^{11,93}

Indirect carotid-cavernous fistulas can often be managed conservatively, as 20–60% will resolve spontaneously.¹¹ Regular follow-up is requisite to monitor for changes in visual acuity, fundoscopic examination, or a significant increase in intraocular pressure.⁹⁴ Patients with significant ocular pain, headache, progressive vision loss, or elevated intraocular pressure not responsive to medical therapy may require endovascular embolization.^{11,94} Transvenous approaches are often necessary secondary to the complex vascular anatomy associated with indirect carotid-cavernous fistulas.⁹¹ Stereotactic radiotherapy can result in occlusion of a carotid-cavernous fistula over the course

of several months.¹¹ As with direct carotid–cavernous fistulas, surgical intervention can be beneficial when other modalities are not available or are unsuccessful.

The management of septic and aseptic cavernous sinus thrombosis includes early anticoagulation and management of any concurrent seizure activity or increased intracranial pressure.⁹⁵ Endovascular thrombolysis has been described, but supporting evidence is currently limited to small retrospective studies.⁹⁶ Septic cavernous sinus thrombosis should be treated with aggressive broad-spectrum intravenous antibiotic therapy. Surgery is indicated to control the primary source of infection.²⁸

Many asymptomatic, small cavernous carotid aneurysms can be managed conservatively with regular monitoring.⁹⁷ Patients presenting with significant orbital apex symptoms, severe orbital pain, or with a large aneurysm at risk of rupture are candidates for endovascular or surgical intervention.⁹⁸ Endovascular coil embolization with intracranial stent placement can be utilized in aneurysms without significant mass effect.⁹⁸ In patients with large aneurysms with cavernous sinus, optic nerve, or superior orbital fissure compression, internal carotid artery occlusion with or without intracranial bypass can be considered.⁹⁸ A surgical intervention such as aneurysm clipping can be utilized if less invasive methods have failed or are otherwise contraindicated.

Orbital apex disorders are a diverse group of conditions not commonly seen in the daily practice of a maxillofacial surgeon. Failure to adequately diagnose and treat these conditions can result in permanent disability to the patient. The management of orbital apex disorders often requires a multidisciplinary approach with involvement from ophthalmology, otolaryngology, or neurosurgery. It is critical for a maxillofacial surgeon to be knowledgeable in the presentation and management of these disorders to ensure timely recognition and treatment and provide the best possible patient outcome.

Funding

None.

Competing interests

None.

Ethical approval

This manuscript was reviewed by the University of North Carolina at Chapel Hill Office of Human Research Ethics

and was found not to require IRB approval (Study Number 14-0191).

Patient consent

Not required.

References

1. Yeh S, Foroozan R. Orbital apex syndrome. *Curr Opin Ophthalmol* 2004;**15**:490–8.
2. Bun RJ, Vissink A, Bos RR. Traumatic superior orbital fissure syndrome: report of two cases. *J Oral Maxillofac Surg* 1996;**54**:758–61.
3. Chen CT, Chen YR. Traumatic superior orbital fissure syndrome: current management. *Craniofacial Trauma Reconstr* 2010;**3**:9–16.
4. Gronski HW, Creely Jr JJ. Carotid-cavernous fistula: a complication of maxillofacial trauma. *South Med J* 1975;**68**:1096–102.
5. Bone I, Hadley DM. Syndromes of the orbital fissure, cavernous sinus, cerebello-pontine angle, and skull base. *J Neurol Neurosurg Psychiatry* 2005;**76**(Suppl. 3):iii29–38.
6. Lenzi GL, Fieschi C. Superior orbital fissure syndrome. Review of 130 cases. *Eur Neurol* 1977;**16**:23–30.
7. Dalley RW, Robertson WD, Rootman J. Globe tenting: a sign of increased orbital tension. *AJNR Am J Neuroradiol* 1989;**10**:181–6.
8. Campiglio GL, Signorini M, Candiani P. Superior orbital fissure syndrome complicating zygomatic fractures. Pathogenesis and report of a case. Case report. *Scand J Plast Reconstr Surg Hand Surg* 1995;**29**:69–72.
9. Linnau KF, Hallam DK, Lomoschitz FM, Mann FA. Orbital apex injury: trauma at the junction between the face and the cranium. *Eur J Radiol* 2003;**48**:5–16.
10. Chen CT, Wang TY, Tsay PK, Huang F, Lai JP, Chen YR. Traumatic superior orbital fissure syndrome: assessment of cranial nerve recovery in 33 cases. *Plast Reconstr Surg* 2010;**126**:205–12. <http://dx.doi.org/10.1097/PRS.0b013e3181dab658>.
11. Ellis JA, Goldstein H, Connolly Jr ES, Meyers PM. Carotid-cavernous fistulas. *Neurosurg Focus* 2012;**32**:E9. <http://dx.doi.org/10.3171/2012.2.FOCUS1223>.
12. Chou PI, Sadun AA, Chen YC, Su WY, Lin SZ, Lee CC. Clinical experiences in the management of traumatic optic neuropathy. *Neuro-Ophthalmology* 1996;**16**:325–36.
13. Steinsapir KD, Goldberg RA. Traumatic optic neuropathy. *Surv Ophthalmol* 1994;**38**:487–518.
14. Lima V, Burt B, Leibovitch I, Prabhakaran V, Goldberg RA, Selva D. Orbital compartment syndrome: the ophthalmic surgical emergency. *Surv Ophthalmol* 2009;**54**:441–9. <http://dx.doi.org/10.1016/j.survophthal.2009.04.005>.
15. Gordon LK. Orbital inflammatory disease: a diagnostic and therapeutic challenge. *Eye (Lond)* 2006;**20**:1196–206.
16. La Mantia L, Curone M, Rapoport AM, Bussone G, International Headache Society. Tolosa-Hunt syndrome: critical literature review based on IHS 2004 criteria. *Cephalalgia* 2006;**26**:772–81.
17. Jacobson DM. Dysthyroid orbitopathy. *Semin Neurol* 2000;**20**:43–54.
18. Bhatti MT, Dutton JJ. Thyroid eye disease: therapy in the active phase. *J Neuroophthalmol* 2014;**34**:186–97. <http://dx.doi.org/10.1097/WNO.0000000000000128>.
19. Robinson D, Wilcsek G, Sacks R. Orbit and orbital apex. *Otolaryngol Clin North Am* 2011;**44**:903–22. <http://dx.doi.org/10.1016/j.otc.2011.06.011>. viii.
20. Walsh RD, Vagefi MR, McClelland CM, Alonso-Basanta M, Newman JG, Farkas T, et al. Primary adenoid cystic carcinoma of the orbital apex. *Ophthalm Plast Reconstr Surg* 2013;**29**:e33–5. <http://dx.doi.org/10.1097/IOP.0b013e31826463be>.
21. Alonso PE, Bescansa E, Salas J, de Haro J, Redondo A, Rioja LF. Perineural spread of cutaneous squamous cell carcinoma manifesting as ptosis and ophthalmoplegia (orbital apex syndrome). *Br J Plast Surg* 1995;**48**:564–8.
22. Gore HL, Corin SM, Klusmann KG, Doshi HM. Mucoepidermoid carcinoma presenting as an orbital apex syndrome. *Ophthalmic Surg* 1992;**23**:59–61.
23. Shindler KS, Liu GT, Womer RB. Long-term follow-up and prognosis of orbital apex syndrome resulting from nasopharyngeal rhabdomyosarcoma. *Am J Ophthalmol* 2005;**140**:236–41.
24. Woolf DK, Ahmed M, Plowman PN. Primary lymphoma of the ocular adnexa (orbital lymphoma) and primary intraocular lymphoma. *Clin Oncol (R Coll Radiol)* 2012;**24**:339–44. <http://dx.doi.org/10.1016/j.clon.2012.03.001>.
25. Chandler JR, Langenbrunner DJ, Stevens ER. The pathogenesis of orbital complications in acute sinusitis. *Laryngoscope* 1970;**80**:1414–28.
26. Jackson K, Baker SR. Periorbital cellulitis. *Head Neck Surg* 1987;**9**:227–34.
27. Baring DE, Hilmi OJ. An evidence based review of periorbital cellulitis. *Clin Otolaryngol* 2011;**36**:57–64. <http://dx.doi.org/10.1111/j.1749-4486.2011.02258.x>.
28. Ebright JR, Pace MT, Niazi AF. Septic thrombosis of the cavernous sinuses. *Arch Intern Med* 2001;**161**:2671–6.
29. Mills RP, Kartush JM. Orbital wall thickness and the spread of infection from the paranasal sinuses. *Clin Otolaryngol Allied Sci* 1985;**10**:209–16.
30. Brook I. Microbiology and antimicrobial treatment of orbital and intracranial complications of sinusitis in children and their management. *Int J Pediatr Otorhinolaryngol* 2009;**73**:1183–6. <http://dx.doi.org/10.1016/j.ijporl.2009.01.020>.

31. Thurtell MJ, Chiu AL, Goold LA, Akdal G, Crompton JL, Ahmed R, et al. Neuro-ophthalmology of invasive fungal sinusitis: 14 consecutive patients and a review of the literature. *Clin Experiment Ophthalmol* 2013;**41**:567–76. <http://dx.doi.org/10.1111/ceo.12055>.
32. Zachariades N, Vairaktaris E, Papavassiliou D, Papademetriou I, Mezitis M, Triantafyllou D. The superior orbital fissure syndrome. *J Maxillofac Surg* 1985;**13**:125–8.
33. Steinsapir KD, Goldberg RA. Traumatic optic neuropathy: a critical update. *Comp Ophthalmol Update* 2005;**6**:11–2.
34. Anderson RL, Panje WR, Gross CE. Optic nerve blindness following blunt forehead trauma. *Ophthalmology* 1982;**89**:445–55.
35. Gross CE, DeKock JR, Panje WR, Hershkowitz N, Newman J. Evidence for orbital deformation that may contribute to monocular blindness following minor frontal head trauma. *J Neurosurg* 1981;**55**:963–6.
36. Warner N, Eggenberger E. Traumatic optic neuropathy: a review of the current literature. *Curr Opin Ophthalmol* 2010;**21**:459–62. <http://dx.doi.org/10.1097/ICU.0b013e32833f00c9>.
37. Gerbino G, Ramieri GA, Nasi A. Diagnosis and treatment of retrobulbar haematomas following blunt orbital trauma: a description of eight cases. *Int J Oral Maxillofac Surg* 2005;**34**:127–31.
38. Fattahi T, Brewer K, Retana A, Ogledzki M. Incidence of retrobulbar hemorrhage in the emergency department. *J Oral Maxillofac Surg* 2014;**72**:2500–2. <http://dx.doi.org/10.1016/j.joms.2014.06.457>.
39. Key SJ, Ryba F, Holmes S, Manisali M. Orbital emphysema – the need for surgical intervention. *J Craniomaxillofac Surg* 2008;**36**:473–6. <http://dx.doi.org/10.1016/j.jcms.2008.04.004>.
40. van Issum C, Courvoisier DS, Scolozzi P. Posttraumatic orbital emphysema: incidence, topographic classification and possible pathophysiologic mechanisms. A retrospective study of 137 patients. *Oral Surg Oral Med Oral Pathol Oral Radiol* 2013;**115**:737–42. <http://dx.doi.org/10.1016/j.oooo.2012.10.021>.
41. Fleishman JA, Beck RW, Hoffman RO. Orbital emphysema as an ophthalmologic emergency. *Ophthalmology* 1984;**91**:1389–91.
42. Buckley MJ, Turvey TA, Schumann SP, Grimson BS. Orbital emphysema causing vision loss after a dental extraction. *J Am Dent Assoc* 1990;**120**:421–2. 424.
43. Giroto JA, Davidson J, Wheatly M, Redett R, Muehlberger T, Robertson B, et al. Blindness as a complication of Le Fort osteotomies: role of atypical fracture patterns and distortion of the optic canal. *Plast Reconstr Surg* 1998;**102**:1409–21. [discussion 1422–3].
44. Barrow DL, Spector RH, Braun IF, Landman JA, Tindall SC, Tindall GT. Classification and treatment of spontaneous carotid-cavernous sinus fistulas. *J Neurosurg* 1985;**62**:248–56.
45. Helmke K, Krüger O, Laas R. The direct carotid cavernous fistula: a clinical, pathoanatomical, and physical study. *Acta Neurochir (Wien)* 1994;**127**:1–5.
46. Gemmete JJ, Chaudhary N, Pandey A, Ansari S. Treatment of carotid cavernous fistulas. *Curr Treat Options Neurol* 2010;**12**:43–53. <http://dx.doi.org/10.1007/s11940-009-0051-3>.
47. Chang CM, Cheng CS. Late intracranial haemorrhage and subsequent carotid-cavernous sinus fistula after fracture of the facial bones. *Br J Oral Maxillofac Surg* 2013;**51**:e296–8. <http://dx.doi.org/10.1016/j.bjoms.2013.07.009>.
48. Melamed E, Rachmilewitz EA, Reches A, Lavy S. Aseptic cavernous sinus thrombosis after internal carotid arterial occlusion in polycythaemia vera. *J Neurol Neurosurg Psychiatry* 1976;**39**:320–4.
49. Ameri A, Bousser MG. Cerebral venous thrombosis. *Neurol Clin* 1992;**10**:87–111.
50. Lai PF, Cusimano MD. The spectrum of cavernous sinus and orbital venous thrombosis: a case and a review. *Skull Base Surg* 1996;**6**:53–9.
51. Ghali MG, Ghali EZ. Intracavernous internal carotid artery mycotic aneurysms: comprehensive review and evaluation of the role of endovascular treatment. *Clin Neurol Neurosurg* 2013;**115**:1927–42. <http://dx.doi.org/10.1016/j.clineuro.2013.07.025>.
52. Stiebel-Kalish H, Kalish Y, Bar-On RH, Setton A, Niimi Y, Berenstein A, et al. Presentation, natural history, and management of carotid cavernous aneurysms. *Neurosurgery* 2005;**57**:850–7.
53. Linskey ME, Sekhar LN, Hirsch Jr W, Yonas H, Horton JA. Aneurysms of the intracavernous carotid artery: clinical presentation, radiographic features, and pathogenesis. *Neurosurgery* 1990;**26**:71–9.
54. Zoumalan CI, Bullock JD, Warwar RE, Fuller B, McCulley TJ. Evaluation of intraocular and orbital pressure in the management of orbital hemorrhage: an experimental model. *Arch Ophthalmol* 2008;**126**:1257–60. <http://dx.doi.org/10.1001/archophth.126.9.1257>.
55. Oester Jr AE, Fowler BT, Fleming JC. Inferior orbital septum release compared with lateral canthotomy and cantholysis in the management of orbital compartment syndrome. *Ophthalm Plast Reconstr Surg* 2012;**28**:40–3. <http://dx.doi.org/10.1097/IOP.0b013e31823646f3>.
56. Murgatroyd HM, Bembridge J. Intraocular pressure. *Contin Educ Anaesth Crit Care Pain* 2008;**8**:100–3. <http://dx.doi.org/10.1093/bjaceaccp/mkn015>.
57. Pillunat LE, Anderson DR, Knighton RW, Joos KM, Feuer WJ. Autoregulation of human optic nerve head circulation in response to increased intraocular pressure. *Exp Eye Res* 1997;**64**:737–44.
58. Grunwald JE, Riva CE, Kozart DM. Retinal circulation during a spontaneous rise of intraocular pressure. *Br J Ophthalmol* 1988;**72**:754–8.
59. Perry M, Moutray T. Advanced Trauma Life Support (ATLS) and facial trauma: can one size fit all? Part 4: ‘can the patient see?’ Timely diagnosis, dilemmas and pitfalls in the multiply injured, poorly responsive/unresponsive patient. *Int J Oral Maxillofac Surg* 2008;**37**:505–14. <http://dx.doi.org/10.1016/j.ijom.2007.11.004>.
60. McInnes G, Howes DW. Lateral canthotomy and cantholysis: a simple, vision-saving procedure. *CJEM* 2002;**4**:49–52.
61. Tarabishy AB, Schulte M, Papaliadis GN, Hoffman GS. Wegener’s granulomatosis: clinical manifestations, differential diagnosis, and management of ocular and systemic disease. *Surv Ophthalmol* 2010;**55**:429–44. <http://dx.doi.org/10.1016/j.survophthal.2009.12.003>.
62. Yen MT, Yen KG. Effect of corticosteroids in the acute management of pediatric orbital cellulitis with subperiosteal abscess. *Ophthalm Plast Reconstr Surg* 2005;**21**:363–6. [discussion: 366–7].
63. Pushker N, Tejwani LK, Bajaj MS, Khurana S, Velpandian T, Chandra M. Role of oral corticosteroids in orbital cellulitis. *Am J Ophthalmol* 2013;**156**. <http://dx.doi.org/10.1016/j.ajo.2013.01.031>. 178–83.e1.
64. Garcia GH, Harris GJ. Criteria for nonsurgical management of subperiosteal abscess of the orbit: analysis of outcomes 1988–1998. *Ophthalmology* 2000;**107**:1454–6. [discussion 1457–8].
65. Tanna N, Preciado DA, Clary MS, Choi SS. Surgical treatment of subperiosteal orbital abscess. *Arch Otolaryngol Head Neck Surg* 2008;**134**:764–7. <http://dx.doi.org/10.1001/archotol.134.7.764>.
66. Noordzij JP, Harrison SE, Mason JC, Hashisaki GT, Reibel JF, Gross CW. Pitfalls in the endoscopic drainage of subperiosteal orbital abscesses secondary to sinusitis. *Am J Rhinol* 2002;**16**:97–101.
67. Hayreh SS, Kolder HE, Weingeist TA. Central retinal artery occlusion and retinal tolerance time. *Ophthalmology* 1980;**87**:75–8.
68. Hayreh SS, Zimmerman MB, Kimura A, Sanon A. Central retinal artery occlusion. Retinal survival time. *Exp Eye Res* 2004;**78**:723–36.
69. Burkat CN, Lenke BN. Retrobulbar hemorrhage: inferolateral anterior orbitotomy for emergent management. *Arch Ophthalmol* 2005;**123**:1260–2.
70. Acartürk S, Seküçoğlu T, Kesiktäs E. Mega dose corticosteroid treatment for traumatic superior orbital fissure and orbital apex syndromes. *Ann Plast Surg* 2004;**53**:60–4.
71. Postma MP, Seldomridge GW, Vines FS. Superior orbital fissure syndrome and bilateral internal carotid pseudoaneurysms. *J Oral Maxillofac Surg* 1990;**48**:503–8.

72. Bracken MB, Shepard MJ, Collins WF, Holford TR, Young W, Baskin DS, et al. A randomized, controlled trial of methylprednisolone or naloxone in the treatment of acute spinal-cord injury. Results of the Second National Acute Spinal Cord Injury Study. *N Engl J Med* 1990;**322**:1405–11.
73. Bracken MB, Shepard MJ, Collins Jr WF, Holford TR, Baskin DS, Eisenberg HM, et al. Methylprednisolone or naloxone treatment after acute spinal cord injury: 1-year follow-up data. Results of the second National Acute Spinal Cord Injury Study. *J Neurosurg* 1992;**76**:23–31.
74. Steinsapir KD. Treatment of traumatic optic neuropathy with high-dose corticosteroid. *J Neuroophthalmol* 2006;**26**:65–7.
75. Rohrich RJ, Hackney FL, Parikh RS. Superior orbital fissure syndrome: current management concepts. *J Craniomaxillofac Trauma* 1995;**1**:44–8.
76. Levin LA, Beck RW, Joseph MP, Seiff S, Kraker R. The treatment of traumatic optic neuropathy: the International Optic Nerve Trauma Study. *Ophthalmology* 1999;**106**:1268–77.
77. Entezari M, Rajavi Z, Sedighi N, Daftarian N, Sanagoo M. High-dose intravenous methylprednisolone in recent traumatic optic neuropathy, Sep, a randomized double-masked placebo-controlled clinical trial. *Graefes Arch Clin Exp Ophthalmol* 2007;**245**:1267–71.
78. Steinsapir KD, Goldberg RA. Traumatic optic neuropathy: an evolving understanding. *Am J Ophthalmol* 2011;**151**. <http://dx.doi.org/10.1016/j.ajo.2011.02.007>. 928–33.e2.
79. Bracken MB, Holford TR. Effects of timing of methylprednisolone or naloxone administration on recovery of segmental and long-tract neurological function in NASCIS 2. *J Neurosurg* 1993;**79**:500–7.
80. Roberts I, Yates D, Sandercock P, Farrell B, Wasserberg J, Lomas G, et al. Effect of intravenous corticosteroids on death within 14 days in 10 008 adults with clinically significant head injury (MRC CRASH trial): randomised placebo-controlled trial. *Lancet* 2004;**364**:1321–8.
81. Ohlsson M, Westerlund U, Langmoen IA, Svensson M. Methylprednisolone treatment does not influence axonal regeneration or degeneration following optic nerve injury in the adult rat. *J Neuroophthalmol* 2004;**24**:11–8.
82. Huang TL, Chang CH, Lin KH, Sheu MM, Tsai RK. Lack of protective effect of local administration of triamcinolone or systemic treatment with methylprednisolone against damages caused by optic nerve crush in rats. *Exp Eye Res* 2011;**92**:112–9. <http://dx.doi.org/10.1016/j.exer.2010.12.008>.
83. Steinsapir KD, Goldberg RA, Sinha S, Hovda DA. Methylprednisolone exacerbates axonal loss following optic nerve trauma in rats. *Restor Neurol Neurosci* 2000;**17**:157–63.
84. Wang X, Li YM, Huang CG, Liu HC, Li QC, Yu MK, et al. Endoscopic transmaxillary transMüller's muscle approach for decompression of superior orbital fissure: a cadaveric study with illustrative case. *J Craniomaxillofac Surg* 2014;**42**:132–40. <http://dx.doi.org/10.1016/j.jcms.2013.03.008>.
85. Ammirati M, Bernardo A. Anatomical study of the superior orbital fissure as seen during a pterional approach. *J Neurosurg* 2007;**106**:151–6.
86. Wohlrab TM, Maas S, de Carpentier JP. Surgical decompression in traumatic optic neuropathy. *Acta Ophthalmol Scand* 2002;**80**:287–93.
87. Fujitani T, Inoue K, Takahashi T, Ikushima K, Asai T. Indirect traumatic optic neuropathy—visual outcome of operative and nonoperative cases. *Jpn J Ophthalmol* 1986;**30**:125–34.
88. Li H, Zhou B, Shi J, Cheng L, Wen W, Xu G. Treatment of traumatic optic neuropathy: our experience of endoscopic optic nerve decompression. *J Laryngol Otol* 2008;**122**:1325–9. <http://dx.doi.org/10.1017/S0022215108002296>.
89. Yang QT, Zhang GH, Liu X, Ye J, Li Y. The therapeutic efficacy of endoscopic optic nerve decompression and its effects on the prognoses of 96 cases of traumatic optic neuropathy. *J Trauma Acute Care Surg* 2012;**72**:1350–5. <http://dx.doi.org/10.1097/TA.0b013e3182493c70>.
90. Ropposch T, Steger B, Meço C, Emesz M, Reitsamer H, Rasp G, et al. The effect of steroids in combination with optic nerve decompression surgery in traumatic optic neuropathy. *Laryngoscope* 2013;**123**:1082–6. <http://dx.doi.org/10.1002/lary.23845>.
91. Ringer AJ, Salud L, Tomsick TA. Carotid cavernous fistulas: anatomy, classification, and treatment. *Neurosurg Clin N Am* 2005;**16**:279–95. viii.
92. Tiewei Q, Ali A, Shaolei G, Feng L, Zhong-song S, Xuesong L, et al. Carotid cavernous fistulas treated by endovascular covered stent grafts with follow-up results. *Br J Neurosurg* 2010;**24**:435–40. <http://dx.doi.org/10.3109/02688697.2010.487127>.
93. Tu YK, Liu HM, Hu SC. Direct surgery of carotid cavernous fistulae and dural arteriovenous malformations of the cavernous sinus. *Neurosurgery* 1997;**41**:798–805. [discussion 805–6].
94. Miller NR. Dural carotid–cavernous fistulas: epidemiology, clinical presentation, and management. *Neurosurg Clin N Am* 2012;**23**:179–92. <http://dx.doi.org/10.1016/j.nec.2011.09.008>.
95. Coutinho JM, Stam J. How to treat cerebral venous and sinus thrombosis. *J Thromb Haemost* 2010;**8**:877–83. <http://dx.doi.org/10.1111/j.1538-7836.2010.03799.x>.
96. Coutinho JM, Ferro JM, Zuurbier SM, Mink MS, Canhão P, Crassard I, et al. Thrombolysis or anticoagulation for cerebral venous thrombosis: rationale and design of the TO-ACT trial. *Int J Stroke* 2013;**8**:135–40. <http://dx.doi.org/10.1111/j.1747-4949.2011.00753.x>.
97. Kupersmith MJ, Hurst R, Berenstein A, Choi IS, Jafar J, Ransohoff J. The benign course of cavernous carotid artery aneurysms. *J Neurosurg* 1992;**77**:690–3.
98. Eddleman CS, Hurley MC, Bendok BR, Batjer HH. Cavernous carotid aneurysms: to treat or not to treat? *Neurosurg Focus* 2009;**26**:E4. <http://dx.doi.org/10.3171/2009.2.FOCUS0920>.

Address:
 Timothy Turvey
 Department of Oral and Maxillofacial
 Surgery
 School of Dentistry
 University of North Carolina at Chapel Hill
 149 Brauer Hall
 CB #7450
 Chapel Hill
 NC 27599-7450
 USA
 Tel: +1 919 537 3702; Fax: +1 919 537 3407
 E-mail: tim_turvey@unc.edu