

# Irreversible Unilateral Visual Loss due to Acute Sinusitis

Antoine E. Tarazi, MD, Alan H. Shikani, MD

• **Extension of sphenothmoiditis into the orbital apex may result in visual loss and ophthalmoplegia, but minimal signs of orbital pathology such as proptosis, chemosis, or lid edema. This entity is termed orbital apex syndrome. The case of a 74-year-old woman with orbital apex syndrome and irreversible unilateral visual loss secondary to bacterial sphenothmoiditis is presented. This case, and our review of the literature, suggest that patients with symptomatic acute sphenothmoiditis are at a relatively higher risk of permanent visual loss than those with sinusitis not involving the posterior ethmoid and/or sphenoid sinuses.**

(*Arch Otolaryngol Head Neck Surg.* 1991;117:1400-1401)

Orbital involvement by sinusitis is a well-recognized entity that is generally due to direct extension of the infection. Visual dysfunction may coincide with or follow signs of orbital involvement such as proptosis, chemosis, and lid edema. Orbital apex syndrome (OAS) is a rare form of complication that classically presents with visual loss and ophthalmoplegia, but with minimal or no signs of orbital inflammation. The pathology starts in the sphenothmoid region and extends into the orbital apex with subsequent blindness. We present a case of acute sphenothmoiditis that was complicated by monocular and irreversible visual loss in an elderly diabetic patient. Extensive investigation ruled out fungal or neoplastic disease.

## REPORT OF A CASE

A 74-year-old woman presented to the emergency department because of acute loss of vision on the right side associated with right-sided periorbital pain of 24 hours' duration. Her history was significant for controlled insulin-dependent diabetes mellitus for the past 6 years and right-sided headache of several months' duration. She denied nasal discharge, fever, postnasal drip, or nasal congestion. Physical examination revealed a temperature of 36.5°C and stable vital signs. Ophthalmologic evaluation revealed minimal proptosis of the right eyelid with moderate ophthalmoplegia and no light perception. A right-sided afferent pupillary defect was noted; the anterior chamber, conjunctiva, and cornea were all normal. Funduscopy examination revealed mild disk pallor without atrophy, and a background of mild diabetic retinopathy that could not explain the visual loss. Examination of the nose with the Storz telescope revealed a mass in the middle meatus that was clinically suspected to be a tumor. No black or necrotic ulcers could be seen in the nose or palate. The rest of her general and neurologic examination was normal.

Computed tomography and magnetic resonance imaging of the orbits revealed a mass involving the right sphenoid, ethmoid, and maxillary air cells with some degree of bony erosion in the posterior portion of the laminae papyracea and extension into the orbital apex (Fig 1). This mass had a high signal intensity on T2 imaging and was suspected to be an inflammatory process (Fig 2). Laboratory work-up included a normal white blood cell count, with a blood glucose level of 12.5 mmol/L. The patient was given 1 g of cefazolin intravenously every 8 hours. A biopsy procedure of the intranasal mass revealed acute and chronic inflammatory changes. No tumor or fungus could be identified.

Because the ophthalmologist believed that

the visual loss was irreversible, a limited decompression with intranasal endoscopic sphenothmoidectomy was performed. Management also included aggressive control of the blood glucose and intravenous administration of cefazolin, which was continued for 2 weeks. The patient's vision did not recover postoperatively nor at the last follow-up, which was 2 months later. The intranasal endoscopic examination, on the other hand, showed resolution of the paranasal pathologic condition.

## COMMENT

Orbital apex syndrome, or isolated visual loss with minimal inflammatory orbital signs caused by adjacent posterior sphenothmoidal sinusitis, is extremely rare. It was originally described by Rochon-Du Vigneaud in 1896<sup>1</sup> and believed to be caused by syphilis. Trantas<sup>2</sup> in 1893 described a case of total ophthalmoplegia and "ocular complications" secondary to paranasal sinusitis. In 1945, Kjoer<sup>3</sup> reported on unilateral blindness, ophthalmoplegia but no proptosis, caused by sphenothmoidal sinusitis. Since then, only a handful of cases fulfilled the criteria of OAS. In the latest study in 1987, three cases of OAS were described by Slavin and Glaser,<sup>4</sup> who renamed the entity *posterior orbital cellulitis*. This syndrome is much less common than the orbital complications of anterior ethmoid sinusitis. Chandler et al<sup>5</sup> summarized the clinical spectrum of the latter; these range from inflammatory orbital edema to orbital cellulitis, orbital and subperiosteal abscesses, optic neuritis, and cavernous sinus thrombosis. Depending on the degree of involvement,

Accepted for publication April 23, 1991.

From the Department of Otolaryngology Head and Neck Surgery, The Johns Hopkins Medical Institutions, Baltimore, Md.

Reprints not available.

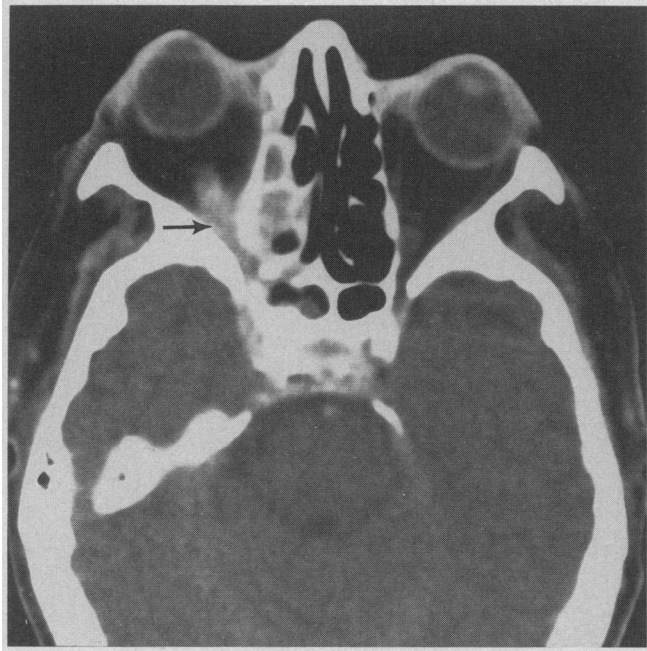


Fig 1.—Computed axial tomogram of the orbits demonstrating right-sided ethmoidal and sphenoidal sinusitis with extension into the orbital apex. There is some bony erosion in the posterior portion of the laminae papyraceae.

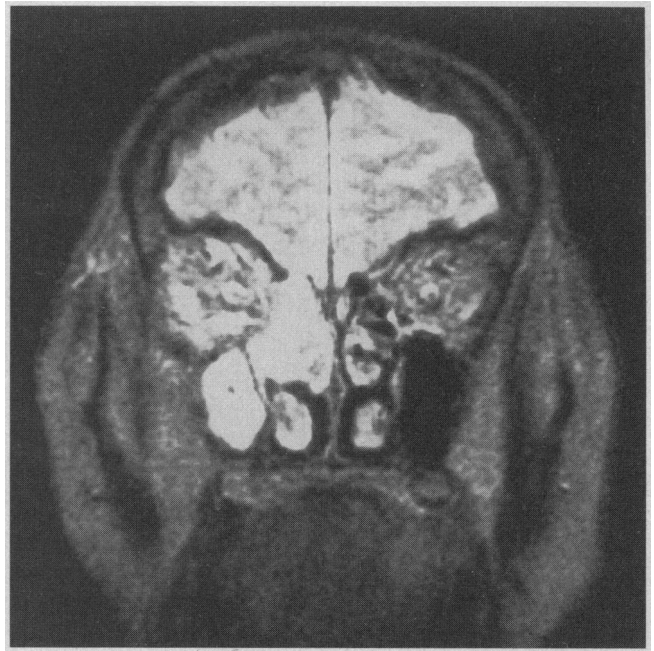

Fig 2.—Magnetic resonance imaging of the head showing right-sided maxillary and ethmoidal sinusitis. The high signal intensity on T2 imaging is suggestive of an inflammatory process.

the patient may present with proptosis, ophthalmoplegia, eyelid edema, chemosis, and possibly visual loss.

The incidence of permanent visual loss with documented orbital or subperiosteal abscesses is 15%.<sup>6-10</sup> The cause has been suggested to include vascular compromise, compression, or infiltration of the optic nerve. Septic vasculitis and increased intraorbital pressure have also been postulated as contributing factors.<sup>4</sup>

Why is the contiguous spread from posterior sphenothmoiditis much less frequent than from anterior ethmoiditis? Perhaps the answer lies in the peculiar anatomy of the interface between the periorbita and the paranasal sinuses. The periosteum of the orbit is loosely attached to the bone anteriorly and may be elevated by a purulent collection resulting in a subperiosteal abscess. In contrast, the periorbita is thicker and more firmly attached posteriorly, providing a barrier to the spread of infection.<sup>4</sup> In addition, the sphenoid bone is thicker and hence more difficult to penetrate than the very thin anterior lamina papyracea. Finally, the ethmoid foramina may serve as a conduit for a direct spread of infection from the sinuses into the orbit anteriorly.

The cause of visual loss in OAS is the same as in orbital cellulitis; however, the importance of compressive and inflammatory factors is magnified because the optic nerve is confined in the orbital apex and within a bony canal. The marked bowing of the posterior ethmoid air cells seen in some patients may further increase the compression of the nerve.<sup>4</sup> In the only autopsy of OAS reported in the literature, Kjoer<sup>3</sup> describes marked necrosis of the proximal segment of the optic nerve with severe thromboangiitis of its vasculature.

The treatment of OAS as recommended by Slavin and Glaser<sup>4</sup> is prompt use of intravenous antibiotics with early decompression and drainage of the sinuses. None of the reported cases had decompression of the optic nerve in the canal itself. In all the cases, the prognosis was very poor with no or very little improvement in vision. Whether a total decompression, including the optic canal in the posterior ethmoid and sphenoid areas is helpful, is not clear. Corticosteroids have been tried but found to be ineffective.<sup>1</sup>

Otolaryngologists should be aware that patients with acute sphenothmoiditis extending into the orbit are at a higher risk of permanent visual loss.

Although the prognosis is poor, aggressive surgical and medical intervention are warranted, since it is possible that some improvement of vision may occur and that the disease may spread to the fellow eye if left untreated. Complete work-up to rule out other treatable disease entities, such as neoplasms or granulomatous disorders, is a must.

## References

1. Kronschnabel EF. Orbital apex syndrome due to sinus infection. *Laryngoscope*. 1974;84:353-371.
2. Trantas A. Ophthalmoplegie totale et autres complications oculaires dans les polysinusites. *Arch Ophthalmologie*. 1893;13:357.
3. Kjoer I. A case of orbital apex syndrome in collateral pan-sinusitis. *Acta Ophthalmol*. 1945;23:357-366.
4. Slavin ML, Glaser JS. Acute severe irreversible visual loss with sphenothmoiditis: 'posterior' orbital cellulitis. *Arch Ophthalmol*. 1987;105:345-348.
5. Chandler JR, Langenbrunner DJ, Stevens ER. The pathogenesis of orbital complications in acute sinusitis. *Laryngoscope*. 1970;80:1414-1428.
6. Jarret WH, Gutman FA. Ocular complications of infection in the paranasal sinuses. *Arch Ophthalmol*. 1969;81:683-688.
7. Quick CA, Payne E. Complicated acute sinusitis. *Laryngoscope*. 1972;82:1248-1263.
8. Hornblase A, Herschorn BJ, Stern K, et al. Orbital abscess. *Surv Ophthalmol*. 1984;29:169-178.
9. Welsh LW, Welsh JJ. Orbital complications of sinus disease. *Laryngoscope*. 1974;84:848-856.
10. Morgan PR, Morrison WV. Complications of frontal and ethmoidal sinusitis. *Laryngoscope*. 1980;90:661-666.