

Genetics and Ocular Disorders: A Focused Review

Hannah L. Scanga, MS, CGC^{a,b}, Ken K. Nischal, MD, FRCOphth^{a,b,*}

KEYWORDS

• Eye disease • Genetics • Genetic testing • Pediatrics

KEY POINTS

- Increasingly accurate phenotyping leads to better genetic evaluation.
- Genetic eye conditions may be due to a common cellular defect (eg, ciliopathies or RASopathies).
- Early-onset retinal dystrophies may be associated with renal disease.
- An understanding of genetic testing helps clinicians identify shortcomings in testing which may lead to a better understanding of the most appropriate test for a given ocular condition.
- Dedicated genetic counselors within ophthalmic and pediatric clinics are likely to improve the delivery of clinical care in these settings.

INTRODUCTION

Genetic eye disease is a vast topic. So many areas of interest exist and so many enormous developments have occurred that providing a comprehensive discussion in a short review such as this is impossible. Therefore, this article concentrates on some new concepts in ophthalmic genetics, and also provides some strategies that may help pediatricians cope with all of the new information in the world of genomics. This article also helps identify patients who might benefit from genetic evaluation and provides some idea of how to interpret those genetic results.

The pediatrician and ophthalmologist often work as a team to determine a diagnosis to account for all physical and developmental anomalies that might present in a child. Whenever concern exists about a child's development, it is important for an ophthalmologist to conduct an evaluation to assess vision and possible related eye anomalies.

The newborn screening examination and the family ocular history provide critical information to pediatricians. Any anatomic anomaly seen by the pediatrician might indicate a genetic disease, which might impact not only the child's vision but also the

^a UPMC Eye Center, University of Pittsburgh, 200 Lothrop Street, Pittsburgh, PA 15213, USA;

^b Children's Eye Center, Children's Hospital of Pittsburgh of UPMC, 4401 Penn Avenue, Pittsburgh, PA 15224-1334, USA

* Corresponding author. Children's Hospital of Pittsburgh, CHL 03-05-01, 4401 Penn Avenue, Pittsburgh, PA 15224-1334.

E-mail address: nischalkk@upmc.edu

overall health of the child. For example, a lens opacity could represent galactosemia. Conversely, if a history exists of a genetic eye defect, the baby should have an immediate thorough evaluation. For example, a family might have a history of incontinentia pigmenti. This disease can variably affect the retinas of different people. A mother might have normal vision, but her child could inherit a form of the disease that will cause blindness if treatment is not obtained before the retinas detach. Therefore, the pediatrician can help prevent total loss of vision if a child with incontinentia pigmenti is referred immediately for retinal examination regardless of the parent's vision.

SELECTED CLINICALLY IMPORTANT OCULAR PHENOTYPE/GENOTYPE CORRELATIONS

This section presents either recent information that is important to know or older information that is still so important that it needs to be revisited.

Lids

Lymphedema-distichiasis syndrome

This syndrome is caused by mutations in FOXC2 and has significant variability of expression.¹ Distichiasis (the growth of extra eyelashes, ranging from a few extra eyelashes to a full extra set on both the upper and lower lids) is the most common clinical feature, followed by lymphedema, which typically has its onset at puberty and not at birth (Milroy disease). Therefore, any child with distichiasis should be genetically tested for this condition.

Cornea

Corneal lesion and trisomy 8 mosaicism

Corneal lesions present as a flat reticular-appearing white lesion usually extending from the limbus into the cornea; fine blood vessels are usually present and the lesion is not elevated (**Fig. 1**).² This lesion is most commonly seen in trisomy 8 mosaicism, and the affected child may seem normal, and therefore testing (see later discussion) should be considered.

Iris

Iris anomalies and ACTA2

Cysts from the iris pigment epithelium at the pupillary margin are also called *iris flocculi* (**Fig. 2**). If a patient has parents or siblings with the same condition or has a family history of cardiac problems or vascular dissection, then ACTA2 analysis should be considered.³ Congenital mydriasis with persistent pupillary membranes has also been found to be associated with ACTA2 mutations.⁴

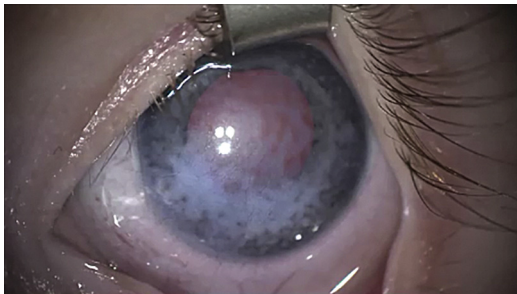

Fig. 1. This corneal lesion is unilateral; there is a flat reticular pattern with fine vessels. If seen, trisomy 8 mosaicism should be excluded.

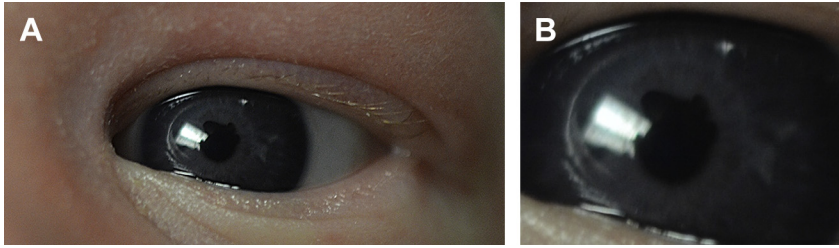


Fig. 2. This child has iris flocculi, which from a distance may appear like an irregular pupil (A), but close up the cysts of the iris pigment epithelium coming through the pupil are seen (B). A family history of these or of cardiovascular anomalies should prompt testing for ACTA2 mutations.

Lens

The relationship between intracerebral hemorrhages, in utero or perinatally, with congenital cataracts or lens anomalies has been found to be associated with mutations in the COL4A1 gene. This gene encodes the $\alpha 1$ chain of type IV collagen, which is a critical component of almost all basement membranes, including those of the vasculature, renal glomeruli, and ocular structures.⁵

Vitreous

Vitreous anomaly and stickler syndrome

Stickler syndrome is a collagenopathy caused by mutations in COL2A1 and COL11A1. Stickler syndrome consists of cleft palate, arthropathy, myopia, and retinal detachment. Ocular-only phenotype is seen in mutations in COL2A1. Some people argue that all patients with cleft palate should be screened for vitreous anomaly (Fig. 3).⁶

Retina

Leber congenital amaurosis

The number of gene mutations that are known to cause Leber congenital amaurosis (LCA) increases as the knowledge base increases, but the LCA genes encode proteins with a wide variety of retinal functions, such as phototransduction (AIPL1, GUCY2D), rod/cone morphogenesis (CRB1, CRX), vitamin A cycle regulation (LRAT, RDH12, RPE65), guanine synthesis (IMPDH1), outer segment phagocytosis (MERTK), and

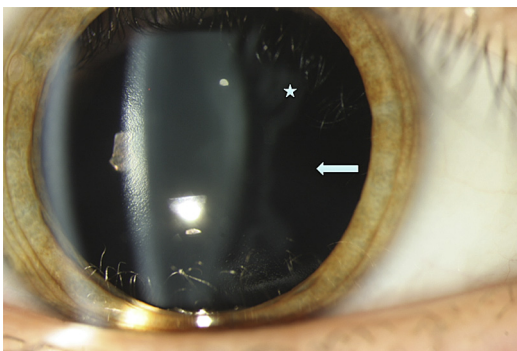


Fig. 3. This patient has genetically proven Stickler syndrome (COL2A1); this is a type 1 vitreous anomaly. Normally the area behind the membranous vitreous structure (*white star*) would reflect some light, but here it is optically empty (*white arrow*). (Courtesy of M. Snead, MD.)

intraphotoreceptor ciliary transport processes (ciliary genes: CEP290, LCA5, RPGRIP1, TULP1, discussed later).⁷

Phenotype-genotype correlation by one Hanein and colleagues⁸ suggested that patients could be divided into 2 main groups, one with photophobia and the other with nyctalopia.

Photophobia

In the group complaining of photophobia, hypermetropia was always noted and involvement was seen of both rods and cones, resulting in early peripheral and macular degeneration of the retina with bone spicule pigments in the periphery; retinal atrophy including the macular region; thin attenuated vessels; and optic disc pallor. When the hypermetropia was higher than +7 diopters, the visual acuity was reduced to counting fingers (CF) or light perception (LP). In these cases, the disease was not progressive and pathognomonic of GUCY2D mutations when the hypermetropia was lower than +7; the visual acuity was frequently recordable and ranged from CF to 20/400. This findings, together with the presence of a keratoconus, suggested mutations in the AIPL1 or RPGRIP1 genes.

Nyctalopia

In the group with night blindness (nyctalopia), 2 clinical subtypes exist, one with hypermetropia and the second without hypermetropia. In the former, an early macular disruption is almost always visible on funduscopy. Consequently, a central scotoma is noted at the visual field and the visual acuity ranges from 20/200 to 20/100 in the first decade of life. These clinical findings suggest mutations in either CRB1 or CRX. In the second subtype, an early peripheral pigmentary retinopathy is visible on funduscopy. The visual field shows a progressive concentric reduction. The visual acuity is much better than in other groups of patients, especially during daytime, reaching values ranging from 20/200 to 20/100 or better during the first decade. This milder form of LCA strongly suggests mutations in the RPE65 or TULP1 genes.

Optic Nerve

Most inherited optic neuropathies are caused by mutations in mitochondrial DNA (Leber hereditary optic neuropathy LHON) or mutations in the nuclear gene OPA1 causing autosomal dominant optic (ADOA) neuropathy (Kjer's type) see Fig. 4. OPA1 encodes mitochondrial proteins but is in nuclear DNA. Mutations in mitochondrial

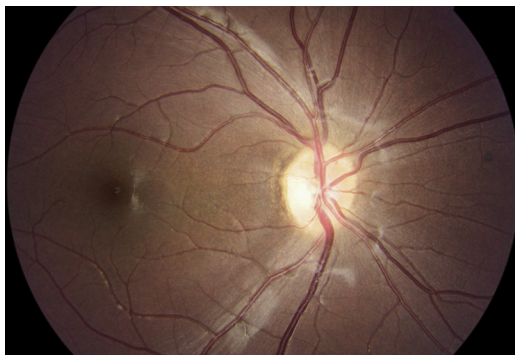


Fig. 4. This child has OPA1 positive mutation; this is autosomal dominant optic atrophy. Note the wedge shaped atrophy temporally.

DNA causing LHON are maternally inherited, whereas mutations in OPA1 are autosomal dominantly inherited from the mother or father. Clinical expressivity is so variable in both conditions that they can be difficult to differentiate unless the inheritance pattern is elucidated with an accurate pedigree. Patients with LHON may benefit from avoidance of certain environmental exposures (smoking, alcohol consumption) that may cause deterioration of the disease. Furthermore, because both diseases (LHON and ADOA) are mitochondrial dysfunctions, an over-the-counter supplement, idebenone, which reduces “stress” on mitochondria, has been shown to have a protective effect in both diseases.^{9–11}

Glaucoma

Mutations in 6 genes (MYOC, PITX2, FOXC1, PAX6, CYP1B1, and LTBP2) are known to cause early-onset glaucoma.¹² Mutations in CYP1B1 and LTBP2 are the only ones that cause recessive disease, whereas the remainder cause glaucoma in a dominant manner. Furthermore, individuals with early-onset glaucoma caused by mutations in MYOC coding for myocilin may be treated in the future with agents that minimize the effects of endoplasmic reticulum stress or may be eligible for clinical trials to test new topical drugs.¹³

DEVELOPMENT OF GROUPINGS OF DISEASES AND SYNDROMES BASED ON CELLULAR EVENTS OR PATHWAYS

Ciliopathies

Two types of cilia exist: intracellular cilia and motile cilia. Intracellular cilia are complex sensory organelles involved in the control of a variety of cellular signaling pathways. These cilia are highly conserved throughout evolution. Cilia receive a variety of extracellular signals, which they transduce and thereby affect proliferation, nerve growth, polarity, differentiation, or tissue maintenance. Since cilia are in all cells, mutations in genes coding for components of cilia affect a multitude of tissues and organ systems in which the cilium-centromere complex functions are important. Ciliopathies are a genetically heterogeneous group of disorders caused by mutations in genes whose products localize to the cilium-centrosome complex.^{14,15}

Important examples of ciliopathies are as follows:

- Retinal-renal syndrome (eg, Senior-Loken syndrome): nephronophthisis in association with retinal dystrophy. Retinal dystrophies are not present in every form of nephronophthisis, but the chance increases if mutations in nephrocystin-5 (NPHP5) are present. NPHP5 interacts with RPGR (mutations in this can cause isolated X-linked retinitis pigmentosa), and both genes are localized in the cilia of renal epithelial cells and retinal photoreceptors, respectively (**Fig. 5**).
- Joubert syndrome: consists of developmental delay and ataxia caused by hypoplasia of the cerebellar vermis in association with retinal coloboma, and is characterized by an irregular breathing pattern during the neonatal period. Recessive mutations in NPHP3, NPHP6/CEP290, NPHP8/RPGRIP1L, AH11, MKS3, ARL13B, INPP5E, and TMEM216, and NPHP1 deletions cause Joubert syndrome.¹⁵
- Meckel syndrome: an autosomal recessive disease that results in perinatal death from dysplasia and malformation of multiple organs. It is characterized by occipital meningoencephalocele, microphthalmia, lung hypoplasia, polycystic kidneys, or renal dysplasia, biliary ectasia, postaxial polydactyly, and situs inversus. Mutations have been described in MKS1, MKS3, NPHP3, NPHP6/CEP290, NPHP8/RPGRIP1L, TMEM216, and CC2D2A.

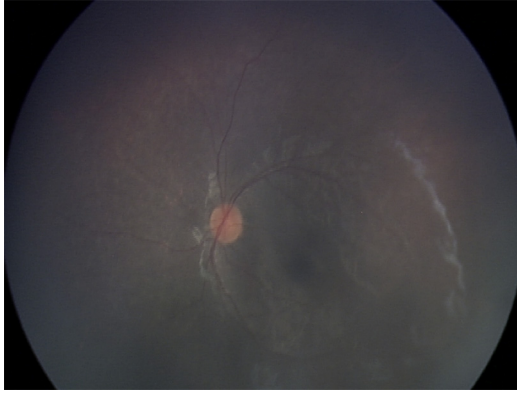


Fig. 5. This child with early-onset retinal dystrophy (age <1 year) was found to have polydipsia and polyuria associated with renal tubular injury/nephronophthisis on evaluation by the renal team.

- Bardet-Biedl syndrome: the Bardet-Biedl syndrome is a multisystem disorder characterized by retinal degeneration, cystic kidney disease, developmental delay, diabetes mellitus, obesity, infertility, and postaxial polydactyly. Mutations in 16 genes (BBS1 to BBS12, MKS1, NPHP6/CEP290, SDCCAG8, and SEPT7 [septin 7]) can cause the Bardet-Biedl syndrome phenotype.
- Usher syndrome: ten different genes are associated with this deaf/blind condition. These genes encode several structurally and functionally distinct proteins, which play a role in stereocilia development in cochlear hair cells, explaining the deafness phenotype when these molecular interactions are perturbed. The mystery is that photoreceptors lack a similar apparatus, and therefore a common theory has been missing for Usher protein function in the 2 neurosensory cell types affected in this syndrome. However, recent animal model work suggests that Usher proteins might regulate protein trafficking between the inner and outer segments of photoreceptors.¹⁶
- Some retinal dystrophy genes are also known to be ciliary genes, such as RP1, RPGR, and RPGRIP1. At present, they do not appear to affect other organ systems.

The severity and extent of organ involvement in ciliopathies depend on the following mechanisms:

- Specific gene mutations cause specific phenotypes. For example, homozygous deletions of NPHP1 usually cause nephronophthisis, whereas 2 truncating mutations of NPHP6/CEP290 cause a Meckel-type phenotype, which is more severe.
- The type of mutation affects phenotype. For example, 2 truncating mutations of NPHP3, NPHP6, NPHP8, or NPHP11/MKS380 cause Meckel syndrome, but the presence of even one missense mutation may result in a milder form of Joubert syndrome.
- Modifier genes affect phenotype. For example, in patients with homozygous NPHP1 deletions (renal only), the presence of an additional heterozygous mutation in NPHP6 or NPHP8 causes additional eye or cerebellar involvement (retinal dystrophy or Joubert syndrome).
- Oligogenicity affects phenotype. For example, Bardet-Biedl syndrome may be caused by the interaction of 2 or more recessive genes with heterozygous

mutations (which would not result in disease themselves because the mutations are not homozygous).

Motile cilia are structurally similar to primary cilia. Genetic defects of these cause primary ciliary dyskinesia, such as Kartagener disease.

RASopathies

The term *RASopathies* refers to a group of 5 neurodevelopmental syndromes (Noonan, LEOPARD, Costello, Cardiofaciocutaneous, and neurofibromatosis-Noonan syndrome) caused by mutations in genes encoding proteins involved in the RAS/MAPK (rat sarcoma/mitogen-activated protein kinase) signaling pathway. This pathway plays a role in regulation of cell determination, proliferation, differentiation, migration, and senescence, and disruption of this pathway can lead to the risk of tumorigenesis and, some evidence suggests, abnormal healing. The study of *RASopathies* is in its infancy.¹⁷

OVERVIEW OF GENETIC TESTING AND PRINCIPLES

This section reviews the capabilities, benefits, and limitations of common genetic testing that may be used in the diagnosis of various ophthalmic conditions. A summary was recently published of the methods used in the select tests discussed herein, with special focus on inherited eye diseases.^{18,19}

Karyotype

Karyotyping is the traditional cytogenetic method used for the assessment of chromosome number and structure. The chromosomal complement is assessed through microscopy. Anomalies are described following the International System for Human Cytogenetic Nomenclature (ISCN), last updated in 2013.¹ Specifically, the resolution of a karyotype is limited to visible alterations, wherein the smallest detectable abnormality is approximately 5 megabases (Mb). Any abnormality below this level will not be observed, resulting in a normal karyotype.

Furthermore, a karyotype may not demonstrate mosaicism, a state in which an individual carries 2 or more genetically distinct cell lines. Because the proportion of mosaic cells may differ among tissues, the likelihood of detecting mosaicism increases with the number of cells counted and, potentially, the sampled tissue. In cases of suspected mosaicism, the number of cells assessed should be increased, from a minimum of 5 in a traditional karyotype to at least 25 or 50 cells.²⁰

For the ophthalmologist, karyotype is most likely to be encountered in the setting of a family history of a chromosome abnormality, individuals in whom a particular chromosome abnormality is suspected based on phenotype, or cases of multiple congenital anomalies for which a specific syndrome is not yet obvious. In summary, the diagnostic utility of chromosome analysis is limited to monosomies, trisomies, balanced and unbalanced translocations, and microdeletion and microduplication syndromes.

Microarray-Based Technologies

Microarrays are cytogenetically based tests focusing on detecting copy number variations in specific alleles across the genome. A *copy number variant* is defined as a genomic segment of at least 1000 nucleotide bases that differ in number when compared with reference genomes.²¹

The 2 major types of microarrays, comparative genomic hybridization (CGH) and single nucleotide polymorphism (SNP) arrays, are discussed later. Comparative genomic

hybridization arrays detect copy number variations by using oligonucleotides (small, synthetic DNA fragments) that correspond to specific chromosomal loci. Targeted CGH arrays may limit the loci to only those associated with genetic disorders, whereas other CGH arrays are more comprehensive. Differences in hybridization intensity between the patient's DNA sample and a reference DNA sample indicate the presence of a copy number variant.²² Comparative genomic hybridization arrays are only capable of detecting changes in copy number, specifically, monosomies, trisomies, unbalanced chromosome translocations, microdeletions, and microduplications at chromosomal loci covered by the oligonucleotide probes. Most notably, CGH arrays are unable to detect balanced chromosome translocations, which would be apparent on a karyotype.

Single nucleotide polymorphism arrays use known polymorphic markers in the human genome to detect copy-number and copy number–neutral variations in the genome. Similar to CGH arrays, the hybridization intensity of the patient's sample to the test probes can quantify the relative amount of DNA present for individual SNPs. Single nucleotide polymorphism arrays are often combined with CGH array technologies, enhancing the diagnostic yield. Compared with karyotyping, the resolutions of microarrays can be less than 100 kilobases.

Comparative genomic hybridization and SNP arrays are used in a pediatric setting for cases involving developmental delay, intellectual disability, or multiple congenital anomalies. A microarray is often a first-line genetic test when a patient's phenotype does not yet suggest a specific genetic syndrome and a detection level greater than karyotyping is desired. Not all copy number variants are pathogenic, and variants of uncertain significance are frequently encountered.²³

Sequencing

DNA sequencing is a primer-initiated technology that allows the sequence of specific genes to be assessed and compared with a reference sequence. Sequencing detects mutations affecting a single nucleotide or a short run of consecutive nucleotides. More specifically, missense, nonsense, frameshift, and splice site mutations are detected by sequencing, as are small insertions and deletions.

The yield of DNA sequencing depends on multiple factors. First, the sensitivity of DNA sequencing is high, but is ultimately depends on the appropriateness of the test given the clinical presentation. Second, a particular condition may be the result of one of several genes, some of which have yet to be recognized as having a role in the pathogenesis of certain diseases. Only the genes known to have this role can be tested, leaving a proportion of cases without a known molecular cause. Third, repetitive sequences within tested genes may limit the areas assessed or the interpretation. This is caused by "slippage" during sequencing, wherein the polymerase cannot accurately bind to the template sequence because of the repetitiveness of the region. Finally, methodologies vary among laboratories with regard to whether all coding exons are sequenced and whether the intronic sequences are included. Furthermore, mutations upstream or downstream from the targeted gene may affect gene expression and are not routinely assessed by commercial laboratories.

In ophthalmologic diseases, sequencing is most useful when a clinical diagnosis is associated with mutations in one or a few genes. As genetic research and technologies expand, knowledge about the relationships between genes and phenotypes increases and the cost of sequencing is decreases, making single-gene studies less relevant for certain diagnoses. To counteract this, DNA sequencing can be performed for numerous genes at one time, such as in a condition-specific panel or in exome sequencing.

Condition-specific panels target the known genes associated with a particular ophthalmic condition, whereas exome sequencing covers approximately 95% of the coding regions of genome. Given the complexities of exome sequencing and the vast amount of information it can provide, both related and unrelated to an individual's symptoms, it is prudent to involve a genetics professional for this testing.

Deletion/Duplication Studies

Deletion/duplication studies use a variety of methods to detect imbalances within a specific gene. In general, these studies complement DNA sequencing in that they are capable of detecting deletions or duplications that may be missed by direct sequencing. These may be missed because DNA sequencing is only able to detect variations compared with a known sequence and has no mechanism for detecting copy number.

DNA sequencing is initiated by primers, which hybridize to the DNA and allow the reaction to proceed. In the presence of a deletion of one of the 2 alleles, the primer is able to hybridize to the intact copy and generate the sequence. Therefore, the test still has an output, and the absence of 1 allele goes undetected. In the presence of a duplication, the primer is able to hybridize to all copies of the allele, allowing the reaction to proceed normally. Because both deletions and duplications of partial or entire genes may account for the pathogenesis of a condition, these variations may be undetected by DNA sequencing, and an individual's molecular diagnosis may not be fully achieved.

The utility of deletion/duplication studies varies, depending on the proportion of cases of a particular disease attributed to copy number variations at the gene level, and the laboratory methods used. Today, one of the most widely used methods is multiplex ligation-dependent probe amplification (MLPA). Multiplex ligation-dependent probe amplification uses probes throughout a targeted DNA sequence. When the probe's sequence is present in the test sample, hybridization and amplification of the probe itself occurs. The amount of the probe is then quantified and the relative amount of the targeted sequences can be determined. In the case of deletions and duplications, fewer and more probes will be detected, respectively. Depending on the size of a gene, MLPA can assess changes to copy number at an exon level.

For clinicians, deletion/duplication studies should be considered when a high clinical suspicion exists for a genetic disease and DNA sequencing was normal. Modern sequencing methods "read" the sequence like a book and see if "it makes sense"; if a whole sentence was missing as the book is "read," one may not realize that anything was wrong as long as the preceding sentence and the following sentence still "flow". This fact is particularly relevant for conditions in which changes to copy number are recognized causes of the disorder. Deletion/duplication studies are irrelevant for men with X-linked conditions, because primers used in DNA sequencing would fail to hybridize to a deleted sequence and no second X chromosome is present to mask the aberration.

NEW THERAPIES FOR GENETIC EYE DISEASE

Much work is in progress at ex vivo and animal model levels for gene therapies for various parts of the eye, including the cornea, trabecular meshwork, and optic nerve, but the area of most advancement in human clinical trials is the treatment of some retinal dystrophies. Specifically, patients with LCA are being treated with gene therapy, but only patients with LCA and mutations in RPE65 can potentially benefit from current RPE65 gene-based clinical trials. Before considering this therapy, a molecular

diagnosis must be established using a genetic test. Recently, 3 clinical trials of gene therapy using recombinant adeno-associated virus vectors have been reported for the treatment of RPE65-related LCA. Substantial gains in visual function of clinical trial participants provide evidence for relevant biologic activity resulting from a newly introduced gene. Reviews of these groundbreaking findings have been published elsewhere.^{24,25}

Recently a group²⁶ reported preliminary results of gene therapy in 6 men with chorioideremia; the 6-month results show promising signs of visual improvement.

SUMMARY

To ensure that patients have the best access to the latest therapies, pediatric ophthalmologists and pediatricians must be receptive to the signs and symptoms of genetic eye disease. Molecular testing should be undertaken with the help of a genetic counselor and/or geneticist. Some academic centers have access to genetic counselors with expertise in ophthalmic genetic disorders, and these experts are invaluable in helping to direct testing and counseling.

REFERENCES

1. Allen RC. Genetic diseases affecting the eyelids: what should a clinician know? *Curr Opin Ophthalmol* 2013;24(5):463–77.
2. Mataftsi A, Islam L, Kelberman D, et al. Chromosome abnormalities and the genetics of congenital corneal opacification. *Mol Vis* 2011;17:1624–40.
3. Chamney S, McGimpsey S, McConnell V, et al. Iris flocculi as an ocular marker of ACTA2 mutation in familial thoracic aortic aneurysms and dissections. *Ophthalmic Genet* 2013. [Epub ahead of print].
4. Moller HU, Fledelius HC, Milewicz DM, et al. Eye features in three Danish patients with multisystemic smooth muscle dysfunction syndrome. *Br J Ophthalmol* 2012; 96(9):1227–31.
5. Colin E, Sentilhes L, Sarfati A, et al. Fetal intracerebral hemorrhage and cataract: think COL4A1. *J Perinatol* 2014;34(1):75–7.
6. Snead MP, McNinch AM, Poulson AV, et al. Richards Stickler syndrome, ocular-only variants and a key diagnostic role for the ophthalmologist. *Eye (Lond)* 2011;25:1389–400.
7. den Hollander AI, Roepman R, Koenekoop RK, et al. Leber congenital amaurosis: genes, proteins and disease mechanisms. *Prog Retin Eye Res* 2008;27(4): 391–419.
8. Hanein S, Perrault I, Gerber S, et al. Leber congenital amaurosis: comprehensive survey of the genetic heterogeneity, refinement of the clinical definition, and genotype-phenotype correlations as a strategy for molecular diagnosis. *Hum Mutat* 2004;23(4):306–17.
9. Barboni P, Valentino ML, La Morgia C, et al. Idebenone treatment in patients with OPA1-mutant dominant optic atrophy. *Brain* 2013;136(Pt 2):e231.
10. Rudolph G, Dimitriadis K, Büchner B, et al. Effects of idebenone on color vision in patients with leber hereditary optic neuropathy. *J Neuroophthalmol* 2013;33(1): 30–6.
11. Yu-Wai-Man P, Griffiths PG, Chinnery PF. Mitochondrial optic neuropathies: disease mechanisms and therapeutic strategies. *Prog Retin Eye Res* 2011;30(2): 81–114.
12. Fan BJ, Wiggs JL. Glaucoma: genes, phenotypes, and new directions for therapy. *J Clin Invest* 2010;120(9):3064–72.

13. Zode GS, Bugge KE, Mohan K, et al. Topical ocular sodium 4-phenylbutyrate rescues glaucoma in a myocilin mouse model of primary open-angle glaucoma. *Invest Ophthalmol Vis Sci* 2012;53(3):1557–65.
14. Adams NA, Awadein A, Toma HS. The retinal ciliopathies. *Ophthalmic Genet* 2007;28:113–25.
15. Hildebrandt F, Benzing T, Katsanis N. Ciliopathies. *N Engl J Med* 2011;364:1533–43.
16. Cosgrove D, Zallocchi M. Usher protein functions in hair cells and photoreceptors. *Int J Biochem Cell Biol* 2014;46:80–9.
17. Cizmarova M, Kostalova L, Pribilincova Z, et al. Rasopathies—dysmorphic syndromes with short stature and risk of malignancy. *Endocr Regul* 2013;47:217–22.
18. Gabriel LA, Traboulsi EI. Genetic diagnostic methods for inherited eye disease. *Middle East Afr J Ophthalmol* 2011;18(1):24–9.
19. Shaffer LG, McGowan-Jordan J, Schmid M, editors. An international system for human cytogenetic nomenclature. Unionville (CT): S. Karger Publishers, Inc; 2013.
20. Scott SA, Cohen N, Brandt T, et al. Detection of low-level mosaicism and placental mosaicism by oligonucleotide array comparative genomic hybridization. *Genet Med* 2010;12:85–92.
21. Feuk L, Carson AR, Scherer SW. Structural variation in the human genome. *Nat Rev Genet* 2006;7(2):85–97.
22. Oostlander AE, Meijer GA, Ylstra B. Microarray-based comparative genomic hybridization and its application in human genetics. *Clin Genet* 2004;66:488–95.
23. Manning M, Louanne H. Array-based technology and recommendations for utilization in medical genetics practice for detection of chromosomal abnormalities. *Genet Med* 2010;12(11):742–5.
24. Cideciyan AV. Leber congenital amaurosis due to *RPE65* mutations and its treatment with gene therapy. *Prog Retin Eye Res* 2010;29(5):398–427.
25. Jacobson SG, Cideciyan AV, Ratnakaram R, et al. Gene therapy for Leber congenital amaurosis caused by *RPE65* mutations: safety and efficacy in 15 children and adults followed up to 3 years. *Arch Ophthalmol* 2012;130(1):9–24.
26. MacLaren RE, Groppe M, Barnard AR, et al. Retinal gene therapy in patients with choroideremia: initial findings from a phase 1/2 clinical trial. *Lancet* 2014. [http://dx.doi.org/10.1016/S0140-6736\(13\)62117-0](http://dx.doi.org/10.1016/S0140-6736(13)62117-0).