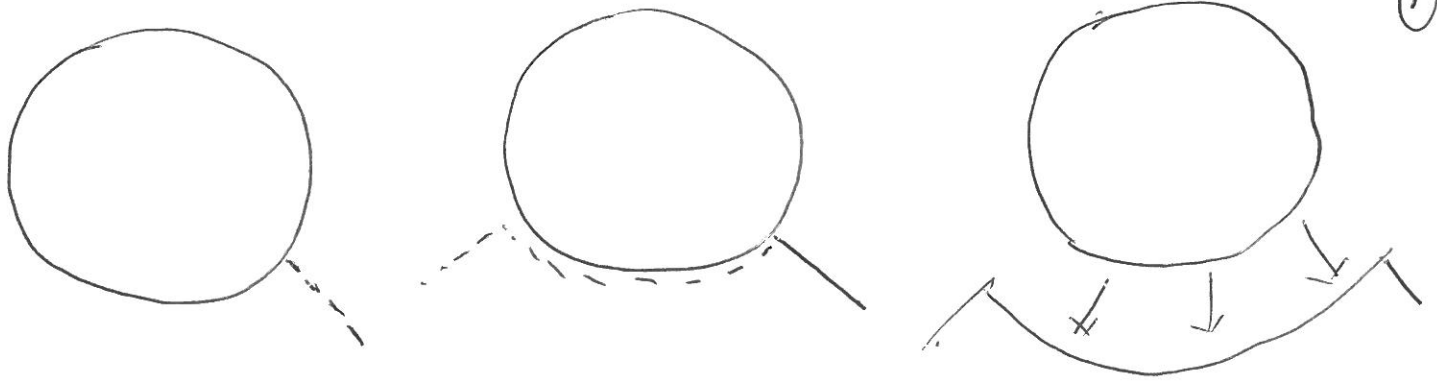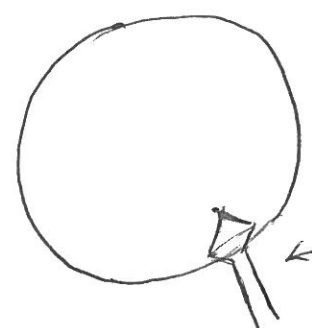
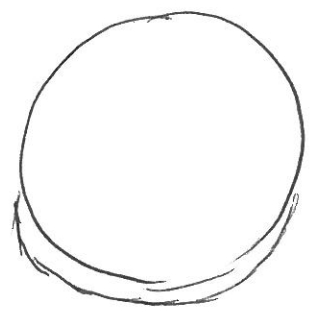
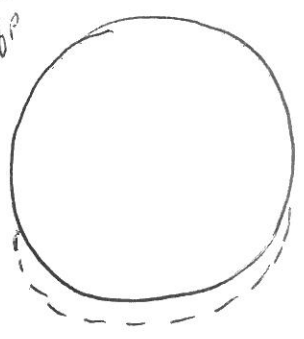

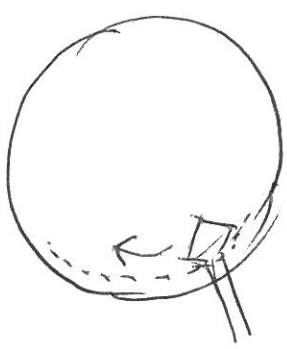



Angled
crescent
knife



keratome




Horizontal
ant^r capsulotomy



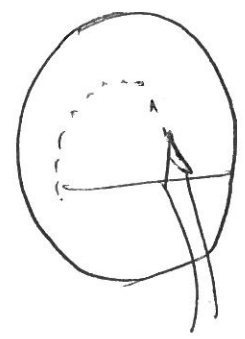
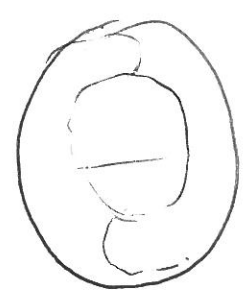
Gentle hydro-
dissection




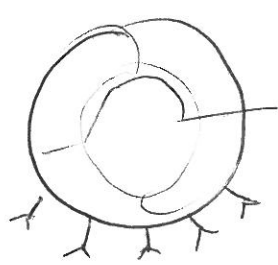
Nucleus
delivery.



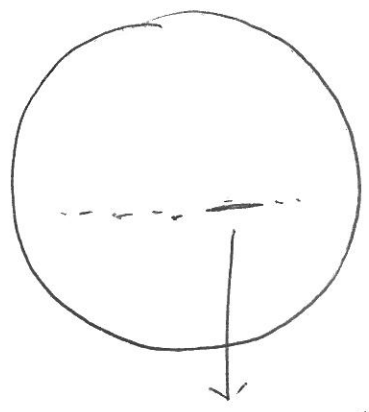
Cortical
cleanup



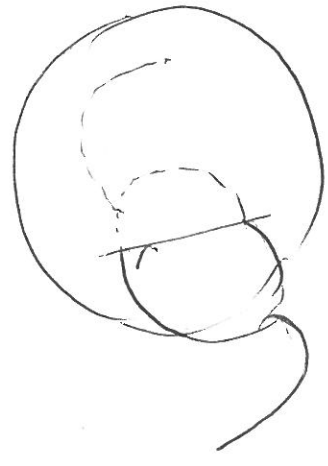
Ant^r
Capsulotomy



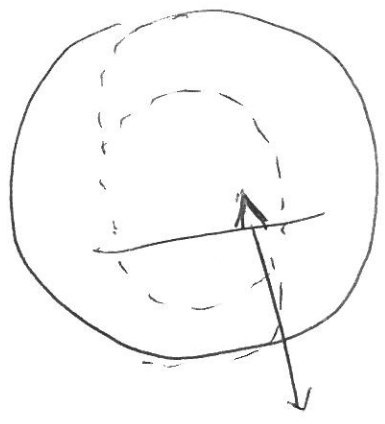
Conj
cavity



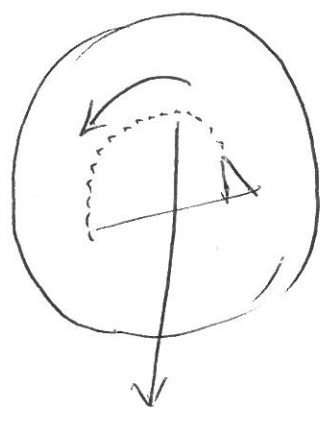
Horizontal ant^r
Capsulotomy
(Cystotome + Vannas)



In-the bag IOL



Initial cut
c Vannas



Utrata
forceps