

Complications of sulcus placement of single-piece acrylic intraocular lenses

Recommendations for backup IOL implantation following posterior capsule rupture

David F. Chang, MD, Samuel Masket, MD, Kevin M. Miller, MD, Rosa Braga-Mele, MD, Brian C. Little, MD, Nick Mamalis, MD, Thomas A. Oetting, MD, Mark Packer, MD, for the ASCRS Cataract Clinical Committee

PURPOSE: To describe complications arising from sulcus placement of single-piece acrylic (SPA) intraocular lenses (IOLs), evaluate IOL options for eyes that lack adequate capsule support, and examine the appropriateness of various IOL designs for sulcus placement.

SETTING: University and private anterior segment surgery practices.

METHODS: Patients referred for complications of SPA IOLs in the ciliary sulcus from 2006 and 2008 were identified. Demographic information, examination findings, and complications of the initial surgery were recorded. Details of surgical interventions and the most recent corrected distance visual acuity (CDVA) were noted. A thorough review of the literature was undertaken to analyze options for IOL placement.

RESULTS: Complications of sulcus SPA IOLs included pigment dispersion, iris transillumination defects, dysphotopsia, elevated intraocular pressure, intraocular hemorrhage, and cystoid macular edema. Two patients in the series of 30 patients experienced 1 complication; 8 experienced 2 complications; 13 experienced 3 complications; 4 experienced 4 complications; and 2 experienced 5 complications. Twenty-eight eyes (93%) required surgical intervention; IOL exchange was performed in 25 (83%). Postoperatively, the mean CDVA improved, with most eyes attaining 20/20.

CONCLUSIONS: Intraocular lenses designed solely for the capsular bag should not be placed in the ciliary sulcus. Backup IOLs in appropriate powers, sizes, and designs should be available for every cataract procedure. The development, investigation, and supply of IOLs specifically designed for placement in eyes that lack adequate capsule support represent clinically important endeavors for ophthalmology and the ophthalmic industry.

J Cataract Refract Surg 2009; 35:1445–1458 © 2009 ASCRS and ESCRS

Single-piece acrylic (SPA) intraocular lenses (IOLs) currently account for approximately one half of the IOLs implanted concurrent with cataract surgery in the United States (Alcon, Inc.; data on file). Given the large annual volume of cataract surgery performed worldwide, a significant number of SPA IOLs may be inadvertently or intentionally placed in the ciliary sulcus; eg, following posterior capsule rupture. This raises the question of whether this strategy is appropriate and the larger issues of which IOL designs are suitable as backup IOLs in the absence of secure capsular bag support. The growing popularity of accommodating, multifocal, toric, and aspheric monofocal IOLs

raises additional concerns about whether these IOLs are appropriate for placement in the ciliary sulcus. Finally, the debate continues over whether an anterior chamber IOL (AC IOL) or a sutured posterior chamber IOL (PC IOL) is the best long-term option in the absence of adequate capsule support.

To help answer these questions, members of the American Society of Cataract and Refractive Surgery (ASCRS) Cataract Clinical Committee conducted a retrospective survey of patients referred for complications associated with SPA IOLs implanted in the ciliary sulcus. We also reviewed the literature with respect to recommendations for backup IOL design and placement.

PATIENTS AND METHODS

Six members of the ASCRS Cataract Clinical Committee reviewed their office records for calendar years 2006 to 2008 to identify patients who had experienced complications of SPA IOL implantation in the ciliary sulcus. All the patients had been referred; none of the investigators implant SPA IOLs in the sulcus. In some cases, the SPA IOL sulcus implantation had occurred several years before the initial referral visit.

Demographic information, examination findings, and complications of the initial surgery were recorded from the medical records. Details of surgical interventions and the most recent corrected distance visual acuity (CDVA) were noted.

RESULTS

Committee members contributed 30 patients (30 eyes) to the database. Demographic characteristics of the patient population are shown in Table 1 and the clinical findings at the time of patient presentation, in Table 2. Twenty-nine of 30 IOLs were single-piece AcrySof IOLs (Alcon, Inc.); the most common model was the SA60AT. Posterior capsule rupture and IOL decentration were observed in approximately two thirds of the eyes. No SPA IOL was suture fixated to the iris or sclera. At the time of initial consultation, the CDVA ranged from 20/20 to 20/400 and the mean intraocular pressure (IOP) was 22.1 mm Hg. Approximately one third of the patients were taking at least 1 IOP-lowering medication.

Complications other than posterior capsule rupture are detailed in Table 3. The most common were pigment dispersion and iris transillumination defects, followed by IOL edge symptoms and elevated IOP. Intraocular hemorrhage and cystoid macular edema (CME) were relatively infrequent, although the latter may have been underreported because of the retrospective nature of the data collection. One patient had none of the complications listed in Table 3. She was included in the analysis because she experienced a posterior capsule rupture and asymptomatic IOL decentration. Two patients presented with 1 complication (IOL edge glare or pigment dispersion). Eight patients experienced 2 of the complications listed in Table 3; 13 experienced 3 complications; 4 experienced

4 complications; and 2 experienced 5 complications. No patient experienced all 6 complications.

Two eyes (7%) are currently being managed medically or by observation. The other 28 eyes (93%) had a surgical intervention. Details of the surgical interventions and the most recent CDVAs are shown in Table 4. An IOL was repositioned in 1 eye, and a haptic was amputated in another eye. An IOL exchange was performed in 26 of the 28 eyes that had a surgical intervention. More than half the eyes having secondary surgery had a simultaneous anterior vitrectomy. The most popular replacement IOL was the Staar Surgical AQ2010V foldable 3-piece silicone IOL. The postoperative visual acuity was better, on average, than the preoperative acuity, with most eyes attaining a CDVA of 20/20. The eye with the worst postoperative CDVA had chronic CME and poorly controlled IOP. To illustrate the typical clinical course, 4 representative cases are described.

Case 1

This 60-year-old woman displayed marked iris chafing in the right eye at the time she presented (Figure 1). Seven years earlier (2000), cataract surgery had been complicated by an incomplete anterior capsulorhexis. An SPA IOL was placed; however, the capsular bag enclosed only the temporally positioned loop. The superior loop and optic were located in the ciliary sulcus, where they freely contacted the posterior iris, causing marked iris chafing. Subsequently, the patient developed recurrent episodes of microhyphema characterized by visual "white outs," chronic IOP elevation, and smoldering iridocyclitis. At the time of referral, she required multiple glaucoma medications in addition to corticosteroid and nonsteroidal topical agents. In July 2007, the SPA IOL was exchanged for a sulcus-positioned 3-piece silicone IOL that was suture fixated to the iris to ensure stability. Following the IOL exchange, the patient experienced no further white outs, the iridocyclitis resolved, and the topical medications were significantly reduced.

Case 2

This 66-year-old man had uneventful cataract surgery with multifocal IOL implantation in the capsular bag in the right eye. Surgery in the left eye in March 2007 was complicated by a radial anterior capsule tear that extended posteriorly (Figure 2). A multifocal SPA IOL was intentionally placed in the ciliary sulcus. Given the large anterior segment of the eye, the SPA IOL was unstable, allowing lens movement and iris chafing. On examination, a microhyphema and a microscopic vitreous hemorrhage were present. Subsequent surgery in May 2007 included removing the

Submitted: March 19, 2009.

Final revision submitted: April 16, 2009.

Accepted: April 22, 2009.

No author has a financial or proprietary interest in any material or method mentioned.

Corresponding author: David F. Chang, MD, Altos Eye Physicians, 762 Altos Oaks Drive, Suite 1, Los Altos, California 94024, USA. E-mail: dceye@earthlink.net.

Table 1. Demographic characteristics of the group.

Number of patients	30
Age at time of initial surgery (years)	
Mean	69
Range	49–88
Race	
Asian	4
Black	1
White	24
Hispanic	1
Sex	
Female	13
Male	17
Year of initial surgery	
2000	2
2001	1
2002	1
2003	1
2004	2
2005	5
2006	5
2007	8
2008	5

SPA IOL, performing an anterior vitrectomy, and implanting a 3-piece AcrySof multifocal IOL in the ciliary sulcus with iris suture fixation for stability. There has been no recurrence of vitreous hemorrhage.

Case 3

This 71-year-old woman had cataract surgery in April 2008 that left the superior loop of an SPA IOL anterior to the capsulotomy, inducing marked iris chafing and IOP elevation to 38 mm Hg (Figure 3). In addition, a posterior capsulotomy with anterior vitreous herniation was noted. In September 2008, an anterior vitrectomy was combined with amputation of the offending lens haptic. The IOP rapidly normalized once the source of iris chafing was surgically eliminated, and the IOL remained centered after the haptic amputation.

Case 4

This 65-year-old man reportedly had uneventful cataract surgery with implantation of an SPA IOL in 2005. At the time of presentation, 1 haptic was in the capsular bag and the remainder of the IOL was in the sulcus. Slitlamp examination showed pigment dispersion and prominent iris transillumination defects (Figure 4). The patient also experienced episodes of intraocular hemorrhaging. Anterior segment optical coherence tomography (OCT) revealed the sulcus location of the

Table 2. Findings at the time of presentation.

Affected Eye	
Left	11
Right	19
SAP IOL Model	
Alcon SA60AT	20
Alcon SN60WF	6
Alcon ReSTOR	1
Alcon toric	1
Alcon AcrySof (model unknown)	1
Rayner 570C	1
Posterior capsule ruptured	
No	9
Yes	21
IOL decentered	
No	9
Yes	21
IOL location	
One haptic in the sulcus	11
Both haptics in the sulcus	19
Corrected distance visual acuity	
20/20	10
20/25	5
20/30	6
20/40	3
20/50	1
20/60	2
≤20/200	3
Maximum IOP (mm Hg)	
Mean	22.1
Range	14–38
Number of IOP lowering medications	
0	19
1	3
2	6
3	1
4	1

IOL = intraocular lens; IOP = intraocular pressure

IOL and the proximity of the dilated posterior iris surface to the square anterior edge of the IOL (Figure 5). Successful viscodissection of the capsular bag and IOL repositioning were performed in November 2008.

DISCUSSION

Should SPA IOLs Be Placed in the Sulcus?

The question of whether SPA IOLs should be placed in the sulcus was posed using anonymous audience response pads at the Spotlight on Cataract Complications Symposium at the 2008 American Academy of Ophthalmology annual meeting. Forty-seven percent of the respondents said “never,” 40% said “yes, if capsule support was adequate,” 2% said “yes, if suture fixated,” and 11% said “yes, if no other PC IOL was available.”

Table 3. Complications of SPA IOL implantation in the ciliary sulcus.

Complication	Number of Patients
IOL edge symptoms	
No	17
Yes	13
Pigment dispersion	
No	5
Yes	25
Iris transillumination defects	
No	6
Yes	24
Maximum IOP > 22 mm Hg	
No	19
Yes	10
Unrecorded	1
Intraocular hemorrhage	
No	23
Yes	7
Cystoid macular edema	
No	24
Yes	4
Unrecorded	2

IOL = intraocular lens; IOP = intraocular pressure

The peer-reviewed literature also does not conclusively answer this controversial question. Two articles from one center support the use of SPA IOLs in the sulcus,^{1,2} but there are several case reports of SPA IOLs inducing complications ranging from iris chafing and the uveitis-glaucoma-hyphema (UGH) syndrome to vitreous hemorrhage.³⁻⁶ Finally, one study⁷ showed good centration and acuity following SPA IOL sulcus placement but a high incidence of secondary glaucoma.

To our knowledge, our retrospective survey represents the largest reported series of chronic complications resulting from sulcus placement of SPA IOLs. In addition to pigment dispersion syndrome, secondary IOP elevation, recurrent iridocyclitis, and CME, the most common complication was lens decentration, which frequently resulted in symptomatic edge glare. We limited this survey to the referral practices of the ASCRS Cataract Clinical Committee members. Although it is impossible to know how many eyes have had sulcus SPA IOL implantation without complications, we believe the problems observed in this series are consistent with and predicted by the design of SPA IOLs. We did not attempt to assess complications of 3-piece PC IOLs implanted in the ciliary sulcus.

Most of the sulcus-fixated SPA IOLs in our series were the SA60AT design which, as noted in the package insert, is designed for implantation in the capsular

Table 4. Surgical interventions and final CDVA.

Surgical Intervention	Number of Eyes
Procedure	
Haptic excision	1
IOL exchange alone	10
IOL exchange and vitrectomy	15
IOL repositioning	1
None	2
Unknown procedure	1
Replacement IOL	
Alcon CR70BU	1
Alcon MA60AC	3
Alcon MN60AC	4
Alcon MN60D3	1
Alcon SN60T4	1
Bausch and Lomb LI61AOV	2
Rayner 570C	1
Staar AQ2010V	10
Staar CQ2015A	2
Unknown	1
CDVA	
20/20	17
20/25	4
20/30	4
20/40	1
20/50	0
20/60	1 (pending capsulotomy)
20/70	1
20/200	1
Unknown	1

CDVA = corrected distance visual acuity; IOL = intraocular lens

bag. This design is not compatible with sulcus placement for several reasons. The bulky single-piece haptics are large and thick enough to contact the posterior iris when placed in the sulcus. The haptics are planar rather than angulated and therefore do not vault the optic posteriorly from the iris. Finally, the overall loop-to-loop dimension is only 13.0 mm, which is too short for many eyes. Especially if the haptics do not fully extend because of their low compressive force, the IOL will be inclined to decenter in the ciliary sulcus of a larger eye.

Aside from the dimensions of these IOLs, the hydrophobic acrylic material has a tacky, textured finish rather than a smooth surface. When not confined to the capsular bag, the roughened surface and sharp square edges of the optic and thick haptics cause chafing of the posterior iris surface. The resulting pigment dispersion syndrome is associated with iris transillumination defects and secondary glaucoma. Contact between the sharp edges and the posterior iris vasculature may also cause chronic uveal inflammation

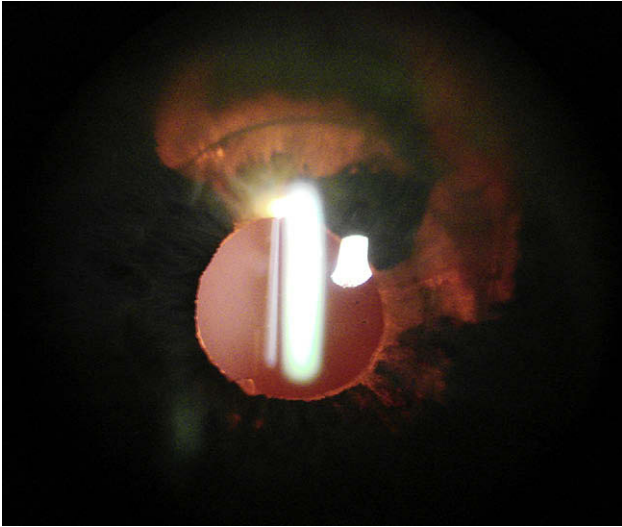


Figure 1. Case 1: The patient experienced pigment dispersion, iris transillumination defects (seen in this retroillumination photograph), elevated IOP, and intraocular hemorrhage after partial sulcus implantation of an SPA IOL.

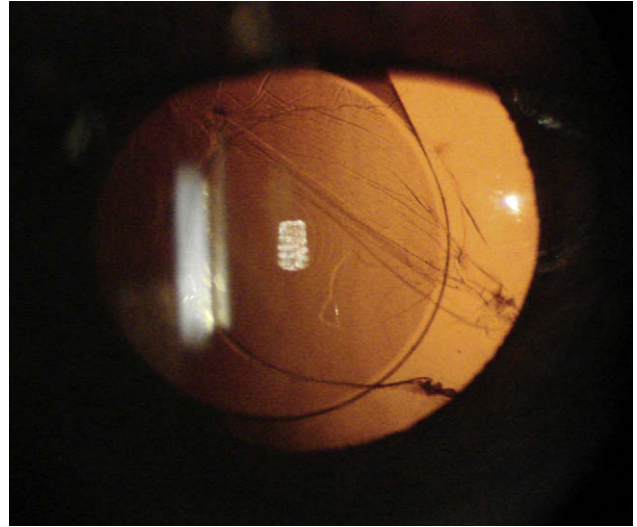


Figure 2. Case 2: The patient experienced IOL decentration, pigment dispersion, iris transillumination, elevated IOP, and intraocular hemorrhage after sulcus implantation of an SPA IOL.

and recurrent microhyphemas that can impair vision and abruptly raise IOP—the UGH syndrome. **Figure 6** shows an SPA IOL that was explanted from an eye with pigment dispersion, glaucoma, and chronic inflammation.

Although they may have a smoother surface, single-piece hydrophilic acrylic IOLs also have large, thick haptics that are not primarily suited for placement in the ciliary sulcus. The C-flex 570 C and Superflex 620H (Rayner) are foldable single-piece hydrophilic

acrylic PC IOLs with closed-loop planar haptics. The manufacturer suggests that these IOLs can be used for sulcus fixation but acknowledges a risk for iris chafing and pigment dispersion (Available at: <http://www.rayner.com/products.php?id=1>. Accessed May 3, 2009). We believe that this single-piece planar design with a square-edged optic and an overall length of only 12.0 mm (570C) or 12.5 mm (620H) engenders the same risks as any single-piece hydrophobic acrylic IOL placed in the sulcus. One such

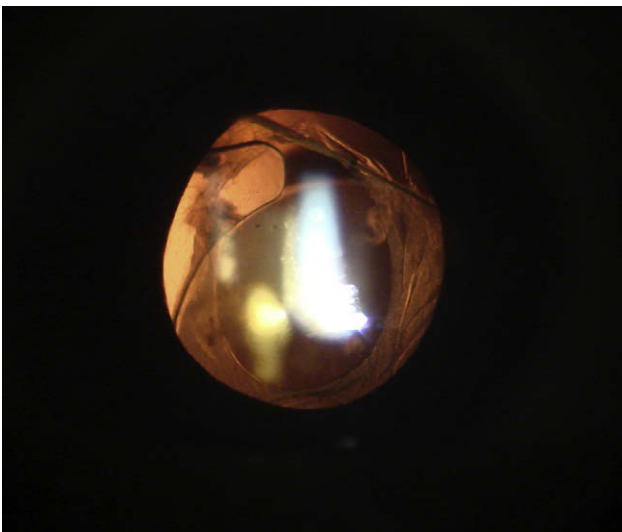


Figure 3. Case 3: The patient experienced IOL edge symptoms, pigment dispersion, iris transillumination, and intraocular hemorrhage following partial sulcus implantation of an SPA IOL.

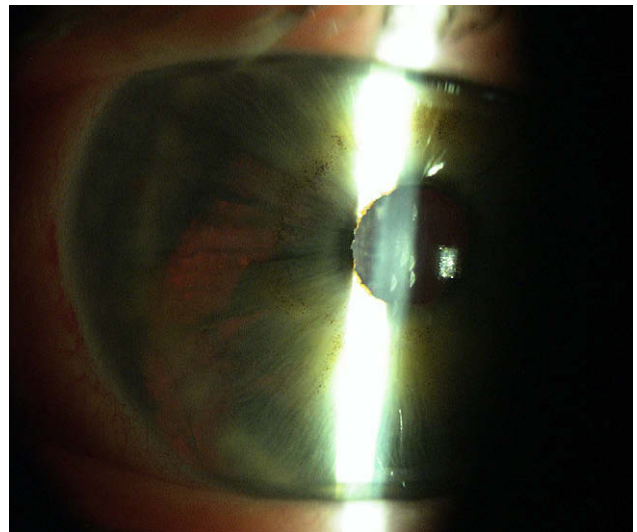


Figure 4. Case 4: The patient experienced pigment dispersion, iris transillumination, and intraocular hemorrhaging from partial sulcus implantation of an SPA IOL.

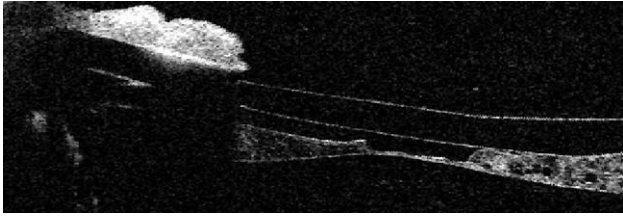


Figure 5. Case 4: Anterior segment OCT image shows the proximity of the square anterior edge of the IOL to the posterior surface of the dilated iris. The clinical photograph is shown in Figure 4.

case is included in our series of complications, and we advise against placing this model in the ciliary sulcus.

The posterior iris-chafing syndrome resulting from sulcus placement of IOLs was first defined more than 2 decades ago.⁸ The subsequent ability to routinely confine IOLs to the capsular bag with a capsulorhexis all but eliminated this problem. However, in a small percentage of cases, one or both SPA haptics may reside in the ciliary sulcus because of anterior or posterior capsule tears or accidental failure to place both haptics in the capsular bag. These cases are susceptible to iris chafing and the UGH syndrome.

Micheli et al.³ reported a case in which a SPA IOL haptic became displaced from the capsular bag into the ciliary sulcus, causing dispersion of posterior iris pigment. Uy and Chan⁷ published a series of 20 eyes with SPA IOLs placed in the ciliary sulcus following posterior capsule rupture. Thirty-five percent of the eyes developed pigment dispersion, and 15% developed secondary pigment dispersion glaucoma. There is a case report of a deformed SPA IOL haptic rubbing the posterior iris and causing pigment dispersion despite being placed in the capsular bag.⁹ Finally, it should be noted that pigment dispersion has also been reported with square-edged 3-piece hydrophobic acrylic IOLs placed in the sulcus.¹⁰⁻¹⁴

Under the direction of one of the authors (N.M.), several sulcus-fixated SPA IOLs that were explanted because of pigment dispersion syndrome were analyzed at the Intermountain Ocular Research Center using light and scanning electron microscopy.⁴ The most common histopathologic finding was pigment granules on the anterior surface of the IOL (Figure 6). This accumulation was greatest on the haptic but also appeared on the peripheral optic and haptic-optic junction. These findings are consistent with posterior iris chafing caused by the optic and the relatively thick flexible haptics, all of which have squared edges and unpolished side walls.

A final question concerns whether 1-piece hydrophobic or hydrophilic acrylic IOLs can be implanted in the ciliary sulcus with transscleral suture fixation. Kim et al.¹⁵ reported a case series of transscleral



Figure 6. Intraocular lens removed from an eye with pigment dispersion, glaucoma, and chronic inflammation. It shows a large number of pigment granules on the anterior surface, especially near the optic-haptic junction.

fixation of the hydrophilic C-flex IOL in 29 eyes in which the mean CDVA improved with limited complications. However, even with transscleral fixation, we remain concerned that the thick planar haptics and anterior square edge of the optic pose a greater risk for iris chafing than 3-piece PC IOLs with round-edged optics.¹⁰⁻¹⁴ In conclusion, we believe that the results of our retrospective survey argue against implanting hydrophobic or hydrophilic SPA IOLs if they will not be fully enclosed by the capsular bag.

Surgical Recommendations for Placing PC IOLs in the Sulcus

Any IOL placed in the ciliary sulcus should have sufficient posterior iris clearance and secure fixation. The latter not only ensures long-term centration, but also avoids lens movement or tilting that can cause uveal irritation, microhyphema, and pigment dispersion syndrome. Even with secure fixation, chronic inflammation and pigment dispersion can result from the posterior iris rubbing against the optic; the haptics should be angulated posteriorly to maximize iris clearance.¹⁶ A 3-piece PC IOL has the advantage of thin, posteriorly angulated C-shaped haptics. Ideally, the anterior optic surface should be smooth and have rounded edges to minimize iris chafing should any posterior iris contact occur. In the absence of suturing, proper IOL fixation requires adequate capsule support and lateral stability within the ciliary sulcus plane. With posterior capsule rupture, this is best achieved by capturing the optic within a well-centered capsulorhexis whose diameter must be slightly smaller than that of the optic.^{17,18} Optic capture is achieved by first

placing the entire 3-piece IOL in the sulcus and then sequentially depressing each side of the optic beneath the rim of the intact capsulorhexis. Peripheral contact between the haptic and the ciliary sulcus is not necessary for stable fixation and centration in this situation.

Lacking optic capture with a capsulorhexis, the overall haptic diameter must be sufficiently long to avoid lateral subluxation within the sulcus space. Intended for intracapsular placement, most available foldable IOLs measure 13.0 mm or less from end to end and may be too short for eyes with larger ciliary sulcus dimensions. A larger corneal diameter (≥ 12.5 mm) is generally associated with a larger anterior segment. Unfortunately, there is no accurate way to judge the ciliary sulcus diameter by external measurements. Werner et al.¹⁹ found poor correlation between the white-to-white corneal diameter and the ciliary sulcus diameter in a study of 22 phakic cadaver eyes, and others have confirmed this poor correlation using different methods of sulcus diameter measurement.²⁰⁻²³ Two of these studies suggest there is a significant but negative correlation with mean corneal curvature, meaning that flatter keratometry readings are associated with larger sulcus diameters.^{20,23} Further complicating matters, the sulcus diameter can vary between different sagittal meridians in the same eye. Using 35 MHz ultrasound biomicroscopy in 28 eyes from normal volunteers, Oh et al.²² found that the horizontal sulcus diameter was always shorter than the vertical diameter (mean difference $0.67 \text{ mm} \pm 0.26$ [SD]; $P < .001$). This means that an initially well-centered 3-piece IOL may later decenter following rotation into a wider sulcus meridian.

In light of these factors, we recommend using the longest available 3-piece foldable PC IOL with a minimum 6.0 mm optic diameter for sulcus placement without capsulorhexis capture. The haptics should be angulated posteriorly, and we advise against using any IOL shorter than 13.0 mm in this situation. Poly(methyl methacrylate) (PMMA) PC IOLs with 6.5 mm optics and a 14.0 mm overall length are available but require a much larger incision for implantation. This may be undesirable if a clear corneal incision has been made under topical anesthesia. Among foldable IOLs currently available in the U.S., only the Staar Surgical silicone AQ2010 V has a 13.5 mm long haptic-haptic length in the 5 to 30 diopter (D) power range. The slightly larger 6.3 mm optic diameter, rounded anterior edge, and 10-degree haptic angulation are additional advantages of this particular model.

When posterior capsule rupture is accompanied by vitreous loss, the risk for subsequent retinal detachment should be considered. Silicone IOLs may compromise surgical visibility should silicone oil or expansile gas be required.^{24,25} Among foldable 3-piece hydrophobic acrylic IOLs, the Alcon MA 50 has

a 6.5 mm diameter optic but a square anterior optic edge and an overall haptic length of only 13.0 mm. There are several case reports of pigment dispersion following piggyback implantation of 3-piece hydrophobic acrylic IOLs in the sulcus.¹⁰⁻¹⁴ These cases demonstrate that the sharp anterior edge of this optic is undesirable in this location. In our series, the silicone AQ2010 V was the most frequently selected replacement lens for IOL exchange, with the surgeons reasoning that its 13.5 mm overall length and rounded optic edge outweighed potential disadvantages of the silicone material.

If residual capsule support is lacking in 1 quadrant, the haptics of a sulcus-placed 3-piece IOL should be oriented 90 degrees away from the peripheral defect. There are no clear guidelines regarding the minimum amount of residual capsule necessary to support a PC IOL in the sulcus without suture fixation. In a retrospective series of 36 eyes, Loya et al.²⁶ found that even with a minimum 180 degrees of circumferential capsule remnant, 56% of the IOLs were tilted when examined by ultrasound biomicroscopy. Only 47% of eyes had both haptics located in the sulcus as intended. If the capsule support is questionable, Zarei-Ghanavati et al.²⁷ recommend using an external safety suture affixed to 1 haptic to retrieve the IOL should it be unstable in the sulcus. In the presence of adequate capsule support for at least 1 haptic, one author (D.C.) reported that a single McCannel iris-haptic 10-0 polypropylene suture can provide stable centration and fixation.^{28,29} Suture fixation of 1 or both haptics of a 3-piece foldable PC IOL to the iris or sclera is an option when there is insufficient capsule support.³⁰ Even with adequate residual posterior capsule support, suture fixation of 1 haptic should also be considered if capsulorhexis optic capture is not possible and a sufficiently long 3-piece foldable IOL is not available. Alternatively, the incision can be widened to accommodate a larger PMMA PC IOL or an open-loop AC IOL.

Finally, the power of the sulcus IOL must be adjusted according to the A-constant of the backup IOL model and the expected change in effective lens position, relative to that assumed for capsular bag fixation.³¹⁻³⁴ With capsulorhexis capture, the same IOL power calculated for capsular bag fixation can generally be used. However, because of the more anterior optic location, the power should be reduced by 0.5 to 1.0 D when the entire PC IOL is placed in the ciliary sulcus.³²⁻³⁴

Should Negative Aspheric PC IOLs Be Placed in the Ciliary Sulcus?

Optical laboratory studies of wavefront-corrected IOLs with negative spherical aberration have

demonstrated decreased efficacy when significant tilt or decentration occurs. This problem is of particular concern when the IOL is placed in the ciliary sulcus instead of the capsular bag. Peer-reviewed studies using postoperative Scheimpflug photography to assess lens centration report mean IOL decentration to be within 0.1 to 0.3 mm with capsular bag fixation.^{35–37}

Only a few studies have examined the centration of IOLs fixated in the ciliary sulcus. Legler et al.³⁸ examined the effect of PC IOL dimensions, design, style, loop fixation, and anterior capsule tears on lens centration. They found that decentration was least with symmetrical bag–bag haptic fixation and no radial anterior capsule tears (mean 0.20 ± 0.05 mm). Asymmetric bag–sulcus fixation in the presence of anterior capsule tears was associated with the highest decentration rate (mean 0.68 ± 0.28 mm). Baumeister and Kohnen³⁹ investigated centration of sulcus-placed piggyback PC IOLs used to correct a hyperopic power surprise. The piggyback IOL had a higher mean decentration (0.49 ± 0.20 mm after 12 months) than the posterior IOL (0.21 ± 0.13 mm after 12 months).

Given the potential for sulcus-fixated IOLs to become decentered by more than 0.5 mm, the effect of tilt and decentration of negatively aspheric IOLs on spherical and other higher-order aberrations (HOAs) becomes an important consideration. Using ray-tracing, Altmann et al.⁴⁰ studied the theoretical optical performance of 3 silicone IOL designs in the presence of decentration. The design models were a spherical IOL (LI61U, Bausch & Lomb), a negatively aspheric IOL (Tecnis Z9000, Abbott Medical Optics), and a purely zero aspheric IOL (SofPort AO, Bausch & Lomb). A Monte Carlo simulation analysis performed 1000 trials with IOL decentration while randomly varying pupil size. Decentration of the spherical LI61U and the negatively aspheric Tecnis Z9000 IOLs led to asymmetrical HOAs that compromised the optical performance of the model eye; decentration did not affect performance with the purely aspheric IOL. Specifically, optical performance was better with the zero aspheric SofPort AO IOL than with the Tecnis Z9000 IOL for 3.0 mm, 4.0 mm, and 5.0 mm pupil diameters when decentration exceeded 0.15 mm, 0.30 mm, and 0.38 mm, respectively. Optical performance with the spherical LI61U IOL was better than with the Tecnis Z9000 IOL for 3.0 mm, 4.0 mm, and 5.0 mm pupil diameters when decentration exceeded 0.3 mm, 0.5 mm, and 0.5 mm, respectively.

Wang and Koch⁴¹ evaluated the theoretical effect of up to 1.0 mm decentration of a negatively aspheric IOL ($-0.287 \mu\text{m}$ with a 6.0 mm pupil). Simulated implantation of the aspheric IOL in 154 eyes of 94 patients demonstrated that with a 6.0 mm pupil, the centration

required for the aspheric IOL to reduce total HOAs below the level of corneal HOAs in 50% of eyes was less than 0.47 mm. Finally, Piers et al.⁴² assessed the performance and optical limitations of standard, aspheric, and wavefront-customized IOLs using clinically verified pseudophakic eye models derived from 46 actual cataract patients. The theoretical customized IOLs could, on average, be decentered by as much as 0.8 mm, tilted more than 10 degrees, and rotated by as much as 15 degrees before their polychromatic modulation transfer function at 8 cycles/degree was reduced to less than that of a negatively aspheric or spherical control IOL.

Based solely on the correction of spherical and other HOAs, it appears inadvisable to implant a wavefront-corrected negatively aspheric IOL if centration within 0.5 to 0.8 mm cannot be achieved. Based on limited data, it appears that up to one third to one half of sulcus-fixated IOLs may exceed this level. This raises concerns about placing negatively aspheric IOLs in the sulcus unless adequate centration, such as with capsulorhexis capture, can be assured.

Should Refractive IOLs Be Placed in the Sulcus?

Accommodating, multifocal, and toric IOLs entail heightened patient expectations for reduced spectacle dependence. In this setting, unanticipated posterior capsule rupture carries the additional disappointment of patients not receiving the desired refractive IOL. This potential problem is a consideration when providing preoperative informed consent.

Clearly, accommodating IOLs such as the Crystallens (Bausch & Lomb), Tetraflex (Clarion), or Synchrony (Visiogen) are sized and designed for capsular bag fixation and should never be placed in the sulcus. Because these designs must be paired with the zonular–ciliary muscle complex to obtain maximum accommodative amplitude and stability, zonular laxity and capsulorhexis tears may also diminish their effectiveness and may increase the risk for subluxation.

Sulcus placement of currently available toric IOLs and some multifocal IOL designs is also contraindicated. The Staar Surgical toric IOL is a single-piece plate-haptic silicone IOL that requires capsular bag placement. As previously discussed, SPA IOLs such as the AcrySof toric, the single-piece ReSTOR (Alcon, Inc.), and the proposed 1-piece Tecnis multifocal also require capsular bag implantation to achieve rotational stability and centration and they should never be placed in the ciliary sulcus.

In the presence of a torn posterior capsule, placement of a 3-piece multifocal IOL in the sulcus may be an option, particularly if proper long-term

centration can be achieved with capsulorhexis capture of the optic. Alcon manufactures a 3-piece ReSTOR (MA or MN 60 D3) that can serve as a backup for the single-piece ReSTOR (SA or SN 60 D3) for sulcus placement in the event of a capsule complication. Abbott Medical Optics manufactures the 3-piece ReZoom and Tecnis multifocal IOLs. In selecting the IOL, the surgeon should consider the increased risk for refractive power surprise, IOL decentration with unwanted images, and ocular complications such as CME.

Timing and Inventory Considerations for Backup IOLs

Several factors govern the decision and timing of implanting an IOL following a capsule complication, particularly when lens material has descended into the vitreous cavity. Judicious removal of visible and accessible lens material in the anterior segment is the immediate priority, with preservation of as much capsule support as possible a secondary objective. Because of the risk for vitreous entanglement and traction, an IOL should not be implanted until a thorough anterior vitrectomy has been performed. The technique of triamcinolone staining can improve intraoperative visualization of vitreous prolapse.⁴³

Following the anterior vitrectomy, the surgeon must assess the remaining capsule support before deciding which IOL to implant and where. The options include sulcus placement with or without capsulorhexis capture or with iris or scleral suture fixation. In the absence of sufficient capsule support, the options would be an AC IOL or a sutured PC IOL.³⁰ It should be emphasized that delaying IOL implantation until a later secondary procedure may be an appropriate option. This decision may be influenced by factors such as pupil size; compromised surgical visibility from corneal edema or hyphema; excessive softening of the globe; patient discomfort and medical stability; surgeon experience and fatigue; and availability of the necessary instrumentation, sutures, and IOL.

Although infrequent, unanticipated posterior capsule rupture is a nerve-wracking complication for surgeons and staff to manage. Amidst the time pressure and stress of this situation, it is understandable that surgeons might be tempted to implant the original IOL selected, particularly if appropriate backup IOLs are not available. It is therefore important for ophthalmologists to prepare for this contingency by having backup IOLs in the operating room and having a preoperative or an intraoperative method for determining which power to use. Storage space and cost may constrain the number of backup options, but it is desirable to have one IOL that can be placed in the anterior chamber and a second that can be placed in the ciliary

sulcus available for every patient. A backup consignment of IOLs in a range of common powers may be the most convenient system. For AC IOLs, it is best to have different sizes (lengths) available and to perform the contingency IOL calculation preoperatively. Lacking this, the AC IOL power can be estimated by subtracting 3.0 to 3.5 D from the PC IOL power calculated for the capsular bag.⁴⁴

Surgeons should also consider having a consignment of backup 3-piece PC IOLs available for placement in the ciliary sulcus. The ideal parameters would be a foldable optic with low to zero spherical aberration, a rounded anterior optic edge, posteriorly angulated and thin-looped haptics, and an overall length of at least 13.5 mm. Sufficient IOL size is particularly important if capsulorhexis optic capture cannot be achieved.

Assuming that the appropriate backup IOL model and power are available, IOL implantation can proceed even if descended nuclear material will require secondary posterior segment surgery.^{45,46} If an appropriate backup IOL is not available, it may be prudent to defer IOL implantation to a later date rather than implant an IOL of improper size, power, or design.

Intraocular Lens Fixation in the Absence of Adequate Capsule Support: AC Versus PC IOL

When there is insufficient capsule structure to securely support a PC IOL, the surgeon must decide between suture fixation of a PC IOL and placement of an AC IOL. A third option in the absence of capsule support is the iris-clip IOL (Verisyse, Abbott Medical Optics, or Artisan, Ophthec BV), which can be fixated to the anterior or posterior surface of the iris.^{47,48} This IOL is not U.S. Food and Drug Administration approved for this indication in the U.S. and is generally not available in an emergent setting.

Lacking adequate capsule support, implantation of an angle-supported AC IOL is a safe and reliable option. Understandably, many surgeons have a negative bias toward AC IOLs because of complications caused by poor IOL design during the 1970s and 1980s. Whether because of sizing problems, a tendency to rotate, closed loops located in the angle, or poor material finish, many AC IOL models were associated with high rates of the UGH syndrome and pseudophakic bullous keratopathy.^{49,50}

This negative historical bias is no longer justified thanks to improved understanding of AC IOL design and size requirements.⁵⁰ Modern AC IOLs are typified by the Kelman multiflex design, which has flexible non-looped haptics that provide 4-point angle fixation. The IOL is slightly vaulted to prevent iris stromal contact, has a smooth finish, and comes in multiple

lengths to permit appropriate sizing. Clinical and experimental studies of modern open-loop AC IOLs have shown good results, with a 1% complication rate in the largest series of primary implantation involving 1000 cases.⁵¹ Ninety-eight percent of eyes in this study achieved a CDVA of at least 20/40.

Endothelial cell loss with AC IOL implantation is acceptably low at 5.3% after 1 year, which is comparable to that after phacoemulsification with an endocapsular IOL.⁵² Relative contraindications for AC IOL implantation are abnormal angle anatomy, iridocorneal adhesions, and large iris defects. In the 1998 survey of practice styles and preferences of ASCRS members,⁵³ 87% of respondents preferred AC IOLs for secondary implantation compared with 13% who preferred sutured PC IOLs.

Improper open-loop AC IOL sizing increases the risk for complications. Intraocular lenses that are too long may cause iris tuck, pupil ovalization, and associated discomfort and uveal inflammation. An AC IOL that is too short may be associated with tilting, pseudophakodonesis, iridocyclitis, and progressive endothelial loss due to intermittent corneal contact. A short AC IOL may be inclined to rotate until the haptic subluxates through an iridectomy and contacts the ciliary body. Because of the importance of correct AC IOL sizing, it is important to have several different sizes available for every common power. Adding 1.0 mm to the horizontal white-to-white corneal diameter should approximate the correct overall length. However, this may misapproximate the angle diameter in some patients. Using ultrasound biomicroscopy in 40 myopic eyes, Reinstein et al.⁵⁴ found only a weak correlation between external white to white and angle diameter ($r^2 = 0.59$; 95% confidence interval, ± 0.53 mm). Therefore, following implantation, an intraoperative assessment should be made to ensure that the implanted AC IOL is neither too long nor too short.

After the anterior chamber is completely cleared of vitreous, the pupil should be constricted with intracameral acetylcholine (Miochol-E) before an ophthalmic viscosurgical device is placed. The existing incision can be enlarged or a new incision created. Some surgeons use a plastic Sheet glide to reduce the likelihood of trapping or tucking the iris with the lead haptic. In the event of iris tuck, the haptic can be gently compressed and lifted slightly forward to release the trapped iris tissue. A peripheral iridectomy to prevent pupillary block should be performed, and the incision should be securely closed with sutures.

Ciliary sulcus fixation of PC IOLs in the absence of capsule support can be accomplished by iris or transscleral suture fixation.^{30,55-58} Late postoperative sublaxation or dislocation of the capsular bag-IOL complex in eyes with pseudoexfoliation and pro-

gressive zonular weakness may be more amenable to repair with transscleral fixation.⁵⁹ However, if the IOL resides in the sulcus and is not encapsulated by a capsular bag, iris suturing is more easily accomplished.²⁸ For scleral fixation, the haptic(s) would have to be externalized to attach the suture. This is important because frequently, it is only after sulcus IOL implantation has been accomplished that the need for supplemental suture fixation becomes apparent.

Iris suturing techniques that avoid ovalization of the pupil have been reported by several authors.^{28,29,56-58} The IOL optic is displaced anteriorly and captured by the pupil, which had been constricted with acetylcholine. The haptic(s) is sutured to the peripheral iris stroma using modifications of the McCannel technique with an external knot or with a sliding internal Siepser knot as described by Chang.²⁸ Typically, a 10-0 polypropylene suture is used with a long curved needle such as the CTC-6 (Ethicon #9090G-SD) to secure the haptics to the iris.

Suturing haptics to the sclera is probably the most difficult and time-consuming option in an emergent setting. The previously common practice of using 10-0 polypropylene suture material should be reconsidered and discouraged because many of these sutures have broken over time.^{60,61} Techniques to suture IOLs to the sclera often use special IOLs with haptic eyelets, require more robust suture material such as 9-0 polypropylene, and may require a scleral flap or Tutoplast to cover the external suture knot.⁶²⁻⁶⁵ Furthermore, ultrasound biomicroscopy has shown that blindly suturing PC IOL haptics ab externo does not reliably accomplish the desired and intended anatomic result in a high percentage of cases.⁶⁶⁻⁶⁹ In a large retrospective series of 95 eyes with ab externo transscleral suture fixation of PC IOLs,⁶⁸ complications included IOL dislocation (23%), high astigmatism (13%), transient ocular hypertension (11%), vitreous hemorrhage (5.3%), retinal detachment (4.2%), and CME (2.0%). In this same nonrandomized retrospective study, Sasahara et al.⁶⁸ reported a significantly lower complication and dislocation rate when endoscopy was used to confirm proper transscleral needle and haptic location in another 26 eyes.

The literature does not ascribe clear-cut superiority to any of these options. The American Academy of Ophthalmology Technology Assessment study³⁰ reviewed 43 papers that addressed the outcomes of IOLs implanted without adequate capsule support and carried an evidence rating of level III or higher. The study was unable to find a significant difference between iris- or scleral-sutured PC IOLs and open-loop AC IOLs. They concluded that all 3 methods were safe and effective options for IOL implantation in eyes with insufficient capsule support. More recent

retrospective studies^{70,71} suggest that flexible open-loop AC IOLs have outcomes at least equal to or better than those with transscleral suture-fixed PC IOLs.

Finally, practical concerns such as device availability and surgeon preference and experience certainly affect this decision. An important difference is that suturing a PC IOL is generally more difficult and time consuming. With a prolonged and complicated procedure and a vitrectomized soft globe, the increased risk for suprachoroidal hemorrhage may be a consideration in favor of reducing the total operative time.

New Approaches for Noncapsular IOL Fixation

Techniques for transscleral PC IOL suture fixation include *ab interno* methods and *ab externo* methods.^{55,72} In all these techniques, the suture knots must be buried, covered, or rotated to prevent conjunctival erosion and reduce the potential for endophthalmitis.^{64,65,73} Several innovative methods of transscleral PC IOL fixation have been reported.

Hoffman et al.^{74,75} recently described a refinement of their previously reported scleral tunnel technique that uses a scleral pocket initiated through a peripheral clear corneal incision. Full-thickness passage of a double-armed suture through the scleral pocket and conjunctiva with subsequent retrieval of the suture ends through the external corneal incision for tying avoids the need for conjunctival dissection, scleral cauterization, or sutured wound closure. The technique has been specifically described for a subluxated IOL–capsular bag complex but can be used for any IOL or intraocular device that requires transscleral fixation.

Agarwal et al.⁷⁶ recently reported a surgical technique that uses fibrin glue to secure the haptics of a PC IOL beneath scleral flaps in eyes with deficient or absent posterior capsules. Rather than using sutures, the tips of the haptics of a single-piece PMMA IOL are externalized through 22-gauge sclerotomies. The authors reported stable outcomes at 6 weeks postoperatively. The long-term stability of this approach is unknown.

Monteiro et al.⁷⁷ described a foldable IOL design for the ciliary sulcus, the PC 425Y 6/13.5 (Ophtec BV). This IOL features eyelets on the haptics for suture fixation, much like those on older single-piece PMMA IOLs. However, the PC 425Y 6/13.5 can be implanted through a 3.2 to 3.5 mm trapezoidal incision. In their retrospective study of 24 eyes, scleral fixation of the foldable IOL took less time and provided a better visual outcome than implantation of a rigid IOL. The mean postoperative astigmatism after 1 month was -0.88 ± 0.42 D in the foldable IOL group and -2.42 ± 0.60 D in the rigid IOL group.

Another new design described in the literature is the Ultima.⁷⁸ This IOL is a hydrophilic acrylic foldable IOL that offers 360-degree sulcus support because of its round geometry. It can be folded and inserted through a 4.0 mm clear corneal incision. The main advantages of the Ultima IOL are the lack of tilting and low amounts of surgically induced astigmatism. The IOL also provides a functional barrier that can block silicone oil from moving from the vitreous cavity into the anterior chamber.

The Sulcoflex IOL (Rayner) is designed for implantation as a piggyback IOL in the ciliary sulcus of the pseudophakic eye. Nevertheless, its design features suggest feasibility as a sulcus backup IOL if made available in the appropriate powers. It is a single-piece hydrophilic acrylic IOL that can be inserted through a 3.0 mm incision. The 6.5 mm optic and haptic edges are round. The haptic is angulated and has an undulated design to preclude rotation. A spherical monofocal version of the Sulcoflex has been implanted in the ciliary sulcus of pseudophakic eyes to correct residual ametropia (M. Amon, MD, G. Kahraman, MD, J. Schauersberger, MD, "Sulcoflex [Rayner 653L], a New IOL for Implantation in the Pseudophakic Eye: Indications and First Results," presented at the XXIV Congress of the European Society of Cataract and Refractive Surgeons, Stockholm, Sweden, September 2007. Abstract available at: <http://www.rayner.com/pdfs/Reference109.pdf>. Accessed May 3, 2009). Toric, multifocal, and aspheric versions of the IOL are also available to correct residual astigmatism, permit presbyopia correction, and reduce HOAs in pseudophakic eyes.

Adequate follow-up and study sample size remain critical issues with any new approach in technique or technology. Because many IOLs are used in an off-label fashion for sulcus fixation and because of the infrequency of this procedure, adequately large studies with sufficient long-term data do not exist. We must therefore be cautious in relying on case reports and small series to make decisions about the appropriate use of these new methods and technologies.

In conclusion, backup IOLs in appropriate powers, sizes, and designs should be available for every cataract procedure. Accommodating IOLs or SPA monofocal or refractive IOLs designed solely for capsular bag placement should not be placed in the ciliary sulcus. Because of the greater risk for tilt and decentration, IOLs with negative asphericity may increase rather than decrease HOAs when placed in the ciliary sulcus. Ophthalmic surgeons must understand the design, sizing, and IOL power parameters required for AC and PC IOL implantation when endocapsular fixation is not possible.

The development, investigation, and supply of IOLs specifically for placement in eyes lacking

adequate capsule bag support represent a clinically important endeavor for the ophthalmic industry. Although the commercial market for backup IOLs is small, we appeal to IOL manufacturers to provide surgeons and their patients with foldable PC IOLs that are appropriately sized and designed for ciliary sulcus placement.

REFERENCES

- Taskapili M, Engin G, Kaya G, Kucuksahin H, Kocabora MS, Yilmazli C. Single-piece foldable acrylic intraocular lens implantation in the sulcus in eyes with posterior capsule tear during phacoemulsification. *J Cataract Refract Surg* 2005; 31:1593–1597
- Taskapili M, Gulkilik G, Kocabora MS, Ozsutcu M, Yilmazli C, Kaya G, Kucuksahin H. Comparison of sulcus implantation of single-piece hydrophilic foldable acrylic and polymethylmethacrylate intraocular lenses in eyes with posterior capsule tear during phacoemulsification surgery. *Eur J Ophthalmol* 2007; 17:595–600
- Micheli T, Cheung LM, Sharma S, Assaad NN, Guzowski M, Francis IC, Norman J, Coroneo MT. Acute haptic-induced pigmentary glaucoma with an AcrySof intraocular lens. *J Cataract Refract Surg* 2002; 28:1869–1872
- LeBoyer RM, Werner L, Snyder ME, Mamalis N, Riemann CD, Augsberger JJ. Acute haptic-induced ciliary sulcus irritation associated with single-piece AcrySof intraocular lenses. *J Cataract Refract Surg* 2005; 31:1422–1427
- Toma HS, DiBernardo C, Schein OD, Adams NA. Recurrent vitreous hemorrhage secondary to haptic-induced chafing. *Can J Ophthalmol* 2007; 42:312–313. Available at: <http://article.pubs.nrc-cnrc.gc.ca/RPAS/rpv?hm=Hlnit&calyLang=eng&journal=cjo&volume=42&afpf=i07-018.pdf>. Accessed May 5, 2009
- Masket S, ed. Consultation section. Cataract surgical problem. *J Cataract Refract Surg* 2007; 33:1355–1361
- Uy HS, Chan PST. Pigment release and secondary glaucoma after implantation of single-piece acrylic intraocular lenses in the ciliary sulcus. *Am J Ophthalmol* 2006; 142:330–332
- Masket S. Pseudophakic posterior iris chafing syndrome. *J Cataract Refract Surg* 1986; 12:252–256
- Boutboul S, Letaief I, Lalloum F, Puech M, Borderie V, Laroche L. Pigmentary glaucoma secondary to in-the-bag intraocular lens implantation. *J Cataract Refract Surg* 2008; 34:1595–1597
- Wintle R, Austin M. Pigment dispersion with elevated intraocular pressure after AcrySof intraocular lens implantation in the ciliary sulcus. *J Cataract Refract Surg* 2001; 27:642–644
- Chang SHL, Lim G. Secondary pigmentary glaucoma associated with piggyback intraocular lens implantation. *J Cataract Refract Surg* 2004; 30:2219–2222
- Iwase T, Tanaka N. Elevated intraocular pressure in secondary piggyback intraocular lens implantation. *J Cataract Refract Surg* 2005; 31:1821–1823
- Masket S, ed. Consultation section. Cataract surgical problem. *J Cataract Refract Surg* 2005; 31:2247–2253.
- Chang WH, Werner L, Fry LL, Johnson JT, Kamae K, Mamalis N. Pigmentary dispersion syndrome with a secondary piggyback 3-piece hydrophobic acrylic lens; case report with clinicopathological correlation. *J Cataract Refract Surg* 2007; 33:1106–1109
- Kim SJ, Lee SJ, Park CH, Jung GY, Park S. Long-term stability and visual outcomes of a single-piece, foldable, acrylic intraocular lens for scleral fixation. *Retina* 2009; 29:91–97
- Amino K, Yamakawa R. Long-term results of out-of-the-bag intraocular lens implantation. *J Cataract Refract Surg* 2000; 26:266–270
- Gimbel HV, Sun R, Ferensowicz M, Anderson Penno E, Kamal A. Intraoperative management of posterior capsule tears in phacoemulsification and intraocular lens implantation. *Ophthalmology* 2001; 108:2186–2189; discussion by WJ Fishkind, 2190–2192
- Gimbel HV, DeBroff BM. Intraocular lens optic capture. *J Cataract Refract Surg* 2004; 30:200–206
- Werner L, Izak AM, Pandey SK, Apple DJ, Trivedi RH, Schmidbauer JM. Correlation between different measurements within the eye relative to phakic intraocular lens implantation. *J Cataract Refract Surg* 2004; 30:1982–1988
- Pop M, Payette Y, Mansour M. Predicting sulcus size using ocular measurements. *J Cataract Refract Surg* 2001; 27:1033–1038
- Fea AM, Annetta F, Cirillo S, Campanella D, De Giuseppe M, Regge D, Grignolo FM. Magnetic resonance imaging and Orbiscan assessment of the anterior chamber. *J Cataract Refract Surg* 2005; 31:1713–1718
- Oh J, Shin H-H, Kim J-H, Kim H-M, Song J-S. Direct measurement of the ciliary sulcus diameter by 35-megahertz ultrasound biomicroscopy. *Ophthalmology* 2007; 114:1685–1688
- Kim K-H, Shin H-H, Kim H-M, Song J-S. Correlation between ciliary sulcus diameter measured by 35 MHz ultrasound biomicroscopy and other ocular measurements. *J Cataract Refract Surg* 2008; 34:632–637
- Kusaka S, Kodama T, Ohashi Y. Condensation of silicone oil on the posterior surface of a silicone intraocular lens during vitrectomy. *Am J Ophthalmol* 1996; 121:574–575
- Porter RGB, Peters JD, Bourke RD. De-misting condensation on intraocular lenses. *Ophthalmology* 2000; 107:778–782
- Loya N, Lichter H, Barash D, Goldenberg-Cohen N, Strassmann E, Weinberger D. Posterior chamber intraocular lens implantation after capsular tear: ultrasound biomicroscopy evaluation. *J Cataract Refract Surg* 2001; 27:1423–1427
- Zarei-Ghanavati S, Gharaii H, Zarei-Ghanavati M. Simple method to evaluate adequacy of capsule for foldable intraocular lens implantation in the sulcus. *J Cataract Refract Surg* 2009; 35:222–225
- Chang DF. Siepser slipknot for McCannel iris-suture fixation of subluxated intraocular lenses. *J Cataract Refract Surg* 2004; 30:1170–1176
- McCannel MA. A retrievable suture idea for anterior uveal problems. *Ophthalmic Surg* 1976; 7(2):98–103
- Wagoner MD, Cox TA, Ariyasu RG, Jacobs DS, Karp CL. Intraocular lens implantation in the absence of capsular support; a report by the American Academy of Ophthalmology (Ophthalmic Technology Assessment). *Ophthalmology* 2003; 110:840–859
- Koeppl C, Findl O, Kriechbaum K, Buehl W, Wirtitsch M, Menapace R, Drexler W. Postoperative change in effective lens position of a 3-piece acrylic intraocular lens. *J Cataract Refract Surg* 2003; 29:1974–1979
- Suto C, Hori S, Fukuyama E, Akura J. Adjusting intraocular lens power for sulcus fixation. *J Cataract Refract Surg* 2003; 29:1913–1917
- Suto C. Sliding scale of IOL power for sulcus fixation using computer simulation. *J Cataract Refract Surg* 2004; 30:2452–2454
- Bayramlar H, Hepsen IF, Yilmaz H. Myopic shift from the predicted refraction after sulcus fixation of PMMA posterior chamber intraocular lenses. *Can J Ophthalmol* 2006; 41:78–82. Available at: <http://article.pubs.nrc-cnrc.gc.ca/RPAS/rpv?hm=Hlnit&calyLang=eng&journal=cjo&volume=41&afpf=i05-103.pdf>. Accessed May 5, 2009

35. Jung CK, Chung SK, Baek NH. Decentration and tilt: silicone multifocal versus acrylic soft intraocular lenses. *J Cataract Refract Surg* 2000; 26:582–585
36. Hayashi K, Hayashi H. Comparison of the stability of 1-piece and 3-piece acrylic intraocular lenses in the lens capsule. *J Cataract Refract Surg* 2005; 31:337–342
37. de Castro A, Rosales P, Marcos S. Tilt and decentration of intraocular lenses in vivo from Purkinje and Scheimpflug imaging; validation study. *J Cataract Refract Surg* 2007; 33:418–429
38. Legler UFC, Assia EI, Castaneda VE, Hoggatt JP, Apple DJ. Prospective experimental study of factors related to posterior chamber intraocular lens decentration. *J Cataract Refract Surg* 1992; 18:449–455
39. Baumeister M, Kohnen T. Scheimpflug measurement of intraocular lens position after piggyback implantation of foldable intraocular lenses in eyes with high hyperopia. *J Cataract Refract Surg* 2006; 32:2098–2104
40. Altmann GE, Nichamin LD, Lane SS, Pepose JS. Optical performance of 3 intraocular lens designs in the presence of decentration. *J Cataract Refract Surg* 2005; 31:574–585
41. Wang L, Koch DD. Effect of decentration of wavefront-corrected intraocular lenses on the higher-order aberrations of the eye. *Arch Ophthalmol* 2005; 123:1226–1230
42. Piers PA, Weeber HA, Artal P, Norrby S. Theoretical comparison of aberration-correcting customized and aspheric intraocular lenses. *J Refract Surg* 2007; 23:374–384
43. Burk SE, Da Mata AP, Snyder ME, Schneider S, Osher RH, Cionni RJ. Visualizing vitreous using Kenalog suspension. *J Cataract Refract Surg* 2003; 29:645–651
44. Villada JR, Sunder Raj P, Akingbehin T. Calculation of the power of anterior chamber implants. *Br J Ophthalmol* 1992; 76:303–306. Available at: <http://www.pubmedcentral.nih.gov/picrender.fcgi?artid=504263&blobtype=pdf>. Accessed May 5, 2009
45. Vajpayee RB, Sharma N, Dada T, Gupta V, Kumar A, Dada VK. Management of posterior capsule tears. *Surv Ophthalmol* 2001; 45:473–488
46. Arbisser LB, Charles S, Howcroft M, Werner L. Management of vitreous loss and dropped nucleus during cataract surgery. *Ophthalmol Clin North Am* 2006; 19(4):495–506
47. Güell JL, Barrera A, Manero F. A review of suturing techniques for posterior chamber lenses. *Curr Opin Ophthalmol* 2004; 15:44–50
48. Oetting TA, Newsom TH. Bilateral Artisan lens for aphakia and megalocornea: long-term follow-up. *J Cataract Refract Surg* 2006; 32:526–528
49. Apple DJ, Brems RN, Park RB, Norman DK, Hansen SO, Tetz MR, Richards SC, Letchinger SD. Anterior chamber lenses. Part 1: complications and pathology and a review of designs. *J Cataract Refract Surg* 1987; 13:157–174
50. Auffarth GU, Wesendahl TA, Brown SJ, Apple DJ. Are there acceptable anterior chamber intraocular lenses for clinical use in the 1990s? An analysis of 4104 explanted anterior chamber intraocular lenses. *Ophthalmology* 1994; 101:1913–1922
51. Clemente P. Langzeitverträglichkeit einer neuen VKL SP525 “Clemente Optifit” 3-Punkt-Fixation ohne Positionierungsloch: Erfahrungen bei 1000 Implantationen über einen Zeitraum von 7 1/2 Jahren. In: Kohnen T, Ohrloff C, Wenzel M, eds. 13. Kongress der Deutschsprachigen Gesellschaft für Intraokularlinsen-Implantation und refraktive Chirurgie, Frankfurt am Main, 112 und 13 März 1999. Cologne, Germany, Biermann, 2000; 421–427
52. Snellingen T, Shrestha JK, Huq F, Husain R, Koirala S, Rao GN, Pokhrel RP, Kolstad A, Upadhyay MP, Apple DJ, Arnesen E, Cheng H, Olsen EG, Vogel M. The South Asian Cataract Management Study: complications, vision outcomes, and corneal endothelial cell loss in a randomized, multi-center clinical trial comparing intracapsular cataract extraction with and without anterior chamber intraocular lens implantation. *Ophthalmology* 2000; 107:231–240
53. Leaming DV. Practice styles and preferences of ASCRS members—1998 survey. *J Cataract Refract Surg* 1999; 25: 851–859
54. Reinstein DZ, Archer TJ, Silverman RH, Rondeau MJ, Coleman DJ. Correlation of anterior chamber angle and ciliary sulcus diameters with white-to-white corneal diameter in high myopes using Artemis VHF digital ultrasound. *J Refract Surg* 2009; 25:185–194
55. Apple DJ, Price FW, Gwin T, Imkamp E, Daun M, Casanova R, Hansen S, Carlson AN. Sutured retropupillary posterior chamber intraocular lenses for exchange or secondary implantation; the 12th Annual Binkhorst Lecture, 1988. *Ophthalmology* 1989; 96:1241–1247
56. Stutzman RD, Stark WJ. Surgical technique for suture fixation of an acrylic intraocular lens in the absence of capsule support. *J Cataract Refract Surg* 2003; 29:1658–1662
57. Condon GP. Simplified small-incision peripheral iris fixation of an AcrySof intraocular lens in the absence of capsule support. *J Cataract Refract Surg* 2003; 29:1663–1667
58. Condon GP, Masket S, Kranemann C, Crandall AS, Ahmed K II. Small-incision iris fixation of foldable intraocular lenses in the absence of capsule support. *Ophthalmology* 2007; 114:1311–1318
59. Davis D, Brubaker J, Espandar L, Stringham J, Crandall A, Werner L, Mamalis N. Late in-the-bag spontaneous intraocular lens dislocation; evaluation of 86 consecutive cases. *Ophthalmology* 2009; 116:664–670
60. Assia EI, Nemet A, Sachs D. Bilateral spontaneous subluxation of scleral-fixed intraocular lenses. *J Cataract Refract Surg* 2002; 28:2214–2216
61. Price MO, Price FW Jr, Werner L, Berlie C, Mamalis N. Late dislocation of scleral-sutured posterior chamber intraocular lenses. *J Cataract Refract Surg* 2005; 31:1320–1326
62. Hannush SB. Sutured posterior chamber intraocular lenses: indications and procedure *Curr Opin Ophthalmol* 2000; 11:233–240
63. Buckley EG. Safety of transscleral-sutured intraocular lenses in children. *J AAPOS* 2008; 12:431–439
64. Oetting TA, Johnson AT, Tisseel and Tutoplast cover. *J Cataract Refract Surg* 2007; 33:2153
65. Knox Cartwright NE, Tole DM. Potential complication of fibrin sealant [letter]. *J Cataract Refract Surg* 2008; 34:881–882; reply by TA Oetting, 882
66. Pavlin CJ, Rootman D, Arshinoff S, Harasiewicz K, Foster FS. Determination of haptic position of transsclerally fixated posterior chamber intraocular lenses by ultrasound biomicroscopy. *J Cataract Refract Surg* 1993; 19:573–577
67. Manabe S-I, Oh H, Amino K, Hata N, Yamakawa R. Ultrasound biomicroscopic analysis of posterior chamber intraocular lenses with transscleral sulcus suture. *Ophthalmology* 2000; 107: 2172–2178
68. Sasahara M, Kiryu J, Yoshimura N. Endoscope-assisted transscleral suture fixation to reduce the incidence of intraocular lens dislocation. *J Cataract Refract Surg* 2005; 31:1777–1780
69. Sewelam A, Ismail AM, El Serogy H. Ultrasound biomicroscopy of haptic position after transscleral fixation of posterior chamber intraocular lenses. *J Cataract Refract Surg* 2001; 27:1418–1422
70. Donaldson KE, Gorscak JJ, Budenz DL, Feuer WJ, Benz MS, Forster RK. Anterior chamber and sutured posterior chamber intraocular lenses in eyes with poor capsular support. *J Cataract Refract Surg* 2005; 31:903–909

71. Kwong YYY, Yuen HKL, Lam RF, Lee VYW, Rao SK, Lam DSC. Comparison of outcomes of primary scleral-fixated versus primary anterior chamber intraocular lens implantation in complicated cataract surgeries. *Ophthalmology* 2007; 114:80–85
72. Eryildirim A. Knotless scleral fixation for implanting a posterior chamber intraocular lens. *Ophthalmic Surg* 1995; 26:82–84
73. Heilskov T, Joondeph BC, Olsen KR, Blankenship GW. Late endophthalmitis after transscleral fixation of a posterior chamber intraocular lens. *Arch Ophthalmol* 1989; 107:1427
74. Hoffman RS, Fine IH, Packer M, Rozenberg I. Scleral fixation utilizing suture retrieval through a scleral tunnel. *J Cataract Refract Surg* 2006; 32:1259–1263
75. Hoffman RS, Fine IH, Packer M. Scleral fixation without conjunctival dissection. *J Cataract Refract Surg* 2006; 32:1907–1912
76. Agarwal A, Kumar DA, Jacob S, Baid C, Srinivasan S. Fibrin glue-assisted sutureless posterior chamber intraocular lens implantation in eyes with deficient posterior capsules. *J Cataract Refract Surg* 2008; 34:1433–1438
77. Monteiro M, Marinho A, Salgado-Borges J, Ribeiro L, Castro-Correia J. Evaluation of a new scleral fixation foldable IOL in the absence of capsule support. *J Fr Ophthalmol* 2007; 30:791–797. Available at: <http://www.em-consulte.com/showarticlefile/132904/index.pdf>. Accessed May 5, 2009
78. Migliorati G, Brusini P. The Ultima[®] foldable scleral fixation intraocular lens: a 2-year follow-up. *Eur J Ophthalmol* 2008; 18:895–902



First author:

David F. Chang, MD

*Altos Eye Physicians, Los Altos,
California, USA*