

Incomplete fluid-air exchange technique for idiopathic macular hole surgery

Bo-Jie Hu¹, Xue-Li Du¹, Wen-Bo Li¹, Yu-Wen Chang², Xing-Dong Shi³, Teng Ma¹, Yong Wang¹, Yan-Hua He¹, Rui Niu¹, Wei-Na Cui¹

¹Department of Retina, Tianjin Medical University Eye Hospital, 251 Fukang Road, Tianjin 300384, China

²People's Hospital of Hetian District, Hetian 848000, Xinjiang Uygur Autonomous Region, China

³Department of Ophthalmology, Tianjin First Central Hospital, Tianjin 300192, China

Co-first authors: Bo-Jie Hu, Xue-Li Du and Wen-Bo Li

Correspondence to: Bo-Jie Hu. Department of Retina, Tianjin Medical University Eye Hospital, 251 Fukang Road, Tianjin 300384, China. bhu07@tmu.edu.cn

Received: 2019-04-14 Accepted: 2019-07-26

Abstract

• **AIM:** To explore an improved procedure involving incomplete fluid-air exchange for idiopathic macular hole (IMH), and the closure rate, visual function, and the visual field of macular holes (MHs) were evaluated.

• **METHODS:** This prospective randomized controlled study, included 40 eyes of 40 patients with IMH who were treated with pars plana vitrectomy and peeling of the internal limiting membrane. They were grouped by random digital table. Twenty-one eyes underwent incomplete fluid-air exchange (IFA) and 19 eyes underwent traditional complete fluid-air exchange (CFA) as the control group. Outcomes included best-corrected visual acuity (BCVA), intraocular pressure, and optical coherence tomography, light adaptive electroretinography, and visual field evaluations.

• **RESULTS:** All MHs <400 μm were successfully closed. BCVAs before and 6mo after surgery were 0.82±0.41 logMAR and 0.28±0.17 logMAR in IFA group and 0.86±0.34 logMAR and 0.34±0.23 logMAR in CFA group, respectively. The electroretinogram analysis of patients in IFA group revealed increases in b-wave amplitudes at 1, 3, and 6mo after surgery. Additionally, patients in IFA group showed an amplitude increase of 28.6% from baseline at 6mo ($P<0.05$), while no obvious improvements were noted in CFA group. Although there were no statistically significant improvements in either group, the IFA group showed a slight increase in mean sensitivity ($P>0.05$).

• **CONCLUSION:** IFA is a reliable method that offers comparable closure rate to CFA and facilitates improvements in visual function.

• **KEYWORDS:** best-corrected visual acuity; electroretinography; internal limiting membrane; macular hole; fluid-air exchange; visual field defect

DOI:10.18240/ijo.2019.10.10

Citation: Hu BJ, Du XL, Li WB, Chang YW, Shi XD, Ma T, Wang Y, He YH, Niu R, Cui WN. Incomplete fluid-air exchange technique for idiopathic macular hole surgery. *Int J Ophthalmol* 2019;12(10):1582-1588

INTRODUCTION

Idiopathic macular hole (IMH) refers the disorganization of retinal tissue in the macular region without related primary disease^[1]. Usually, the symptoms of the deterioration of central visual acuity and metamorphosis draw patients' attention first. IMH predominantly affects women over the age of 50 years^[2]. Since Kelly and Wendel^[3] first described vitrectomy to treat macular holes (MHs) in 1991, several vitrectomy-based surgical methods have been implemented for MH. At present, the standard therapeutic regimen for IMH includes pars plana vitrectomy combined with internal limiting membrane (ILM) peeling, air or gas tamponade. Combined with vitrectomy, ILM peeling and fluid-air exchange achieves a closure rate of >90% for holes smaller than 400 μm^[4-5] and an acceptable closure rate of 50%-88% for larger holes^[6].

Melberg and Thomas^[7] first reported visual field defects after MH surgery in 1995. Since then, numerous studies have confirmed this phenomenon in patients after vitrectomy for MH, including presentations of scotoma, wedge-shaped defects^[8], and arc-shaped defects^[9]. Other studies have reported the worsening of visual field loss after the surgery^[10]. Overall, the reported complication rate for vitrectomy to treat MH ranges from 7%-71%^[11-12].

The mechanism by which vitrectomy produces visual field defects is unclear. Several studies have related this phenomenon to mechanical damage of the optic nerve by extrusion needle^[13-14] and tractional damage to the peripapillary nerve fiber layer during posterior hyaloid removal^[14-15]. Alternatively, some studies have implicated high intraoperative infusion pressure and optic nerve fiber dehydration following complete fluid-air exchange in the development of visual field defects^[16-17].

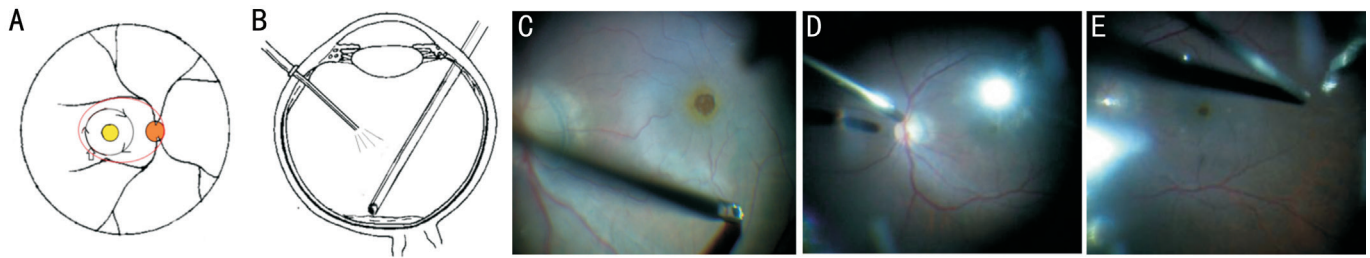


Figure 1 The incomplete fluid-air exchange procedure A and B are sketches, and C-E are intraoperative still photographs. For A, the right orange circle represents the optic disc and the yellow circle indicates the macular area. The larger black circle represents peeling of the inner limiting membrane (ILM) of approximately 2-3 papillary diameters. ILM peeling began at the inferior temporal avascular retina (wide arrow) and continued in the direction indicated by the black arrows. No additional operations were performed in the macular area after ILM peeling in the incomplete fluid-air exchange group. For incomplete fluid-air exchange (B), we left a small amount of fluid on the posterior retinal surface to avoid mechanical contact with the posterior area and especially the optic disc and the ILM sparing retina (shown as the oval region circled with a red line of A). C represents the beginning of the ILM peeling. D and E represent the operation of incomplete fluid-air exchange.

Additionally, the potential influence of impaired retinal or choroidal circulation, gas contact with the retina, and light toxicity cannot be excluded.

In the present study, we compared outcomes of an improved incomplete fluid-air exchange (IFA) technique with those of traditional complete fluid-air exchange (CFA) for IMH surgery. IFA technology was designed to improve the recovery of visual function and reduce the occurrence of visual field defects. The IFA technique leaves a small amount of fluid on the surface of the posterior retina to avoid touching the area between the superior and inferior vascular arches, especially the ILM sparing retina and optic disc.

SUBJECTS AND METHODS

Ethical Approval The study protocol followed Declaration of Helsinki and was approved by the Ethics Committee of Tianjin Medical University Eye Hospital and registered with Clinicaltrials.gov (study No.NCT02584062). Patients provided written informed consent for participation prior to study enrollment.

Study Design and Patients The study, a prospective randomized controlled study, included a total of 40 patients with diagnosed IMH. And these patients were divided into IFA group and CFA group based on the random digital table. The exclusion criteria were high myopia (≥ -6.00 diopters), axial length (AL) >26.0 mm, a history of internal eye surgery or ocular trauma, and other diseases potentially affecting visual function. Additionally, patients who were unable to maintain a prone position were also excluded.

Ophthalmologic Examination Preoperative and postoperative ophthalmic examinations were performed at baseline and 1, 3, and 6mo after surgery and included best-corrected visual acuity (BCVA) using the Snellen visual chart, intraocular pressure measurement with a non-contact tonometer, slit-lamp microscopy, indirect ophthalmoscopy, optical coherence tomography (OCT; TOPCON 3D-OCT-2000; Topcon

Corporation, Tokyo, Japan), evaluation of the 30° central field of vision (HAAG-STREIT OCTOPUS900; Haag-Streit, Koenitz, Switzerland), and light-adapted electroretinography (ERG; ESPION 0-190). Optometry and LENSTAR examinations were also performed before the surgery. MH was classified using the Gass classification.

Surgical Procedures All surgeries were performed by the same experienced surgeon with the same instruments (25G, Constellation, Alcon, Fort Worth, TX). After satisfactory retrobulbar anesthesia, we performed a standard 3-port pars plana vitrectomy. Complete removal of the posterior vitreous membrane was confirmed by triamcinolone staining. Then, the ILM surrounding the macula was peeled by approximately 2-3 papillary diameters assisted by indocyanine green (ICG; 2.5 mg/mL, 5s). ILM peeling was initiated at an avascular point located at the inferior temporal area inner retinal vascular arch and away from macula. ILM peeling was performed concentrically from the beginning point to the rim of the MH. Thereafter, patients underwent 1 of 2 fluid-air exchange procedures. In IFA group, there was no additional operation around the macula after ILM peeling. Then, we performed IFA, which involved leaving a small amount of fluid on the surface of the posterior retina. The IFA procedure is illustrated in Figure 1. The CFA group underwent complete fluid-air exchange, retaining the soft-tip of the extrusion cannula at the area of the MH for a few seconds after fluid removal. After surgery, all patients maintained a strict prone position for 48h, then a right/left lateral supine position for 2d, and gradually returned to a free position.

Patients with an obviously cloudy lens underwent combined phacoemulsification and intraocular lens (IOL) implantation. Whether a patient underwent combined cataract surgery was not influenced by group and was decided prior to group assignment.

The primary outcome after surgery was anatomic closure of the MH. Secondary outcomes included the recovery of visual

Table 1 Characteristics of the MH patients involved in the study

Parameters	IFA group	CFA group	<i>t</i>	<i>P</i>
No. (cases, male/female)	5/16	3/16	-	-
Eye (cases, phakia/pseudophakia)	21 (21/0)	19 (19/0)	-	-
Age (y, mean±SD)	67.33±4.52	63.56±6.82	2.22	0.30
Duration (d, mean±SD)	73.52±54.76	89.33±87.63	-0.69	0.18
AL (mm, mean±SD)	23.39±0.86	23.46±0.55	-0.31	0.31
MHD (µm, mean±SD)	427.00±171.86	486.53±190.93	-1.04	0.62
Stage of MH (Gass stage)				0.60
I	0	0		
II	12 (57.1%)	8 (42.1%)		
III	4 (19.0%)	4 (21.1%)		
IV	5 (23.8%)	7 (36.8%)		

IFA: Incomplete fluid-air exchange; CFA: Complete fluid-air exchange; AL: Axial length; MHD: The minimum diameter of macular hole.

function measured as BCVA, light ERG findings, and visual field defects as a complication.

Statistical Analysis A one-way ANOVA was used to assess the changes between pre- and postoperation for IFA group or CFA group. Significant effects were further investigated using Bonferroni multiple comparison tests. Student's *t*-tests were used to compare paired data between the two groups at each time point. Chi-square tests were used to analyze categorical data. All statistical analyses were performed using GraphPad Prism6 (GraphPad Software Inc., San Diego, CA, USA). The threshold for statistical significance was set at *P*<0.05. Data are expressed as the mean and standard deviation.

RESULTS

The study included a total of 40 eyes from 40 patients, with 21 eyes in IFA group and 19 eyes in CFA group. All of the eyes are phakia eyes. There were no significant differences between the groups in terms of age, disease duration, AL, and MH diameter or stage (Table 1). Four MHs (>400 µm) were not successfully closed at the time of the first postoperative follow-up; of these, two belonging to IFA group were closed after CFA, one patient from IFA group underwent an extended ILM peeling and plugging procedure, and another patient from CFA group refused further treatment. In IFA group, 12 eyes of them combined cataract and vitrectomy surgery, 2 eyes underwent cataract surgery in the follow-up period, and the other 4 eyes did not undergo cataract surgery within 6mo after operation. In CFA group, 11 eyes combined cataract and vitrectomy surgery, the other 7 eyes did not undergo cataract surgery within 6mo after operation. No patients were lost to follow-up. Therefore, we analyzed data for 36 eyes, including 18 eyes in IFA group and 18 eyes in CFA group.

Macular Hole Closure Rate The initial closure rate in IFA group was 85.71% (18/21) at 1mo after surgery; we successfully closed 100% (12/12) of holes with a diameter <400 µm and

66.7% (6/9) of holes with a diameter >400 µm. In CFA group, the initial closure rate was 94.74% (18/19) including 100% (8/8) of holes with a diameter <400 µm and 90.9% (10/11) of holes with a diameter >400 µm. There was no significant between-group difference in the initial closure rate (*P*=0.673, Chi-square test); also, the closure rate for large MHs did not have significant differences (*P*=0.089, Chi-square test). There were no cases of MH reopening during follow-up. We present a series of morphological changes in the MH examined by OCT after surgery with incomplete fluid-air exchange in Figure 2.

Visual Function

Changes in best-corrected visual acuity BCVAs expressed as logMAR values before and after surgery are shown in Figure 3. Preoperative and postoperative (1, 3, and 6mo) BCVAs were 0.82±0.41 logMAR (Snellen visual acuity, 20/100), 0.51±0.24 logMAR (Snellen visual acuity, 20/57), 0.38±0.22 logMAR (Snellen visual acuity, 20/43), and 0.28±0.17 logMAR (Snellen visual acuity, 20/36) in the IFA group and 0.86±0.34 logMAR (Snellen visual acuity, 20/111), 0.53±0.30 logMAR (Snellen visual acuity, 20/59), 0.40±0.27 logMAR (Snellen visual acuity, 20/45), and 0.34±0.23 logMAR (Snellen visual acuity, 20/41) in CFA group, respectively. The mean postoperative BCVA was significantly higher at all three follow-ups in both groups compared to the baseline (*P*<0.05). There were no significant between-group differences during follow-up.

Electroretinogram amplitudes and implicit times The b-wave ERG amplitudes and implicit times are shown in Figure 4. Preoperative and postoperative (1, 3, and 6mo) b-wave amplitudes were 112.16±20.95 mV, 119.13±35.94 mV, 132.52±19.14 mV, and 144.54±24.58 mV in the IFA group and 124.94±45.21 mV, 132.24±35.51 mV, 130.69±35.25 mV, and 129.31±34.25 mV in the CFA group, respectively. There was a

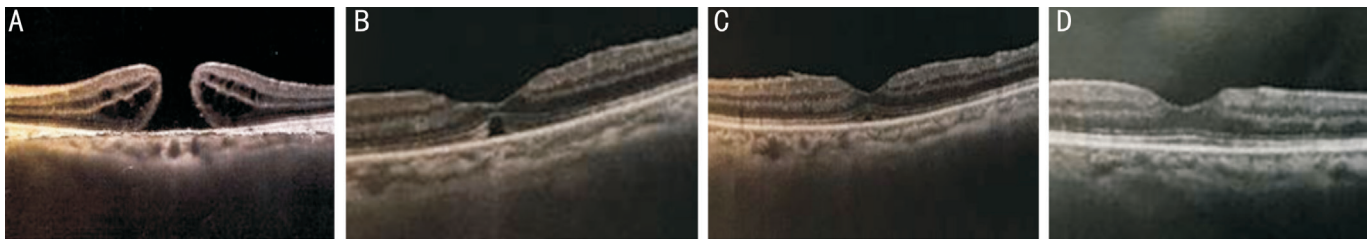


Figure 2 Morphological changes of the MH examined by OCT after surgery with incomplete fluid-air exchange technology A: The MH before surgery, showing a rupture of the whole retinal nerve fiber layer (Snellen visual acuity is finger counting); B: The MH healing like a bridge 1mo after surgery, showing a focal loss of photoreceptor cells in subcentral foveal macular (Snellen visual acuity is 20/67); C: The morphology of MH 3mo after surgery, showing an unbroken IS/OS layer and a subtle loss of the ellipsoid zone (Snellen visual acuity is 20/100 with a cloudy lens); D: Perfect healing of MH 6mo after surgery (Snellen visual acuity is 20/25 after phaco and IOL implant surgery).

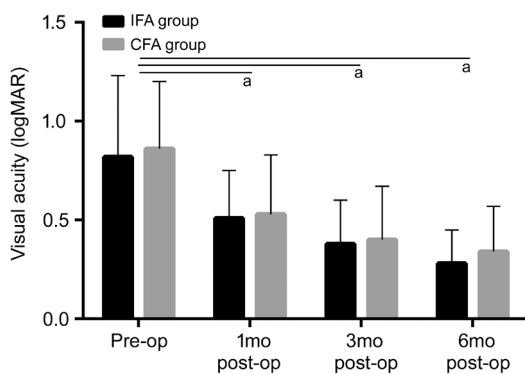


Figure 3 BCVA changes in patients after MH surgery The mean postoperative BCVA was significantly higher at all 3 follow-ups in both groups compared to the baseline. ^a $P < 0.05$ significantly different from the baseline.

tendency for higher amplitudes in the IFA group during follow-up; at 6mo, there was a significant increase in amplitude of 28.6% compared to baseline ($P < 0.05$), and amplitudes were significantly higher in the IFA group compared to the CFA group at 3 and 6mo after surgery ($P < 0.05$).

We also examined the implicit times of b-waves (Figure 4B). Preoperative and postoperative (1, 3, and 6mo) implicit times were 33.11±1.61ms, 33.61±1.04ms, 33.44±0.78ms, and 33.33±0.69ms in the IFA group and 32.44±1.85ms, 33.44±1.46ms, 33.67±1.50ms, and 33.61±1.54ms in the CFA group, respectively. Implicit times were prolonged in both groups at 1mo after surgery ($P > 0.05$). Values gradually returned to baseline over the 6-month follow-up period in the experiment group but not in the CFA group; between-group differences were statistically significant at the 3 and 6mo follow-ups ($P < 0.05$).

Changes in the visual field Changes in the central 30° visual field represented by mean sensitivity and mean deviation are shown in Figure 5. Preoperative and postoperative (1, 3, and 6mo) mean sensitivity values were 23.21±4.96, 23.19±5.22, 24.15±4.11, and 25.13±5.16 in the IFA group and 23.61±4.03, 25.17±4.00, 24.85±3.83, and 25.01±4.66 in the CFA group, respectively. Although there were no obvious improvements

in either group ($P > 0.05$), there was a non-significant increase in IFA group. There were no significant between-group differences ($P > 0.05$).

Preoperative and postoperative (1, 3, and 6mo) mean deviations of the central visual field were 4.53±2.41, 4.41±2.10, 4.26±1.74, and 4.02±1.93 in the IFA group and 4.72±2.73, 4.27±2.59, 4.07±2.60, and 4.13±2.94 in the CFA group, respectively. There were no significant changes in either group.

Ocular and Systemic Complications Totally 2 of the patients underwent cataract surgery during the follow-ups. One case occurred at 3mo after MH surgery, and the other one occurred at 5mo after vitrectomy. No systemic complications were noted during the 6mo follow-up.

DISCUSSION

The greatest difference between our study and other is that here, we improved a procedure of IFA for MH surgeries. During IFA, we leave a small amount of fluid on the surface of the posterior retina to avoid touching the ILM sparing retina and optic disc.

Here, we summarize our experience with IFA technology compared to CFA for the surgical treatment of IMH. The results indicated that closure rates were similar between the two procedures, although CFA was associated with a comparable closure rate for MHs >400 μm. The factors affecting MH closure are mainly linked to residual traction from the ILM or epiretinal membrane, shorter maintenance tamponade, poor compliance with a prone position, and large hole diameters^[18-21]. In other cases, the exact reasons for poor hole closure are unclear^[22]. Previous studies have consistently associated lower closure rates with MH >400 μm^[23-26]; therefore, we do not believe that IFA was a direct reason for poorer closure of large MHs in IFA group in this study. This notion is supported by the successful closure of stage 2/3 MHs in IFA group.

During surgery, the range of ILM peeling (2-3 papillary diameters) did not just cover the fovea; therefore, we performed full-field ERG, which is more valuable for assessing retinal function than BCVA. Both groups showed postoperative improvements

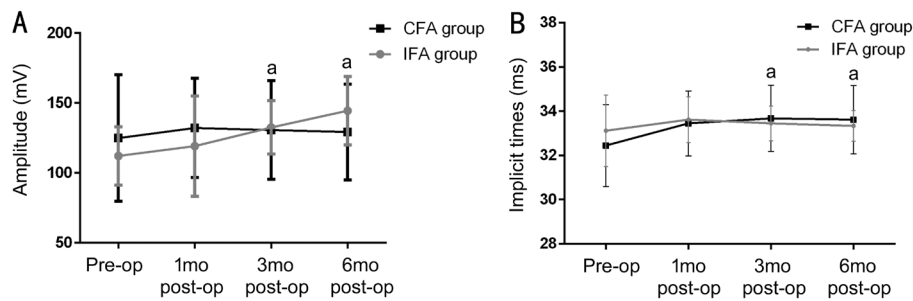


Figure 4 ERG changes over time in patients after MH surgery A: b-wave amplitudes of ERG changes. There was a tendency for higher amplitudes in the IFA group during follow-up; at 6mo, there was a significant increase in amplitude of 28.6% compared to baseline ($P<0.05$) and amplitudes were significantly higher in the IFA group compared to the CFA group at 3 and 6mo after surgery ($P<0.05$). B: Implicit times of ERG changes. Implicit times were prolonged in both groups at 1mo after surgery ($P>0.05$). Values gradually returned to baseline over the 6-month follow-up period in the experiment group but not in the CFA group; between-group differences were statistically significant at the 3 and 6mo follow-ups ($P<0.05$). ^a $P<0.05$ significant difference between two groups.

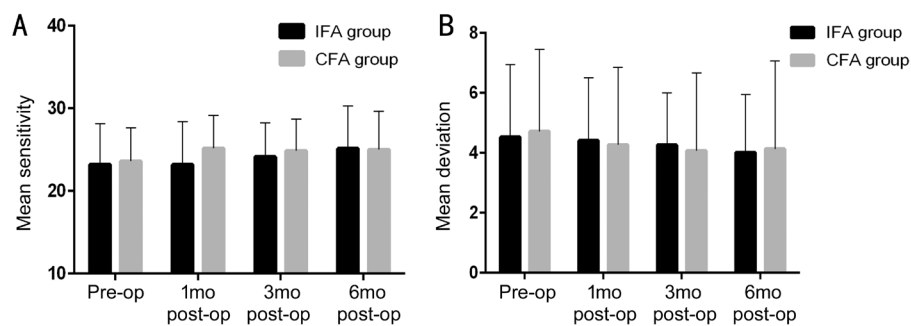


Figure 5 Mean sensitivity changes over time in patients after MH surgery A: Mean sensitivity changes. Although there were no obvious improvements in either group, there was a non-significant increase in the IFA group; however, there were no significant between-group differences. B: Mean deviation changes. There were also no significant changes in either group.

in visual function as measured by BCVA and b-wave amplitude recovery, the latter of which was better in IFA group. Some patients underwent combined phacoemulsification and IOL implantation surgery, which also improves BCVA. Although we did not utilize a uniform standard to quantify BCVA (e.g., use of cataract surgery together with posterior capsule incision in all patients), our outcome is still meaningful in a real-world context. Consistent with our study, previous studies have reported notable improvements in visual function after IMH closure^[27-29]. Improvements in BCVA and on ERG suggest that better visual function was achieved in IFA group. A previous study concluded that surgeon experience is an important factor affecting functional results and suggested that, when possible, surgeons should minimize contact with the inner retinal fiber^[30]. Moreover, improvements in BCVA were noted earlier than those in ERG findings; we found that ERG recovery occurred 6mo after vitrectomy. One possible explanation is that improvements in BCVA were attributed to substitution of the IOL as well as MH closure. Alternatively, it can be considered that electrophysiological recovery is delayed by damage to the inner retinal layer, damage during removal of the posterior vitreous cortex, and ILM. As shown by a previous study, ERG objectively reflects the electrophysiological responses of cones

and the inner retinal layer, including Müller and bipolar cells. No significant visual field defects were noted in our study. We consider that this result may have been partly related to the use of IFA, which maintained a humid environment in the macular area as well as a constant intraocular pressure of 30 mm Hg. Several studies have implicated these factors in the development of postoperative visual field defects. Intraoperative optic disc damage is chiefly associated with visual field defects. Many studies have implicated dehydration of the inner retina as the main cause^[31-32]. Vote *et al*^[33-34] used a humidifying device for fluid-air exchange to verify the relationship between retinal dehydration and the visual field. Some studies have alternatively proposed that infusion pressure fluctuation can cause visual field loss^[35-36]; however, Hirata *et al*^[36] found that infusion pressures <30 mm Hg were associated with a lower rate of visual field defects compared to 50 mm Hg. Finally, in agreement with our hypothesis, some studies have recommended minimizing direct mechanical contact to improve postoperative visual function^[37]. Yet, this hypothesis is not necessarily supported by our data. This may have been related to a short follow-up period, the inclusion of a small number of patients, or our restricted analysis of the central visual field.

The final closure rate in this study was 97.5% (39/40). Failure close MH in one patient was partly related to refusal of further treatment. All four MHs that were not closed after the initial procedure were Gass stage 4 holes with symptom durations varying from 2mo to 2y. Of note, we used sterile air tamponade in the vitreous cavity rather than an expansive gas. Thus, we speculate that larger hole diameter, shorter duration of intraocular tamponade, and potential poor compliance with a prone position were the main reasons for initial failure to close the MH. Also of note, all four diameters were >400 μm with complete posterior vitreous detachment and MH edges that were smooth, regular, round, and hydropic. In a study by Brockmann *et al*^[38], perifoveal pseudocysts on OCT were beneficial for MH closure. A possible mechanism underlying this observation is that compensatory glia cell swelling reduced the minimal diameter of larger holes^[39]. In contrast, OCT in all four cases of unclosed MHs in this study revealed pseudocysts at the IMH rim. Moreover, some studies have confirmed that the basal diameter and minimum linear diameter of the MH affect anatomical closure^[40-41], and that diameters >400 μm have lower closure rates than smaller diameters^[42-43]. The relationship between the course of disease and MH closure remains controversial^[44-45].

As mentioned above, the present study had some limitations. First, because of the limitation of our conditions, it was a great pity that we could not use more accurate multifocal electrophysiology and microperimetry examinations. We hope moreover, we included a small number of patients. A future long-term randomized controlled study is needed to verify the safety and efficacy of IFA for IMH surgery.

In conclusion, there was no significant effect of IFA technology on the success of anatomical MH closure; however, use of this technique facilitated functional recovery and reduced the occurrence of visual field defects. Given the observation of a general lower closure rate for stage 4 MHs, we recommend an IFA approach for early stage 2-3 MHs. For larger (>400 μm) MHs, IFA may also be chosen after surgeons weigh the pros and cons of this approach.

ACKNOWLEDGEMENTS

Foundation: Supported by National Natural Science Foundation of Xinjiang Autonomous Region, China (No.81460089)

Conflicts of Interest: Hu BJ, None; Du XL, None; Li WB, None; Chang YW, None; Shi XD, None; Ma T, None; Wang Y, None; He YH, None; Niu R, None; Cui WN, None.

REFERENCES

- 1 Oh H. Idiopathic macular hole. *Dev Ophthalmol* 2014;54:150-158.
- 2 Wilczyński T, Heinke A, Niedzielska-Krycia A, Jorg D, Michalska-Malecka K. Optical coherence tomography angiography features in patients with idiopathic full-thickness macular hole, before and after surgical treatment. *Clin Interv Aging* 2019;14:505-514.

- 3 Kelly NE, Wendel RT. Vitreous surgery for idiopathic macular holes. Results of a pilot study. *Arch Ophthalmol* 1991;109(5):654-659.
- 4 Williamson TH, Lee E. Idiopathic macular hole: analysis of visual outcomes and the use of indocyanine green or brilliant blue for internal limiting membrane peel. *Graefes Arch Clin Exp Ophthalmol* 2014;252(3):395-400.
- 5 Giansanti F, Tartaro R, Caporossi T, Bacherini D, Savastano A, Barca F, Rizzo S. An internal limiting membrane plug and gas endotamponade for recurrent or persistent macular hole. *J Ophthalmol* 2019;2019:6051724.
- 6 Ip MS, Baker BJ, Duker JS, Reichel E, Bauman CR, Gangnon R, Puliafito CA. Anatomical outcomes of surgery for idiopathic macular hole as determined by optical coherence tomography. *Arch Ophthalmol* 2002;120(1):29-35.
- 7 Melberg NS, Thomas MA. Visual field loss after pars plana vitrectomy with air/fluid exchange. *Am J Ophthalmol* 1995;120(3):386-388.
- 8 Arima T, Uemura A, Otsuka S, Doi N, Nakao K. Macular hole surgery-associated peripheral visual field loss. *Jpn J Ophthalmol* 1998;42(6):476-483.
- 9 Paques M, Massin P, Santiago PY, Spielmann AC, Gaudric A. Visual field loss after vitrectomy for full-thickness macular holes. *Am J Ophthalmol* 1997;124(1):88-94.
- 10 Li JN, Wang JX, Zhu XL, Yan H. Characteristics of central visual field defect after macular hole surgery. *Int J Ophthalmol* 2019;12(3):451-456.
- 11 Pendergast SD, McCuen BW 2nd. Visual field loss after macular hole surgery. *Ophthalmology* 1996;103(7):1069-1077.
- 12 Bopp S, Lucke K, Hille U. Peripheral visual field loss after vitreous surgery for macular holes. *Graefes Arch Clin Exp Ophthalmol* 1997;235(6):362-371.
- 13 Hutton WL, Fuller DG, Snyder WB, Fellman RL, Swanson WH. Visual field defects after macular hole surgery. A new finding. *Ophthalmology* 1996;103(12):2152-2158; discussion 2158-2159.
- 14 Kerrison JB, Haller JA, Elman M, Miller NR. Visual field loss following vitreous surgery. *Arch Ophthalmol* 1996;114(5):564-569.
- 15 Paques M, Massin P, Santiago PY, Spielmann AC, Gaudric A. Visual field loss after vitrectomy for full-thickness macular holes. *Am J Ophthalmol* 1997;124(1):88-94.
- 16 Hirata A, Yonemura N, Hasumura T, Murata Y, Negi A. Effect of infusion air pressure on visual field defects after macular hole surgery. *Am J Ophthalmol* 2000;130(5):611-616.
- 17 Ezra E, Arden GB, Riordan-Eva P, Aylward GW, Gregor ZJ. Visual field loss following vitrectomy for stage 2 and 3 macular holes. *Br J Ophthalmol* 1996;80(6):519-525.
- 18 Paques M, Massin P, Blain P, Duquesnoy AS, Gaudric A. Long-term incidence of reopening of macular holes. *Ophthalmology* 2000;107:760-765.
- 19 Tadayoni R, Gaudric A, Haouchine B, Massin P. Relationship between macular hole size and the potential benefit of internal limiting membrane peeling. *Br J Ophthalmol* 2006;90(10):1239-1241.
- 20 Huisinching C, McGwin G Jr. Re: Conart *et al.*: Outcomes of macular hole surgery with short-duration positioning in highly myopic eyes: a case-control study (*Ophthalmology* 2014;121:1263-1268). *Ophthalmology* 2015;122(9):e55-e56.

- 21 Bell L, Hooper R, Bunce C, Pasu S, Bainbridge J. Positioning In Macular hole Surgery (PIMS): statistical analysis plan for a randomised controlled trial. *Trials* 2017;18(1):274.
- 22 Fekrat S, Wendel RT, de la Cruz Z, Green WR. Clinicopathologic correlation of an epiretinal membrane associated with a recurrent macular hole. *Retina* 1995;15(1):53-57.
- 23 Stec LA, Ross RD, Williams GA, Trese MT, Margherio RR, Cox MS Jr. Vitrectomy for chronic macular holes. *Retina* 2004;24(3):341-347.
- 24 Schaub F, Enders P, Scholz P, Mütter PS, Fauser S, Kirchhof B. Anterior chamber aqueous flare is not a predictor for surgical closure of full-thickness idiopathic macular holes. *Eur J Ophthalmol* 2019.
- 25 Nuzzi R, Tridico F. Perspectives of autologous mesenchymal stem-cell transplantation in macular hole surgery: a review of current findings. *J Ophthalmol* 2019;2019:3162478.
- 26 Wong R, Howard C, Orobona GD. Retina Expansion Technique For Macular Hole Apposition Report 2: efficacy, closure rate, and risks of a macular detachment technique to close large full-thickness macular holes. *Retina* 2018;38(4):660-663.
- 27 Kim SH, Kim HK, Yang JY, Lee SC, Kim SS. Visual recovery after macular hole surgery and related prognostic factors. *Korean J Ophthalmol* 2018;32(2):140-146.
- 28 Kaźmierczak K, Stafiej J, Stachura J, Żuchowski P, Malukiewicz G. Long-term anatomic and functional outcomes after macular hole surgery. *J Ophthalmol* 2018;2018:3082194.
- 29 Karacorlu M, Sayman Muslubas I, Ersoz MG, Hocaoglu M, Arf S. When does visual acuity stabilize after macular hole surgery? Five-year follow-up of surgery for idiopathic macular hole. *Acta Ophthalmol* 2019;97(1):e136-e137.
- 30 Jenisch TM, Zeman F, Koller M, Märker DA, Helbig H, Herrmann WA. Macular hole surgery: an analysis of risk factors for the anatomical and functional outcomes with a special emphasis on the experience of the surgeon. *Clin Ophthalmol* 2017;11:1127-1134.
- 31 Welch JC. Dehydration injury as a possible cause of visual field defect after pars plana vitrectomy for macular hole. *Am J Ophthalmol* 1997;124(5):698-699.
- 32 Ohji M, Nao-I N, Saito Y, Hayashi A, Tano Y. Prevention of visual field defect after macular hole surgery by passing air used for fluid-air exchange through water. *Am J Ophthalmol* 1999;127(1):62-66.
- 33 Vote BJ, Russell MK, Newland A, Polkinghorne PJ. The evaluation of a humidifying device for vitreoretinal surgery. *Br J Ophthalmol* 2004;88(12):1582-1584.
- 34 Vote BJ, Newland A, Polkinghorne PJ. Humidity devices in vitreoretinal surgery. *Retina* 2002;22(5):616-621.
- 35 Kokame GT. Visual field defects after vitrectomy with fluid-air exchange. *Br J Ophthalmol* 2001;85(1):121.
- 36 Hirata A, Yonemura N, Hasumura T, Murata Y, Negi A. Effect of infusion air pressure on visual field defects after macular hole surgery. *Am J Ophthalmol* 2000;130(5):611-616.
- 37 Hasumura T, Yonemura N, Hirata A, Murata Y, Negi A. Retinal damage by air infusion during vitrectomy in Rabbit eyes. *Invest Ophthalmol Vis Sci* 2000;41(13):4300-4304.
- 38 Brockmann T, Steger C, Weger M, Wedrich A, Haas A. Risk assessment of idiopathic macular holes undergoing vitrectomy with dye-assisted internal limiting membrane peeling. *Retina* 2013;33(6):1132-1136.
- 39 Michalewska Z, Michalewski J, Nawrocki J. Continuous changes in macular morphology after macular hole closure visualized with spectral optical coherence tomography. *Graefes Arch Clin Exp Ophthalmol* 2010;248(9):1249-1255.
- 40 Shukla SY, Afshar AR, Kiernan DF, Hariprasad SM. Outcomes of chronic macular hole surgical repair. *Indian J Ophthalmol* 2014;62(7):795-798.
- 41 Unsal E, Cubuk MO, Ciftci F. Preoperative prognostic factors for macular hole surgery: Which is better? *Oman J Ophthalmol* 2019;12(1):20-24.
- 42 Chakrabarti M, Benjamin P, Chakrabarti K, Chakrabarti A. Closing macular holes with “macular plug” without gas tamponade and postoperative posturing. *Retina* 2017;37(3):451-459.
- 43 Guber J, Lang C, Valmaggia C. Internal limiting membrane flap techniques for the repair of large macular holes: a short-term follow-up of anatomical and functional outcomes. *Klin Monbl Augenheilkd* 2017;234(4):493-496.
- 44 Jaycock PD, Bunce C, Xing W, Thomas D, Poon W, Gazzard G, Williamson TH, Laidlaw DA. Outcomes of macular hole surgery: implications for surgical management and clinical governance. *Eye (Lond)* 2005;19(8):879-884.
- 45 Brockmann T, Steger C, Weger M, Wedrich A, Haas A. Risk assessment of idiopathic macular holes undergoing vitrectomy with dye-assisted internal limiting membrane peeling. *Retina* 2013;33(6):1132-1136.