



# Rhegmatogenous Retinal Detachment after Intravitreal Injection of Anti-Vascular Endothelial Growth Factor

Philip P. Storey, MD, MPH, Maitri Pancholy, BS, Turner D. Wibbelsman, BS, Anthony Obeid, MD, MPH, Daniel Su, MD, Durga Borkar, MD, Sunir Garg, MD, FACS, Omesh Gupta, MD, MBA

**Purpose:** To report the rate, risk factors, and outcomes of rhegmatogenous retinal detachment (RRD) after intravitreal injection of anti-vascular endothelial growth factor medications.

**Design:** Single-center, retrospective, consecutive review.

**Participants:** All patients receiving ranibizumab, bevacizumab, or aflibercept for neovascular age-related macular degeneration or retinal vein occlusion between October 1, 2014, and October 1, 2017.

**Methods:** The total number of eyes and injections were determined from billing codes. Rhegmatogenous retinal detachment patients were determined from billing records and confirmed with chart review.

**Main Outcome Measures:** Rate of retinal detachment and visual acuity outcomes.

**Results:** A total of 180 671 intravitreal injections in 12 718 unique patients were included. An RRD occurred in 24 patients within 3 months after injection, giving a rate of 1 RRD per 7532 intravitreal injections (0.013%) and 1 RRD per 530 patients (0.19%). No association was found between RRD risk after injection and diagnosis ( $P = 0.54$ ), physician experience ( $P = 0.23$ ), injection site ( $P = 0.41$ ), caliper use ( $P = 0.75$ ), or 31- versus 30-gauge needle use ( $P = 0.18$ ). A retinal tear was found located in the quadrant of the injection site (within 1.5 clock hours of the injection) in 15 of 24 patients (62.5%;  $P < 0.0001$ ). At the time of RRD diagnosis, the macula was attached in 9 patients (37.5%). Interventions for RRD repair included pars plana vitrectomy (PPV; 15 patients), combined scleral buckle and PPV (4 patients), pneumatic retinopexy (3 patients), and laser or cryotherapy alone (2 patients). Single-surgery success rate was 54.2%, with 54.5% of recurrent detachments caused by proliferative vitreoretinopathy. Average loss from visual acuity recorded at the visit before diagnosis of RRD was 1.0 line for macula-on detachments versus 6.8 lines for macula-off detachments ( $P = 0.027$ ) at final follow-up (average, 16.3 months).

**Conclusions:** Retinal detachment after intravitreal injection is uncommon, with a rate of approximately 1 in 7500 injections. Macular status at the time of RRD diagnosis significantly affects visual outcomes. *Ophthalmology* 2019;126:1424-1431 © 2019 by the American Academy of Ophthalmology

Over the past 2 decades, the use of intravitreal injection of anti-vascular endothelial growth factor (VEGF) inhibitors has increased dramatically. After pivotal studies established their efficacy, intravitreal injections of anti-VEGF medications have become the standard of care for neovascular age-related macular degeneration (AMD)<sup>1-4</sup> and retinal vein occlusion (RVO).<sup>5-7</sup> In the United States, in 2000, fewer than 2000 intravitreal injections were administered annually; in 2016, more than 3.2 million injections of anti-VEGF medication were administered.<sup>8</sup>

Although uncommon, the most notable complications of intravitreal injection of anti-VEGF medications are endophthalmitis, retinal detachment, retinal tears, vitreous hemorrhage, intraocular inflammation, and cataract, with the first 2 complications having the greatest risk for visual loss. Rates of endophthalmitis have been well studied, and those in the published literature range from approximately 1 in 2000 to 3000 injections.<sup>9-11</sup> Rates of rhegmatogenous retinal detachment (RRD) after intravitreal injection are less well defined. The VEGF Inhibition Study in Ocular Neovascularization (VISION) trial reported an RRD rate of

approximately 1 in 1250 injections of pegaptanib sodium, whereas the Anti-VEGF antibody for the Treatment of Predominantly Classic Choroidal Neovascularization in Age-Related Macular Degeneration (ANCHOR) and the Minimally Classic/Occult Trial of the anti-VEGF Antibody Ranibizumab in the Treatment of Vascular AMD (MARINA) reported a combined rate of 1 in 8500 injections of ranibizumab.<sup>1,12</sup> In addition, to our knowledge, the visual and anatomic outcomes of these patients after retinal detachment repair have not been reported. The purpose of this study was to evaluate the rate, risk factors, and outcomes of RRD after intravitreal injection of the anti-VEGF medications ranibizumab, bevacizumab, and aflibercept for neovascular AMD and RVO.

## Methods

### Overview

This single-center retrospective, consecutive case series was approved by the Wills Eye Hospital Institutional Review Board.

No informed consent was obtained as this was a retrospective study of de-identified patients. The study adhered to the tenets of Declaration of Helsinki. Billing records were used to identify retrospectively all cases of RRD within 90 days of a 0.05-ml intravitreal injection of ranibizumab (Genentech, Inc., San Francisco, CA), bevacizumab (Genentech), or aflibercept (Regeneron Pharmaceuticals, Tarrytown, NY) between October 1, 2014, and October 1, 2017. Billing data were used to determine the age, gender, indication for treatment, and number of intravitreal injections. Charts of all patients with retinal detachment were reviewed and the diagnosis was confirmed. Recorded data included underlying diagnosis; date of causative injection; location of injection; location of tear(s); presence of preoperative proliferative vitreoretinopathy; presence of a posterior vitreous detachment (PVD); macular status of the RRD; date and type of intervention to repair the detachment; and visual acuity before causative injection, at time of retinal detachment, at 3 and 6 months after the procedure, and at final follow-up.

### Inclusion and Exclusion Criteria

All eyes with RRD after intravitreal injection of an anti-VEGF agent for AMD or RVO were included. Eyes with a retinal detachment occurring more than 90 days after last intravitreal injection were excluded because the detachment was thought unlikely to be secondary to the injection. Although a history of diabetes was not an exclusion criterion, all patients receiving intravitreal anti-VEGF agents for diabetic retinopathy or diabetic macular edema were excluded—even those patients who did not demonstrate an RRD—because diabetic tractional retinal detachments could confound the analysis.

### Injection Technique

All intravitreal injections were performed in an office-based setting, either in a designated procedure room or in a clinical room where the examination was conducted. Eyes were prepped with a topical anesthetic and topical povidone-iodine. Injection with a 30- or 31-gauge needle was performed 3.5 to 4.0 mm from the limbus. Physicians individually determined use of subconjunctival lidocaine, use of a bladed lid speculum, conjunctival displacement before injection, caliper use, and injection site.

### Repair of Retinal Detachment

All eyes demonstrating an RRD were treated immediately based on the anatomic features of the retinal detachment and the attending physician's evaluation. The surgical approach could include cryotherapy, laser retinopexy, pneumatic retinopexy, pars plana vitrectomy, scleral buckling, or a combination thereof.

### Outcomes

The primary outcome was the rate of RRD after intravitreal injection of anti-VEGF agents. Secondary outcomes included visual acuity outcomes. Snellen visual acuity was converted to the logarithm of the minimum angle of resolution (logMAR) equivalent. Vision levels of counting fingers and hand movements were assigned visual acuity values of 1.98 and 2.28 logMAR, respectively. Clinical variables were analyzed using Excel software (Microsoft, Redmond, WA), and statistical analysis was performed using Stata software version 14 (StataCorp, College Station, TX). For all rates, 95% Poisson confidence intervals (CIs) were calculated.

## Results

### Rhegmatogenous Retinal Detachment

Over the 3-year study period, a total of 180 671 intravitreal injections (100 405 ranibizumab, 19 611 bevacizumab, and 60 655 aflibercept) were administered to 12 718 unique patients (Table 1). Average patient age was 79.9 years, and 61.4% of patients were women. Indication for injection was neovascular AMD for 146 163 injections (80.9%), branch RVO for 18 474 injections (10.2%), and central RVO for 16 016 injections (8.9%). Overall, 93% of patients had at least 3 months of follow-up, and 83% of patients had at least 1 year of follow-up.

A total of 24 patients demonstrated RRDs, giving an overall rate of 1 RRD per 7692 injections (0.013%; 95% CI, 0.009%–0.020%) and 1 RRD per 530 patients (0.19%; 95% CI, 0.12%–0.28%; Table 1). Of patients in whom RRD developed after intravitreal injection, average patient age was 75.7 years (range, 46.9–93.7 years), and the primary diagnosis was neovascular AMD for 20 patients, central RVO for 3 patients, and branch RVO for 1 patient. Patients received an average of 20 injections before detachment (range, 1–62 injections), which presented an average of 31.3 days after injection (range, 6–70 days). Ten patients were phakic, whereas 14 were pseudophakic. Four patients (17.4%) with RRDs after intravitreal injection showed proliferative vitreoretinopathy before surgery. The average length of follow-up of patients in whom RRD developed was 16.3 months, with a range of 2.3 to 39.0 months. Nearly all patients in whom RRD developed after intravitreal injection had at least 3 months of follow-up. No patients had a prior history of retinal detachment or retinal tear or of surgical intervention in the affected eye between the intravitreal injection and development of the RRD. Individual patient characteristics are described in Table 2.

Univariate analysis was performed to evaluate patient and injection characteristics associated with RRD after intravitreal injection. No association was found with a patient's diagnosis and the risk of RRD ( $P = 0.54$ ). The number of prior injections a patient received in the study period was not found to be associated significantly with the development of an RRD (chi-square test for the number of injections: 0–5 vs. 6–10 vs. 11–15 vs. 16–20 vs. 21+,  $P = 0.28$ ). Among patients in whom RRD developed after intravitreal injection, 25% (6/24) were women compared with 61.4% of all patients included in the study ( $P < 0.001$ ). Younger age was associated with a significantly higher risk of RRD after intravitreal injection ( $P = 0.01$ , continuous variable logistic regression). Medication type also was associated with RRD risk. The rate of RRD for ranibizumab was 6 in 100 405 injections (1 per 16 734 injections [0.006%]; 95% CI, 0.002%–0.013%), that for bevacizumab was 5 in 19 611 injections (1 per 3922 injections [0.025%]; 95% CI, 0.008%–0.059%), and that for aflibercept was 13 in 60 655 injections (1 per 4666 injections [0.021%]; 95% CI, 0.011%–0.037%;  $P = 0.010$ ). We found no difference in the rate of detachment with the use of a 30-gauge versus a 31-gauge needle ( $P = 0.18$ ).

A total of 36 physicians administered intravitreal injections in this study. Univariate analysis of physician and injection characteristics was performed for the 19 physicians who administered at least 1000 intravitreal injections. We found no difference in the rate of RRD after intravitreal injection between individual physicians ( $P = 0.48$ , chi-square test). The number of years practicing as a vitreoretinal physician was not associated with the risk of RRD after injection ( $P = 0.23$ ). As routine practice, physicians chose to administer intravitreal injections inferotemporally ( $n = 17$ ), superotemporally ( $n = 1$ ), superiorly ( $n = 1$ ), and inferonasally

Table 1. Intravitreal Injections of Anti-Vascular Endothelial Growth Factor Agents and Rhegmatogenous Retinal Detachment Rates

No. of Intravitreal Injections	No. of Patients	Average Age (yrs)	Gender (% Female)	No. of Rhegmatogenous Retinal Detachment Cases	Rhegmatogenous Retinal Detachment Rate per Injection	Rhegmatogenous Retinal Detachment Rate per Patient
180671	12718	79.9	61.4	24	1 in 7532 (0.013%; 95% CI, 0.009%–0.020%)	1 in 530 (0.19%; 95% CI, 0.12%–0.28%)

CI = confidence interval.

( $n = 1$ ). (Note: One physician chose an inferotemporal approach for right eyes and an inferonasal approach for left eyes.) We found no correlation between the choice of injection site and the risk of detachment ( $P = 0.41$ ). Although all physicians injected 3.5 to 4.0 mm posterior to the limbus, 3 physicians consistently used calipers or a 1-ml syringe to measure the injection site, whereas other physicians did not measure. We found measuring with calipers or a syringe did not have any effect on the rate of RRD after injection ( $P = 0.75$ ).

Relevant clinical and demographic variables then were selected for multivariate logistic regression analysis to assess risk factors for RRD development after intravitreal injection, which included age, gender, diagnosis, and medication agent (Table 3). Younger age was found to be associated with higher risk of RRD development (odds ratio, 0.96 per year of older age; 95% CI, 0.93–1.00;  $P = 0.048$ ). Male gender also was associated with significantly higher rates of detachment (odds ratio, 4.39; 95% CI, 1.72–11.20;  $P = 0.002$ ). Medication type also was associated with development of an RRD, with higher rates for aflibercept (odds ratio, 2.75; 95% CI, 1.03–7.30;  $P = 0.04$ ) and bevacizumab (odds ratio, 3.71; 95% CI, 1.12–12.25;  $P = 0.03$ ) compared with ranibizumab. Given that all bevacizumab injections were administered with a 31-gauge needle, whereas the 2 other medications were administered with a 30-gauge needle, needle gauge was omitted from the model to avoid collinearity.

The site of the intravitreal injection before development of the retinal detachment was superior for 7 injections, inferotemporal for 15 injections, and inferonasal for 2 injections. A tear was found located in the quadrant of the injection site (within 1.5 clock hours of the injection) in 15 of 24 patients (62.5%;  $P < 0.0001$ ). A PVD was documented in 18 patients (75.0%) before development of the RRD after intravitreal injection. Of the 6 patients without a PVD, 2 patients showed a full PVD present at the time the RRD was identified.

Interventions to repair the retinal detachment included pars plana vitrectomy (PPV; 15 patients), combined scleral buckle and PPV (4 patients), pneumatic retinopexy (3 patients), and laser therapy or cryotherapy alone (2 patients). Of patients undergoing a primary PPV, 12 received gas tamponade and 3 received silicone oil. The 4 patients treated with combined scleral buckle and PPV received gas tamponade. Overall, a single intervention successfully treated the RRD in 13 of 24 patients (54.2%). The single-surgery success rate for patients treated with a PPV alone was 46.7% (7/15 patients), that for combined scleral buckle plus PPV was 100% (4/4), that for pneumatic retinopexy was 33.3% (1/3 patients; 1 treated with additional laser, 1 treated with PPV), and that cryotherapy or laser retinopexy was 50% (1/2 patients; 1 treated with additional laser). For patients treated with PPV alone, the success rate with gas tamponade was 58.3% (7/12 patients) and 0% with silicone oil (0/3 patients). Causes of recurrent detachment were PVR (6/11 [54.5%]) and new breaks (5/11 [45.5%]). Overall, 25% of patients (6/24) with an RRD secondary to intravitreal injection demonstrated PVR.

At the time of diagnosis of the detachment, the macula was attached in 9 patients (37.5%) and was detached in 15 patients (62.5%). Interventions to repair macula-on detachments included 4 patients undergoing PPV with gas, 2 patients undergoing scleral buckle plus PPV, 2 patients undergoing laser therapy or cryotherapy, and 1 patient undergoing pneumatic retinopexy. Interventions to repair macula-off detachments included 8 patients undergoing PPV with gas, 3 patients undergoing PPV with silicone oil, 2 patients undergoing scleral buckle plus PPV, and 2 patients undergoing pneumatic retinopexy. The single-surgery success rate for macula-on detachments was 66.7% (6/9 patients) compared with 46.7% (7/15 patients) for macula-off detachments ( $P = 0.34$ ).

After surgery, 18 patients (75.0%) continued receiving intravitreal injections for the underlying disease. In patients who continued injections, treatment was delayed in 50% of patients compared with the prior treatment interval, with an average delay of 12.6 weeks (range, 0–76.9 weeks). For patients with a delay in treatment, 55.6% (10 patients) showed worsening macular edema. Six patients (25%) did not continue intravitreal injection after treatment of the RRD, only 1 of whom showed worsened macular edema, but did not resume intravitreal injection because of a lack of visual symptoms and poor visual prognosis. All patients with silicone oil placed at the primary procedure (3 patients) stopped intravitreal injections after surgery without recurrence of macular edema. Two patients underwent silicone oil placement during a subsequent procedure for treatment of RRD, and both of these patients resumed intravitreal injection at the full dose.

## Visual Acuity Outcomes

Overall, average visual acuity before development of the RRD was 0.79 logMAR (approximate Snellen equivalent, 20/125), which decreased to 1.41 logMAR (Snellen equivalent, 20/500) at the time of RRD diagnosis. Eleven patients (45.8%) demonstrated baseline visual acuity of 20/200 or worse before an RRD developed. Average visual acuity after repair of the detachment was 1.30 logMAR (Snellen equivalent, 20/400) at 3 months and 1.25 logMAR (Snellen equivalent, 20/400) at final follow-up (Fig 1). At final follow-up, the average change in visual acuity was a loss of 4.6 lines compared with baseline vision but a gain of 1.6 lines compared with vision at the time of RRD diagnosis.

Macular status at the time of RRD diagnosis affected visual outcomes. Before the detachment developed, baseline visual acuity was similar for patients who demonstrated macula-on detachments (0.74 logMAR; approximate Snellen equivalent, 20/100) and macula-off detachments (0.82 logMAR; Snellen equivalent, 20/125;  $P = 0.80$ ). At time of diagnosis of the RRD, average acuity for a macula-on detachment was 0.88 logMAR (Snellen equivalent, 20/160) compared with 1.73 logMAR (Snellen equivalent, 20/1000) for macula-off detachments ( $P = 0.020$ ). Average visual acuity 3 months after repair of macula-on detachments was 0.91 logMAR (Snellen equivalent, 20/160) versus 1.54 logMAR (Snellen equivalent, 20/630) for macula-off detachments

Table 2. Characteristics and Visual Outcomes of Patients in Whom Rhegmatogenous Retinal Detachment Developed after Intravitreal Injection

Patient No.	Drug	Lens Status	No. of Injections before Rhegmatogenous Retinal Detachment Development	Location of Injection (Clock Hours)	Location of Tears (Clock Hours)	Macula Status at Time of Diagnosis	Initial Procedure	Single-Surgery Success	Secondary Procedure	Visual Acuity				Length of Follow-up (mos)
										Baseline	Rhegmatogenous Retinal Detachment Presentation	3 Months	Final	
1	Aflibercept	PCIOL	11	7:30	1, 1:30, 6, 6:30, 4:30	Off	PPV with C <sub>3</sub> F <sub>8</sub>	Yes	NA	20/50	20/400	20/200	20/200	7.1
2	Ranibizumab	PCIOL	21	7:30	10:30	On	PPV with C <sub>3</sub> F <sub>8</sub> + SB	Yes	NA	CF	CF	CF	CF	3.1
3	Aflibercept	PCIOL	23	7:30	9, 12	Off	PPV with SF <sub>6</sub>	No	PPV with SO	20/40	20/400	CF	CF	12.0
4	Ranibizumab	Phakic	9	7:30	11, 6	On	Cryotherapy	Yes	NA	CF	CF	CF	CF	34.4
5	Aflibercept	PCIOL	34	12	11	On	Pneumatic	Yes	NA	20/25	20/40	20/40	20/30	16.1
6	Ranibizumab	PCIOL	25	7:30	7:30	Off	PPV with SF <sub>6</sub>	No	PPV with SO	20/400	20/100	CF	20/200	25.4
7	Ranibizumab	Phakic	32	8	8	On	PPV with SF <sub>6</sub>	No	PPV with SO	20/200	CF	20/200	20/400	33.5
8	Bevacizumab	PCIOL	3	1:30	1:30, 2	Off	PPV with C <sub>3</sub> F <sub>8</sub>	Yes	NA	CF	CF	HM	HM	5.5
9	Aflibercept	Phakic	41	12	12	Off	Pneumatic	No	Laser	20/200	HM	20/100	20/200	22.3
10	Bevacizumab	Phakic	1	7:30	10:30	On	PPV with SF <sub>6</sub>	Yes	NA	20/60	20/50	20/70	20/25	15.0
11	Aflibercept	PCIOL	5	12	7, 10:30	Off	PPV/SO	No	PPV with SO	20/400	CF	CF	CF	14.0
12	Aflibercept	PCIOL	62	7:30	3	Off	PPV with C <sub>3</sub> F <sub>8</sub>	Yes	NA	20/400	CF	CF	20/400	7.6
13	Aflibercept	Phakic	7	7:30	12, 10	Off	PPV with C <sub>3</sub> F <sub>8</sub>	No	PPV with SO	20/200	CF	CF	CF	12.3
14	Aflibercept	Phakic	20	7:30	9	On	PPV with SF <sub>6</sub> + SB	Yes	NA	20/60	20/60	20/400	20/400	3.2
15	Aflibercept	Phakic	16	7:30	11	Off	PPV with SF <sub>6</sub> + SB	Yes	NA	20/60	HM	N/A	CF	2.3
16	Aflibercept	PCIOL	13	4:30	11, 11:30	Off	PPV with C <sub>3</sub> F <sub>8</sub>	Yes	NA	20/200	20/200	20/200	20/200	20.1
17	Aflibercept	Phakic	62	7:30	10, 11	Off	PPV with C <sub>3</sub> F <sub>8</sub> + SB	Yes	NA	20/50	CF	20/400	CF	7.5
18	Ranibizumab	PCIOL	10	4:30	8, 9:30	On	PPV with SF <sub>6</sub>	Yes	NA	20/30	20/50	20/60	20/30	22.5
19	Ranibizumab	PCIOL	4	12	11, 5	Off	PPV/SO	No	PPV with SO	20/40	HM	CF	HM	25.7
20	Bevacizumab	PCIOL	20	12	6, 8	On	PPV with C <sub>3</sub> F <sub>8</sub>	No	PPV with SO	20/40	20/30	20/60	20/60	3.9
21	Aflibercept	PCIOL	27	7:30	8, 9, 12, 2	Off	PPV/SO	No	PPV with SO	20/40	HM	CF	CF	11.8
22	Aflibercept	PCIOL	8	12	10:30, 5	On	Laser	No	Laser	20/30	20/30	20/25	20/25	23.0
23	Bevacizumab	Phakic	4	12	12, 1	Off	PPV with SF <sub>6</sub>	Yes	NA	20/200	HM	20/200	20/60	39.0
24	Bevacizumab	Phakic	12	7:30	8	Off	Pneumatic	No	PPV with C <sub>3</sub> F <sub>8</sub>	20/30	20/40	20/20	20/30	24.9

CF = counting fingers; C<sub>3</sub>F<sub>8</sub> = perfluoropropane; HM = hand movements; NA = None; PCIOL = posterior chamber intraocular lens; PPV = pars plana vitrectomy; RRD = rhegmatogenous retinal detachment; SB = scleral buckle; SF<sub>6</sub> = sulfurhexafluoride; SO = silicone oil.



Table 3. Univariate and Multivariate Analysis of Potential Risk Factors and Their Association with the Development of a Rhegmatogenous Retinal Detachment after Intravitreal Injection of Anti-Vascular Endothelial Growth Factor Agents

Variable	Rhegmatogenous Retinal Detachments after Intravitreal Injection (%; 95% CI)	Univariate Analysis		Multivariate Analysis	
		Odds Ratio (95% CI)	P Value	Odds Ratio (95% CI)	P Value
Gender					
Female	6 in 114 490 (0.005%; 0.002%–0.011%)	Reference	Reference	Reference	Reference
Male	18 in 66 181 (0.027%; 0.016%–0.043%)	5.19 (2.06–13.08)	<0.001	4.39 (1.72–11.20)	0.002
Age (yrs)					
At injection	Average age at RRD, 75.7±10.1 yrs	0.96 (0.93–0.99)	0.01	0.96 (0.93–1.00)	0.048
Diagnosis					
nAMD	20 in 146 163 (0.014%; 0.008%–0.021%)	Reference	Reference	Reference	Reference
BRVO	1 in 18 474 (0.005%; 0.000%–0.030%)	0.40 (0.05–2.95)	0.37	0.24 (0.03–1.88)	0.18
CRVO	3 in 16 016 (0.019%; 0.004%–0.055%)	1.37 (0.41–4.61)	0.61	0.69 (0.19–2.54)	0.58
Myopic CNV*	0 in 13 (0%; 0.0%–28.4%)	<0.001	0.99	<0.001	0.99
Agent					
Ranibizumab	6 in 100 405 (0.006%; 0.002%–0.013%)	Reference	Reference	Reference	Reference
Aflibercept	13 in 60 655 (0.021%; 0.011%–0.037%)	3.59 (1.36–9.44)	0.01	2.75 (1.03–7.30)	0.04
Bevacizumab	5 in 19 611 (0.025%; 0.008%–0.059%)	4.27 (1.30–13.98)	0.02	3.71 (1.12–12.25)	0.03

BRVO = branch retinal vein occlusion; CNV = choroidal neovascularization; CI = confidence interval; CRVO = central retinal vein occlusion; nAMD = neovascular age-related macular degeneration; RRD = rhegmatogenous retinal detachment.

\*Because of the small sample size, a confidence interval for the odds ratio is unavailable.

( $P = 0.044$ ). At final follow-up, macula-on detachments demonstrated an average visual acuity of 0.84 logMAR (Snellen equivalent, 20/125) compared with 1.49 logMAR (Snellen equivalent, 20/630) for macula-off detachments ( $P = 0.060$ ). At final follow-up, the average loss from baseline acuity was 1.0 lines for macula-on detachments versus 6.8 lines for macula-off detachments ( $P = 0.027$ ). At final follow-up, macula-on detachments gained 0.3 lines of vision from the time of RRD diagnosis, whereas macula-off detachments gained 2.3 lines of vision ( $P = 0.35$ ).

Visual outcomes were evaluated by surgical intervention. At final follow-up, average loss in visual acuity compared with baseline acuity before RRD was 4.8 lines for PPV with any tamponade agent ( $n = 15$ ), which was 2.3 lines for patients who underwent PPV with gas ( $n = 12$ ) and 14.5 lines for patients who underwent PPV with silicone oil ( $n = 3$ ). Average loss of vision at final follow-up compared with baseline acuity was 9.8 lines for patients who underwent scleral buckle plus PPV ( $n = 4$ ), 0 lines for patients who underwent pneumatic retinopexy ( $n = 3$ ), and 0 lines for patients who underwent laser therapy or cryotherapy ( $n = 2$ ). Average loss of vision from baseline to final follow-up was not significantly different between interventions (PPV with gas vs. pneumatic retinopexy,  $P = 0.27$ ; PPV with silicone oil vs. pneumatic retinopexy,  $P = 0.068$ ; PPV vs. scleral buckle plus PPV,  $P = 0.29$ ).

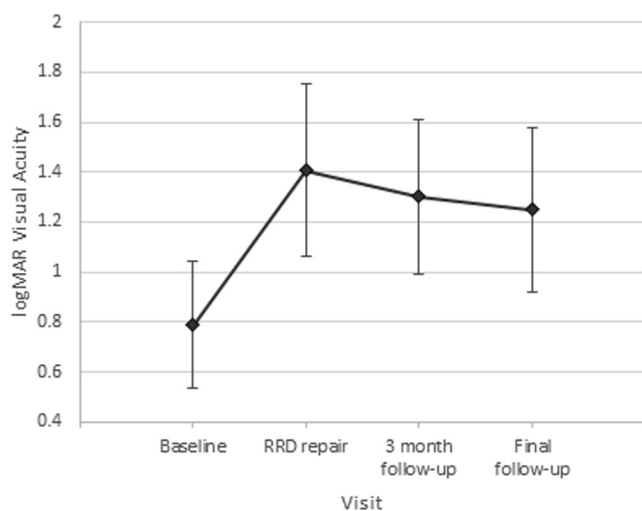
Visual outcomes were evaluated by baseline lens status. Visual acuity before an RRD developed was no different between phakic and pseudophakic patients (0.80 logMAR vs. 0.78 logMAR;  $P = 0.94$ ). After RRD repair, average visual acuity remained similar at 3 months (phakic patients, 1.18 logMAR vs. pseudophakic patients, 1.39 logMAR;  $P = 0.48$ ) and final follow-up (phakic patients, 1.23 logMAR vs. pseudophakic patients, 1.27 logMAR;  $P = 0.91$ ).

## Discussion

Rhegmatogenous retinal detachment remains uncommon, although reported rates of RRD have varied widely between

studies. In the VISION Study, which used the anti-VEGF medication pegaptanib with 27-gauge needles, 6 detachments were reported after 7545 injections (0.08%).<sup>13</sup> In the ANCHOR and MARINA trials, the reported rates of RRD after intravitreal ranibizumab with a 30-gauge needle were 2 in 5921 injections (0.03%) and 0 in 10 443 injections, respectively.<sup>1,2</sup> In the VEGF Trap-Eye: Investigation of Efficacy and Safety in Wet AMD (VIEW) studies, which also used 30-gauge needles, the reported rates of RRD at week 96 were 3 in 595 eyes (0.5%) for 0.5 mg ranibizumab every 4 weeks and 2 in 601 eyes (0.3%) for 0.5 mg aflibercept every 4 weeks.<sup>14</sup> In the Comparison of Age-Related Macular Degeneration Treatments Trials, RRD rates were 0 in 5449 ranibizumab injections and 3 in 5508 bevacizumab injections with 30-gauge needles.<sup>4</sup> Rates of RRD after intravitreal injection in retrospective studies have varied from 0% to 9.5%, although most studies included fewer than 10 000 injections.<sup>1,13,15–18</sup> In a retrospective study of more than 35 000 injections with 30-gauge needles, a rate of 1 in 7188 injections (0.013%) was reported.<sup>19</sup> In this study of more than 180 000 intravitreal injections of the anti-VEGF medications ranibizumab, bevacizumab, and aflibercept for neovascular AMD and RVO, we report a rate of RRD of approximately 1 in 7500 injections and 1 in 530 patients.

Female gender was associated with a lower risk of RRD after intravitreal injection. Although women accounted for 61% of patients in our study, only 25% of patients in whom an RRD developed after intravitreal injection were women. In population-based studies, men have been shown to have higher rates of RRD.<sup>20</sup> However, it remains unclear whether any mechanism by which a gender difference for RRD development after intravitreal injection could exist. Additionally, younger age was found to be associated with a higher risk of RRD after intravitreal injection. For each



**Figure 1.** Graph showing visual acuity outcomes of eyes in which rhegmatogenous retinal detachment developed after intravitreal injection. Error bars represent 95% confidence intervals. logMAR = logarithm of the minimum angle of resolution; RRD = rhegmatogenous retinal detachment.

year of older age, the odds of a detachment decreased slightly (odds ratio, 0.96), which was statistically significant. In population studies, older age has been associated with a higher risk of RRD development, with the highest risk reported in patients older than 60 years.<sup>21</sup> It is unclear how younger age might be associated with a higher risk of detachment after intravitreal injection, and this result should be interpreted with caution.

We found that the rate of RRD differed among anti-VEGF medications, with a rate as high as approximately 1 in 3900 injections for bevacizumab and as low as 1 in 16000 injections for ranibizumab. It is unclear by what mechanism rates could vary among medications. At our practice, bevacizumab is administered from prefilled syringes from a compounding pharmacy with 31-gauge needles, whereas ranibizumab and aflibercept are administered with 30-gauge needles from vials or prefilled syringes direct from the manufacturer. It is possible that the needle gauge could impact detachment rates, although arguments exist to support the safety of either a 31- or 30-gauge needle. Some experimental studies have shown that a 31-gauge needle requires almost twice as much mechanical force to penetrate tissue as 27- or 30-gauge needles, which could impact tractional forces from the vitreous gel or accuracy of needle placement on the sclera.<sup>22,23</sup> However, a smaller needle creates a smaller puncture wound, which may be less likely to create tears or vitreous prolapse. When we directly compared RRD rates with 31-gauge versus 30-gauge needles, we found no significant difference between the needles. Although we did find medication type to be associated with detachment rates, we caution against over-interpretation of these results because this could be a chance finding; we know of no mechanism by which one anti-VEGF medication might lead to increased rates of detachment over another.

The location of an intravitreal injection is important. If an injection is too far anterior, the crystalline lens or ciliary

body may be damaged.<sup>24</sup> However, if the location is too posterior, the needle may violate the vitreous base, damage the ora serrata, or even penetrate the retina.<sup>25</sup> The ora serrata begins at different distances from Schwalbe's line based on the position on the eye: approximately 6.1 mm superiorly, 6.5 mm laterally, 6.2 mm inferiorly, and 5.7 mm laterally.<sup>26</sup> A retinal detachment after intravitreal injection may occur through a direct tear from needle penetration through the retina, tractional forces induced with vitreous prolapse through the injection site, or development of a PVD. We attempted to correlate the location of intravitreal injection with retinal tears found after development of the RRD. Physicians at our practice place intravitreal injections 3.5 to 4.0 mm from the corneal limbus in the quadrant of the physician's choice. Most physicians do not measure with calipers before injection. Although 60% of eyes demonstrated tears within 1.5 clock hours of the injection site, the injection location did not explain all detachments. We found no difference in the rate of RRD after intravitreal injection among physicians. We also found no association between RRD rates and physician experience, injection site, caliper use, or 31- versus 30-gauge needles.

An intravitreal injection may lead to detachment of the posterior vitreous from the retina, which may cause retinal breaks and detachment. However, this mechanism may account for only a small number of detachments in our study. Although development of a PVD likely plays a role in the development of an RRD after intravitreal injection for some patients, 75% of patients in our study already showed a PVD present before an RRD developed. Of the patients without a PVD present before the development of a retinal detachment, one third were found to have a full PVD present at the time the RRD was identified.

Unlike endophthalmitis after injection, where the causality is usually not in doubt, RRD may not have been caused by an intravitreal injection. Although annualized rates of RRD have varied across studies and populations, a review reported that the highest rate of RRD was found in the 60- to 69-year-old age group, with annualized rates varying between 19 and 27 per 100 000.<sup>21</sup> Based on this estimate, our study of nearly 13 000 unique patients over a 3-year period could expect between 7 and 10 retinal detachments without the added risk of intravitreal injection. Because our study reported 24 RRDs, the attributable risk of intravitreal injection may be 30% to 40% lower than our reported rates, which would give estimated attributable risk rates as low as 1 RRD per 12 900 injections or 1 RRD per 900 patients. It should be noted that our study included only RRDs that occurred within 90 days of intravitreal injection to minimize the inclusion of detachments that were not caused by the injection. However, our estimates do not account for a baseline population risk, and the attributable risk of RRD from intravitreal injection most likely is lower than our reported rates.

Patients in our study in whom an RRD developed were treated with a range of interventions. Most underwent surgery with PPV or combination scleral buckle plus PPV, although approximately 20% were treated with pneumatic retinopexy or with laser therapy or cryotherapy alone. No

significant difference in single-surgery success rates was found between interventions, although the number of patients within each surgical subgroup was limited. Although all 4 patients in the combined PPV plus scleral buckle arm showed initial surgery success, this study is underpowered to detect a difference in surgical approach. The failure rate was relatively high, with almost half of patients requiring additional interventions, most commonly for redetachment secondary to PVR. Overall, in one quarter of patients who demonstrated an RRD after intravitreal injection, PVR developed, the reason for which remains unclear. It is possible that a tear caused by the intravitreal injection could lead to retinal pigment epithelium cell exposure, causing a cascade of cellular events triggering PVR formation, or that eyes with RVO or AMD may have increased expression of proinflammatory cytokines. Furthermore, patients sought treatment with an RRD an average of 1 month after intravitreal injection, and nearly 20% of patients showed preoperative PVR. Although it is unclear when the RRD developed initially, it is possible that the relatively poor baseline visual acuity—approximately half of patients showed vision of 20/200 or worse—resulted in late discovery of the RRD, leading to PVR and worse outcomes. Although the single-surgery success rate is low, it should be emphasized that the total number of patients is small and that there is no control group of patients undergoing RRD repair at the same institution without the risk factor of intravitreal injection. Considering the heterogeneity of RRD patients, the limited number of patients likely is inadequate to draw conclusions about the nature of RRD in intravitreal injection patients.

Visual acuity outcomes primarily depended on the macular status of the retinal detachment at the time of diagnosis. Before development of the RRD, average visual acuity was approximately 20/125, with no significant difference between patients who demonstrated macula-on versus macula-off detachments. At the time of RRD diagnosis, approximately 40% of patients demonstrated a macula-on detachment. At final follow-up, average vision for macula-on detachments was approximately 20/125 compared with 20/630 for macula-off detachments. At final follow-up, macula-on detachments showed a loss of an average of 1 line of vision, compared with 7 lines for macula-off detachments. We found no difference in visual outcomes based on surgical intervention, although as previously noted, subgroup analysis is limited.

Limitations of the study include its retrospective, cross-sectional design. Patients who demonstrated a retinal detachment may have followed up with providers outside our practice, although no such cases are known. Comparing rates of RRD after intravitreal injection with other studies is inherently limited by different injection protocols among physicians and locations. Our study excluded patients treated with anti-VEGF medication for diabetic macular edema or diabetic retinopathy because retinal detachment may develop as a result of tractional causes after intravitreal injection.<sup>27</sup> Because we purposely excluded patients treated for diabetic macular edema or diabetic retinopathy to isolate the effect of intravitreal injection on RRD, our reported rates of detachment may not apply to patients treated with

intravitreal injection for diabetic eye disease. Additionally, although we attempted to evaluate some factors associated with development of RRD after intravitreal injection, it is possible that additional patient characteristics or injection techniques that were not included in our analysis may be risk factors. Although we evaluated visual outcomes by baseline lens status, we did not evaluate the effect of cataract progression or the effect of cataract surgery after vitrectomy, which could be a confounder on visual outcomes. Given the retrospective nature of the study, bias may exist that skews our data. If patients who demonstrated an RRD after intravitreal injection were not captured—because of follow-up with an outside provider or a loss to follow-up—our ascertainment would be too low. Conversely, if patients who demonstrated an RRD after intravitreal injection showed a higher rate of follow-up compared with patients receiving intravitreal injections without an RRD developing, our rate would be too high. Finally, although we evaluated whether the risk of RRD development was associated with the number of injections patients received during the study period, our analysis does not include intravitreal injections given before the study period or outside of our clinics, which likely underestimates the true number of injections some patients received and limits our ability to evaluate this potential risk factor accurately.

We expect the use of anti-VEGF medications for retinal disease to continue to expand, because they have proven highly effective. Although some patients with complications resulting from intravitreal injections do well, many experience substantial visual loss. Although retinal detachment after injection always may remain a risk, additional research to decrease complications further and improve patient outcomes is welcome.

## References

1. Rosenfeld PJ, Brown DM, Heier JS, et al. Ranibizumab for neovascular age-related macular degeneration. *N Engl J Med*. 2006;355(14):1419–1431.
2. Brown DM, Kaiser PK, Michels M, et al. Ranibizumab versus verteporfin for neovascular age-related macular degeneration. *N Engl J Med*. 2006;355(14):1432–1444.
3. Heier JS, Brown DM, Chong V, et al. Intravitreal aflibercept (VEGF trap-eye) in wet age-related macular degeneration. *Ophthalmology*. 2012;119(12):2537–2548.
4. Group CR, Martin DF, Maguire MG, et al. Ranibizumab and bevacizumab for neovascular age-related macular degeneration. *N Engl J Med*. 2011;364(20):1897–1908.
5. Campochiaro PA, Heier JS, Feiner L, et al. Ranibizumab for macular edema following branch retinal vein occlusion: six-month primary end point results of a phase III study. *Ophthalmology*. 2010;117(6):1102–1112.e1.
6. Iturralde D, Spaide RF, Meyerle CB, et al. Intravitreal bevacizumab (Avastin) treatment of macular edema in central retinal vein occlusion: a short-term study. *Retina*. 2006;26(3):279–284.
7. Brown DM, Heier JS, Clark WL, et al. Intravitreal aflibercept injection for macular edema secondary to central retinal vein occlusion: 1-year results from the phase 3

- COPERNICUS study. *Am J Ophthalmol.* 2013;155(3):429–437.e7.
8. McLaughlin MD, Hwang JC. Trends in vitreoretinal procedures for Medicare beneficiaries, 2000 to 2014. *Ophthalmology.* 2017;124(5):667–673.
  9. Storey P, Garg S. Endophthalmitis following intravitreal injection. *Curr Ophthalmol Rep.* 2018;6(2):145–151.
  10. Rayess N, Rahimy E, Storey P, et al. Postinjection endophthalmitis rates and characteristics following intravitreal bevacizumab, ranibizumab, and aflibercept. *Am J Ophthalmol.* 2016;165:88–93.
  11. Storey P, Dollin M, Pitcher J, et al. The role of topical antibiotic prophylaxis to prevent endophthalmitis after intravitreal injection. *Ophthalmology.* 2014;121(1):283–289.
  12. Brown DM, Michels M, Kaiser PK, et al. Ranibizumab versus verteporfin photodynamic therapy for neovascular age-related macular degeneration: two-year results of the ANCHOR study. *Ophthalmology.* 2009;116(1):57–65.e5.
  13. Gragoudas ES, Adamis AP, Cunningham Jr ET, et al. Pegaptanib for neovascular age-related macular degeneration. *N Engl J Med.* 2004;351(27):2805–2816.
  14. Schmidt-Erfurth U, Kaiser PK, Korobelnik JF, et al. Intravitreal aflibercept injection for neovascular age-related macular degeneration: ninety-six-week results of the VIEW studies. *Ophthalmology.* 2014;121(1):193–201.
  15. Kuppermann BD, Thomas EL, de Smet MD, et al. Safety results of two phase III trials of an intravitreal injection of highly purified ovine hyaluronidase (Vitrase) for the management of vitreous hemorrhage. *Am J Ophthalmol.* 2005;140(4):585–597.
  16. Fung AE, Rosenfeld PJ, Reichel E. The International Intravitreal Bevacizumab Safety Survey: using the internet to assess drug safety worldwide. *Br J Ophthalmol.* 2006;90(11):1344–1349.
  17. Jonas JB, Spandau UH, Schlichtenbrede F. Short-term complications of intravitreal injections of triamcinolone and bevacizumab. *Eye (Lond).* 2008;22(4):590–591.
  18. Wu L, Martinez-Castellanos MA, Quiroz-Mercado H, et al. Twelve-month safety of intravitreal injections of bevacizumab (Avastin): results of the Pan-American Collaborative Retina Study Group (PACORES). *Graefes Arch Clin Exp Ophthalmol.* 2008;246(1):81–87.
  19. Meyer CH, Michels S, Rodrigues EB, et al. Incidence of rhegmatogenous retinal detachments after intravitreal anti-vascular endothelial factor injections. *Acta Ophthalmol.* 2011;89(1):70–75.
  20. Hajari JN, Bjerrum SS, Christensen U, et al. A nationwide study on the incidence of rhegmatogenous retinal detachment in Denmark, with emphasis on the risk of the fellow eye. *Retina.* 2014;34(8):1658–1665.
  21. Mityr D, Charteris DG, Fleck BW, et al. The epidemiology of rhegmatogenous retinal detachment: geographical variation and clinical associations. *Br J Ophthalmol.* 2010;94(6):678–684.
  22. Magalhães OJ, De Ávila MP, Maia M, et al. Difference between bevel-up and bevel-down 23-gauge one-step incisions: analysis of anterior chamber optical coherence tomography and IOP. *Retina.* 2010;30(3):521–523.
  23. Kozak I, Dean A, Clark TM, et al. Prefilled syringe needles versus standard removable needles for intravitreal injection. *Retina.* 2006;26(6):679–683.
  24. Meyer CH, Rodrigues EB, Michels S, et al. Incidence of damage to the crystalline lens during intravitreal injections. *J Ocul Pharmacol Ther.* 2010;26(5):491–495.
  25. Wimpissinger B, Binder S. Entry-site-related retinal detachment after pars plana vitrectomy. *Acta Ophthalmol Scand.* 2007;85(7):782–785.
  26. White MH, Lambert HM, Kincaid MC, et al. The ora serrata and the spiral of Tillaux. Anatomic relationship and clinical correlation. *Ophthalmology.* 1989;96(4):508–511.
  27. Arevalo JF, Maia M, Flynn Jr HW, et al. Tractional retinal detachment following intravitreal bevacizumab (Avastin) in patients with severe proliferative diabetic retinopathy. *Br J Ophthalmol.* 2008;92(2):213–216.

## Footnotes and Financial Disclosures

Originally received: December 18, 2018.

Final revision: April 14, 2019.

Accepted: April 23, 2019.

Available online: April 28, 2019.

Manuscript no. 2018-2821.

Wills Eye Hospital, Mid Atlantic Retina, Thomas Jefferson University, Philadelphia, Pennsylvania.

Presented at: Retina Society Annual Meeting, September 2018, San Francisco; and American Academy of Ophthalmology Annual Meeting, October 2018, Chicago, Illinois.

Financial Disclosure(s):

The author(s) have no proprietary or commercial interest in any materials discussed in this article.

**HUMAN SUBJECTS:** Human subjects were included in this study. The human ethics committees at Wills Eye Hospital approved the study. All research adhered to the tenets of the Declaration of Helsinki. No informed consent was obtained as this was a retrospective study of de-identified patients.

No animal subjects were included in this study.

Author Contributions:

Conception and design: Storey, Pancholy, Wibbelsman, Obeid, Gupta

Analysis and interpretation: Storey, Pancholy, Wibbelsman, Obeid, Garg, Gupta

Data collection: Storey, Pancholy, Wibbelsman, Obeid

Obtained funding: Study was performed as part of our regular employment duties at Wills Eye Hospital.

Overall responsibility: Storey, Pancholy, Wibbelsman, Obeid, Su, Borkar, Garg, Gupta

Abbreviations and Acronyms:

**AMD** = age-related macular degeneration; **CI** = confidence interval; **logMAR** = logarithm of the minimum angle of resolution; **PPV** = pars plana vitrectomy; **PVD** = posterior vitreous detachment; **RRD** = rhegmatogenous retinal detachment; **RVO** = retinal vein occlusion; **VEGF** = vascular endothelial growth factor.

Correspondence:

Omesh Gupta, MD, MBA, Retina Service, Wills Eye Hospital, Mid Atlantic Retina, Thomas Jefferson University, 840 Walnut Street, Suite 1020, Philadelphia, PA 19107. E-mail: [ogupta@midatlanticrotina.com](mailto:ogupta@midatlanticrotina.com).